A 58-year-old man comes to the office with upper abdominal pain, fatigue, and anorexia. He says his symptoms began about a month ago and seem to be getting worse. The patient has a history of cirrhosis due to chronic hepatitis C. Physical examination shows cachexia and worsening ascites. Imaging studies reveal a large mass in the right hepatic lobe consistent with unresectable hepatocellular cancer. The patient is scheduled to undergo percutaneous embolization of the artery supplying the tumor. Contrast material administration into which of the following structures is most likely to visually enhance the artery prior to embolization?

- A. Celiac trunk
- B. Gastroduodenal artery
- C. Inferior mesenteric artery
- D. Inferior vena cava
- E. Splenic artery
- F. Superior mesenteric artery

Submit

A 58-year-old man comes to the office with upper abdominal pain, fatigue, and anorexia. He says his symptoms began about a month ago and seem to be getting worse. The patient has a history of cirrhosis due to chronic hepatitis C. Physical examination shows cachexia and worsening ascites. Imaging studies reveal a large mass in the right hepatic lobe consistent with unresectable hepatocellular cancer. The patient is scheduled to undergo percutaneous embolization of the artery supplying the tumor. Contrast material administration into which of the following structures is most likely to visually enhance the artery prior to embolization?

- ✓ A. Celiac trunk (83%)
- B. Gastroduodenal artery (5%)
- C. Inferior mesenteric artery (0%)
- D. Inferior vena cava (3%)
- E. Splenic artery (1%)
- F. Superior mesenteric artery (5%)

Omitted
Correct answer
A

83%
Answered correctly

05 secs
Time Spent

04/21/2020
Last Updated

Explanation

Upper abdominal vasculature

Upper abdominal vasculature

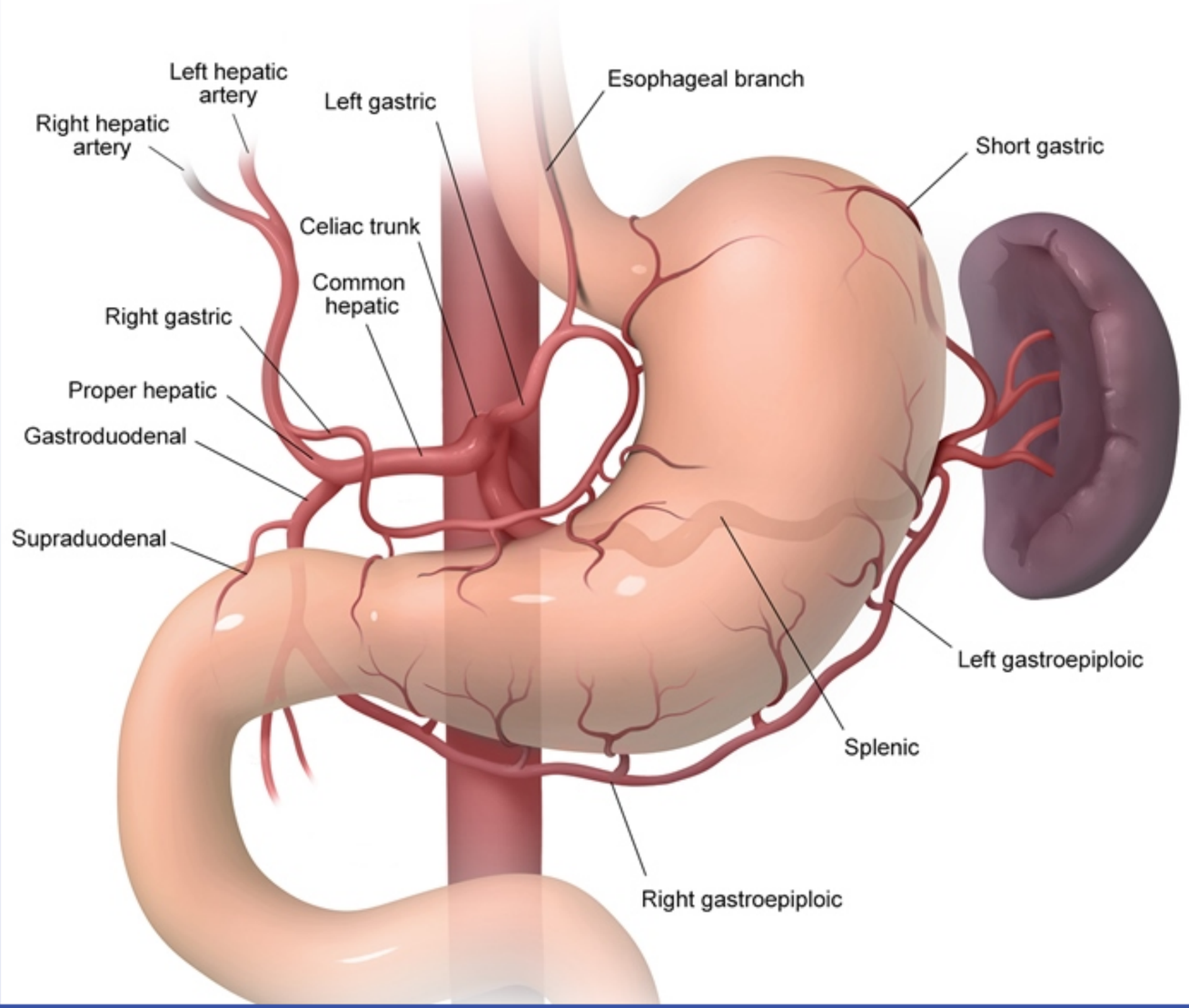

Upper abdominal vasculature

Exhibit Display

Upper abdominal vasculature

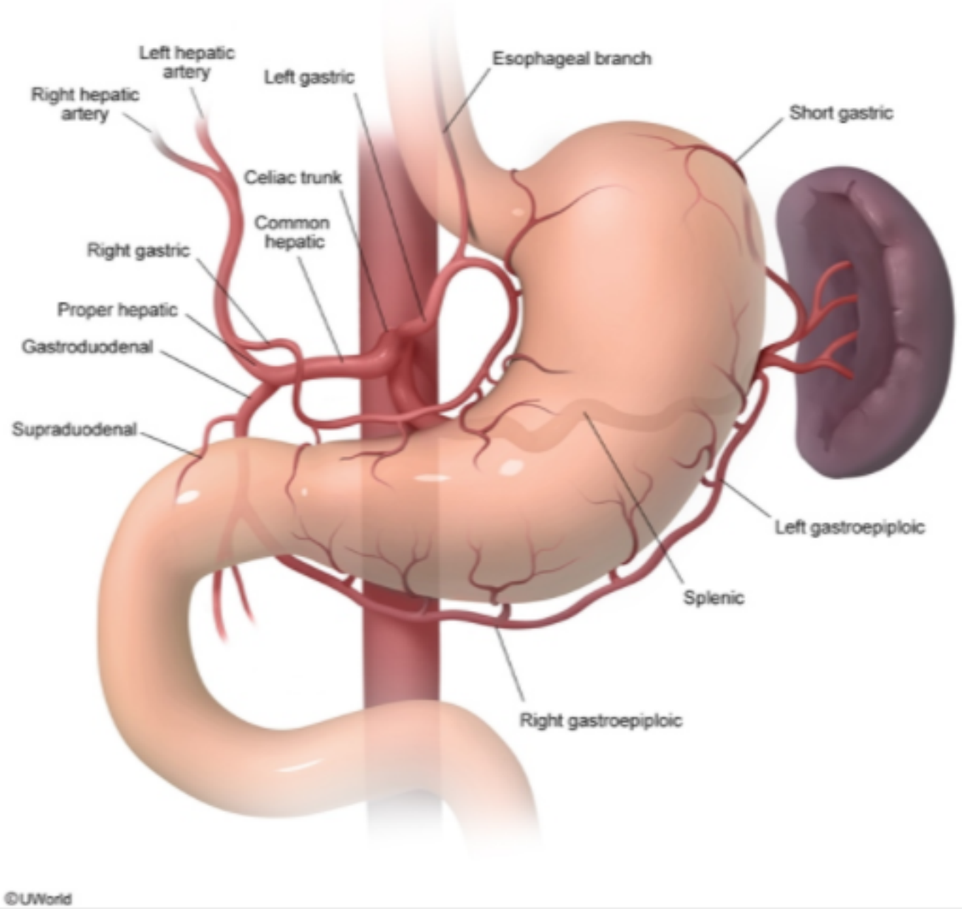

Zoom In | Zoom Out | Reset | Add To New Card | Existing Card

©UWorld

The vascular supply to the upper abdomen mainly comes from the **celiac trunk** (celiac artery), which is the first anterior branch of the abdominal aorta. The celiac trunk branches into the left gastric, **common hepatic**, and splenic arteries. The left gastric artery further divides into the esophageal and stomach branches, which supply blood to the abdominal esophagus and upper stomach. The splenic artery and its branches (dorsal pancreatic, short gastric, left gastro-omental, and greater pancreatic arteries) provide blood to the spleen, the gastric fundus, and part of the pancreas **(Choice E)**.

The common hepatic artery further divides into the gastroduodenal and proper hepatic arteries. The gastroduodenal artery supplies blood to the pylorus, proximal duodenum, and pancreatic head **(Choice B)**.

The **proper hepatic** artery divides into the left and right hepatic arteries, which provide arterial blood supply to the liver and would perfuse this patient's right hepatic lobe mass.

(Choice C) The inferior mesenteric artery branches off the abdominal aorta at the L3 level (inferior to both the celiac trunk and superior mesenteric artery). This artery provides blood supply to the colon from the splenic flexure to the upper rectum (eg, descending and sigmoid colon).

(Choice D) The inferior vena cava (IVC) is formed by the union of both common iliac veins and drains blood from the lower part of the body to the right atrium. Other veins that empty into the IVC include the hepatic, renal, lumbar, and gonadal veins.

(Choice F) The superior mesenteric artery branches off the abdominal aorta inferior to the origin of the celiac trunk. The superior mesenteric artery supplies blood to part of the pancreas and the intestine from the lower part of the duodenum to the first two-thirds of the transverse colon.

Educational objective:
The celiac trunk is the first main branch of the abdominal aorta; it provides oxygenated blood to the spleen, stomach, liver, abdominal esophagus, and parts of the duodenum and pancreas. The proper hepatic artery branches off the common hepatic artery from the celiac trunk and provides arterial blood supply to the liver.

Anatomy	Gastrointestinal & Nutrition	Cardiovascular anatomy
Subject	System	Topic

A 21-year-old man comes to the emergency department due to abdominal pain, nausea, and vomiting. The patient started having vague periumbilical pain in the morning. Over the next several hours, the pain became more severe, sharper, and localized to the right lower abdominal quadrant. Temperature is 38.3 C (100.9 F), blood pressure is 132/84 mm Hg, pulse is 102/min, and respirations are 12/min. Physical examination shows maximal tenderness in the right lower abdomen two-thirds of the distance from the umbilicus to the anterior superior iliac spine. Bowel sounds are decreased. Laboratory studies reveal a leukocyte count of 16,000/mm^3. The change in this patient's pain characteristics is most likely explained by which of the following?

A. Involvement of the obturator internus muscle

B. Inflammation of the psoas major muscle

C. Stimulation of the cecal nerve endings

D. Irritation of the parietal peritoneum

E. Retrocecal orientation of the appendix

Submit

A 21-year-old man comes to the emergency department due to abdominal pain, nausea, and vomiting. The patient started having vague periumbilical pain in the morning. Over the next several hours, the pain became more severe, sharper, and localized to the right lower abdominal quadrant. Temperature is 38.3 C (100.9 F), blood pressure is 132/84 mm Hg, pulse is 102/min, and respirations are 12/min. Physical examination shows maximal tenderness in the right lower abdomen two-thirds of the distance from the umbilicus to the anterior superior iliac spine. Bowel sounds are decreased. Laboratory studies reveal a leukocyte count of 16,000/mm^3. The change in this patient's pain characteristics is most likely explained by which of the following?

- A. Involvement of the obturator internus muscle (1%)
- B. Inflammation of the psoas major muscle (8%)
- C. Stimulation of the cecal nerve endings (7%)
- ✓ D. Irritation of the parietal peritoneum (69%)
- E. Retrocecal orientation of the appendix (13%)

Omitted
Correct answer
D

69%
Answered correctly

01 sec
Time Spent

02/03/2020
Last Updated

Explanation



1
2
3
4
5
6
7
8
9
10
11
12
13
14
15
16
17
18
19
20
21
22
23
24
25
26
27
28
29
30
31

McBurney point

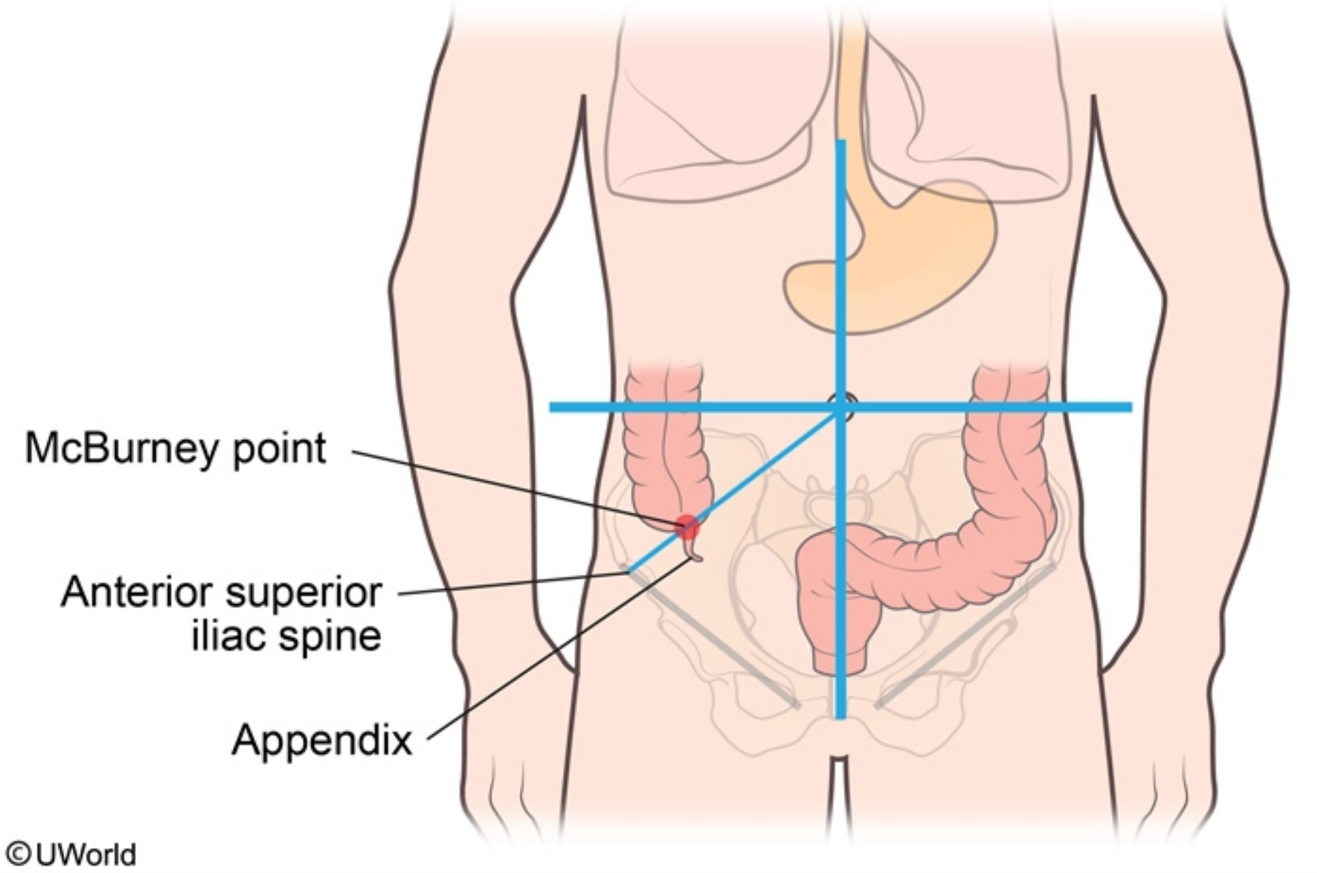

This patient's presentation is concerning for **appendicitis**, which can cause both visceral (vague, nonlocalized) and somatic (sharp, well-localized) abdominal pain. **Visceral abdominal pain** is most often due to luminal distension and stretching of smooth muscle and is carried by general visceral afferent fibers of the autonomic nervous system. The pain typically occurs in the **midline** region and is **poorly localized** and of a dull, constant, or cramping quality. Patients with visceral pain also commonly develop nausea, vomiting, or sweating due to activation of the autonomic nervous system. In contrast, somatic pain is usually due to irritation of the parietal peritoneum and is well localized, more severe, and worsened with deep inspiration or pushing on the abdominal wall.

©UWorld

This patient's presentation is concerning for **appendicitis**, which can cause both visceral (vague, nonlocalized) and somatic (sharp, well-localized) abdominal pain. **Visceral abdominal pain** is most often due to luminal distension and stretching of smooth muscle and is carried by general visceral afferent fibers of the autonomic nervous system. The pain typically occurs in the **midline** region and is **poorly localized** and of a dull, constant, or cramping quality. Patients with visceral pain also commonly develop nausea, vomiting, or sweating due to activation of the autonomic nervous system. In contrast, somatic pain is usually due to irritation of the parietal peritoneum and is well localized, more severe, and worsened with deep inspiration or pushing on the abdominal wall.

The afferent pain fibers for the appendix, proximal colon (including the cecum), and overlying visceral peritoneum cross through the superior mesenteric plexus and enter the spinal cord at the T10 level to produce vague, referred pain at the umbilicus **(Choice C)**. As the appendix becomes more inflamed, it irritates the **parietal peritoneum** and abdominal wall and causes a **more severe somatic pain** that **shifts** from the umbilical region to the **McBurney point** (two-thirds of the distance from the umbilicus to the anterior superior iliac spine). With peritoneal irritation, the abdominal wall becomes very sensitive to gentle palpation or sudden release of pressure (ie, rebound tenderness).

The appendix is usually located 2 cm beneath the ileocecal valve in the right lower quadrant. Depending on its orientation, there can be additional clinical findings. A pelvic appendix lies against the right obturator internus muscle, causing right lower quadrant pain with internal rotation of the right hip **(Choice A)**. Patients with a retrocecal appendix may not have significant right lower quadrant tenderness because the inflamed appendix does not contact the anterior parietal peritoneum, and the cecum (distended with gas) acts as a cushion that blocks the examiner's hand. However, the inflamed appendix will lie against the right psoas muscle, causing pain with hip extension **(Choices B and E)**.

Educational objective:
Appendicitis causes dull visceral pain at the umbilicus due to afferent pain fibers entering at the T10 level in the spinal cord. Progressive inflammation in the appendix irritates the parietal peritoneum and abdominal wall to cause more severe somatic pain shifting from the umbilicus to McBurney's point (two-thirds of the distance from the umbilicus to the anterior superior iliac spine).

Anatomy	Gastrointestinal & Nutrition	Appendicitis
Subject	System	Topic

Copyright © UWorld. All rights reserved.

A 65-year-old man is evaluated in the clinic due to several months of abdominal pain and vomiting. The pain starts 2 to 3 hours after meals, is characterized as crampy, and is often associated with bilious vomiting. Lately, the patient has been tolerating only liquids and has consequently lost 12 lbs in the past 4 months. On physical examination, he has mild epigastric tenderness on deep palpation. Contrast-enhanced CT scan of the abdomen shows an irregular mass in the third portion of the duodenum that is infiltrating beyond the gut wall. If this mass continues to enlarge, which of the following structures is most likely to be compromised in this patient?

A. Common bile duct

B. Gastroduodenal artery

C. Portal vein

D. Superior mesenteric artery

E. Ureter

Submit

A 65-year-old man is evaluated in the clinic due to several months of abdominal pain and vomiting. The pain starts 2 to 3 hours after meals, is characterized as crampy, and is often associated with bilious vomiting. Lately, the patient has been tolerating only liquids and has consequently lost 12 lbs in the past 4 months. On physical examination, he has mild epigastric tenderness on deep palpation. Contrast-enhanced CT scan of the abdomen shows an irregular mass in the third portion of the duodenum that is infiltrating beyond the gut wall. If this mass continues to enlarge, which of the following structures is most likely to be compromised in this patient?

- A. Common bile duct (12%)
- B. Gastroduodenal artery (18%)
- C. Portal vein (6%)
- ✓ D. Superior mesenteric artery (58%)
- E. Ureter (3%)

Omitted
Correct answer
D

58%
Answered correctly

01 sec
Time Spent

05/31/2020
Last Updated

Explanation

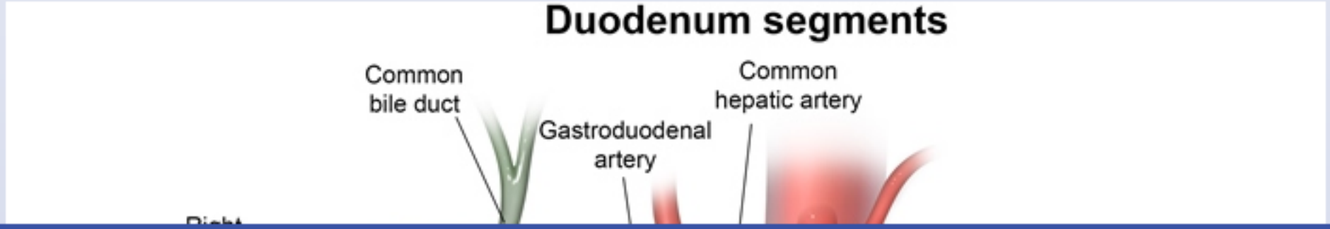

1
2
3
4
5
6
7
8
9
10
11
12
13
14
15
16
17
18
19
20
21
22
23
24
25
26
27
28
29
30
31

Duodenum segments

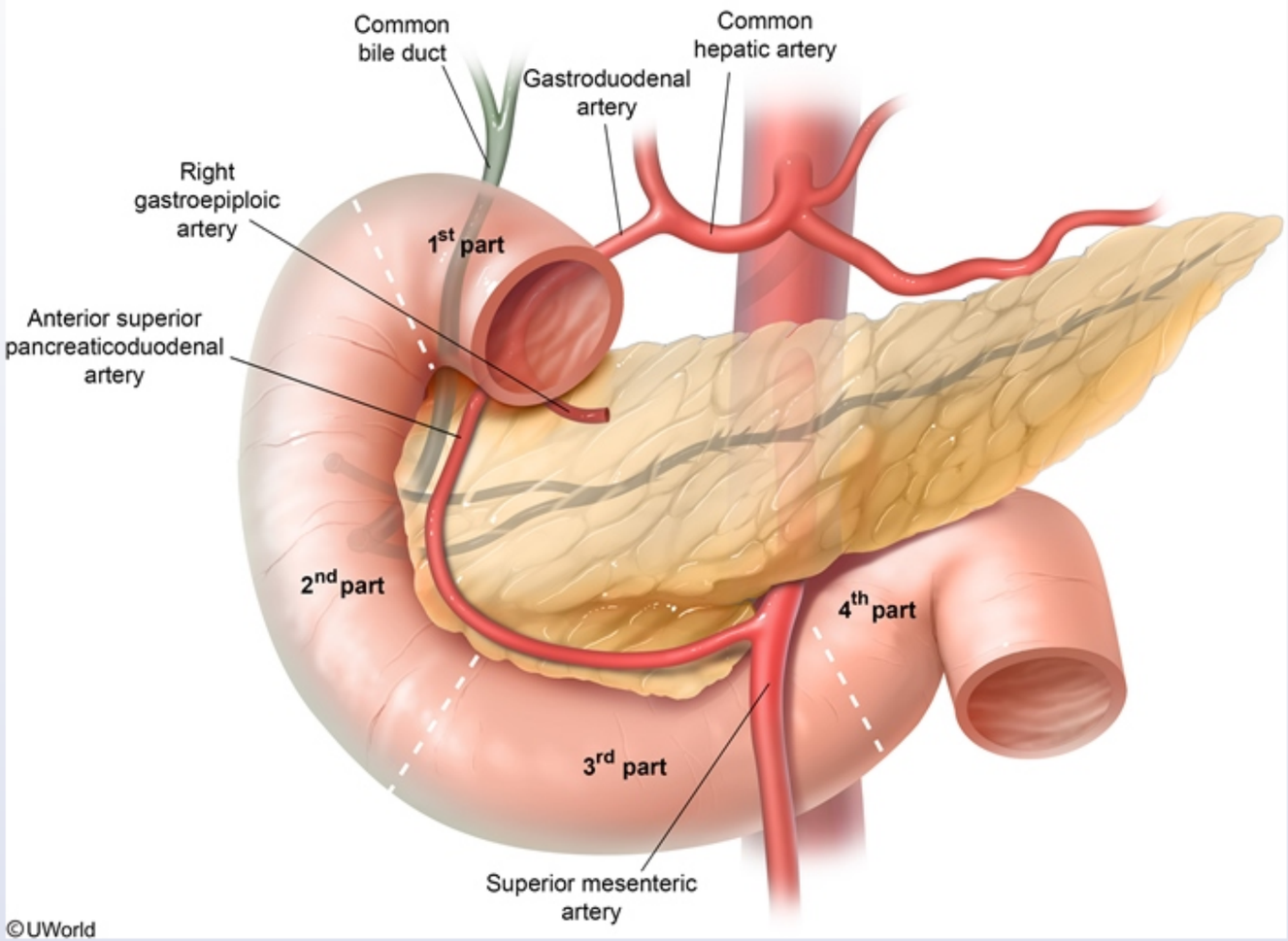

The first part of the duodenum emerges from the pylorus of the stomach and is horizontally oriented over the first lumbar vertebra. It is the only part of the duodenum that is not retroperitoneal. The second part of the duodenum courses inferiorly from the level of L1 to L3. This part of the duodenum is in close relation to the head of the pancreas and contains the ampulla of Vater, the site where pancreatic and common bile duct secretions are released.

artery

©UWorld

The first part of the duodenum emerges from the pylorus of the stomach and is horizontally oriented over the first lumbar vertebra. It is the only part of the duodenum that is not retroperitoneal. The second part of the duodenum courses inferiorly from the level of L1 to L3. This part of the duodenum is in close relation to the head of the pancreas and contains the ampulla of Vater, the site where pancreatic and common bile duct secretions are released.

The **third part** of the **duodenum** courses horizontally over L3, the abdominal aorta, and the inferior vena cava. It is in close association with the uncinate process of the pancreas and the **superior mesenteric artery** and vein. Small bowel malignancies are rare; if they occur in the third part of the duodenum, anterior tumor invasion could compromise the superior mesenteric vessels. The fourth part of the duodenum courses superiorly and to the left of the L2 and L3 vertebrae and becomes the jejunum past the ligament of Treitz.

(Choice A) The common bile duct is formed when the common hepatic duct and cystic duct join in the porta hepatis region of the hepatoduodenal ligament. The common bile duct courses inferiorly, posterior to the first part of the duodenum and within the head of the pancreas, to drain into the second part of the duodenum.

(Choice B) The gastroduodenal artery arises from the common hepatic artery and courses inferiorly, posterior to the first part of the duodenum, where it then splits into the anterior superior pancreaticoduodenal artery and the right gastroepiploic artery. Peptic ulcers involving the posterior duodenal bulb can erode into the gastroduodenal artery and cause bleeding.

(Choice C) The portal vein is formed by the union of the superior mesenteric and splenic veins in the retroperitoneum. It is located posterior to the pancreas at the level of the first lumbar vertebra and makes no contact with the duodenum.

(Choice E) The left ureter has no relation to the duodenum. The right ureter courses retroperitoneally, posterior to the second part of the duodenum, for a short length.

Educational objective:
The third part of the duodenum courses horizontally across the abdominal aorta and inferior vena cava at the level of the third lumbar vertebra. The superior mesenteric vessels lie anterior to the duodenum at this location.

References

- Upper gastrointestinal bleeding due to superior mesenteric artery to duodenum fistula: rare complication of metastatic lung carcinoma.

The **third part** of the **duodenum** courses horizontally over L3, the abdominal aorta, and the inferior vena cava. It is in close association with the uncinate process of the pancreas and the **superior mesenteric artery** and vein. Small bowel malignancies are rare; if they occur in the third part of the duodenum, anterior tumor invasion could compromise the superior mesenteric vessels. The fourth part of the duodenum courses superiorly and to the left of the L2 and L3 vertebrae and becomes the jejunum past the ligament of Treitz.

(Choice A) The common bile duct is formed when the common hepatic duct and cystic duct join in the porta hepatis region of the hepatoduodenal ligament. The common bile duct courses inferiorly, posterior to the first part of the duodenum and within the head of the pancreas, to drain into the second part of the duodenum.

(Choice B) The gastroduodenal artery arises from the common hepatic artery and courses inferiorly, posterior to the first part of the duodenum, where it then splits into the anterior superior pancreaticoduodenal artery and the right gastroepiploic artery. Peptic ulcers involving the posterior duodenal bulb can erode into the gastroduodenal artery and cause bleeding.

(Choice C) The portal vein is formed by the union of the superior mesenteric and splenic veins in the retroperitoneum. It is located posterior to the pancreas at the level of the first lumbar vertebra and makes no contact with the duodenum.

(Choice E) The left ureter has no relation to the duodenum. The right ureter courses retroperitoneally, posterior to the second part of the duodenum, for a short length.

Educational objective:
The third part of the duodenum courses horizontally across the abdominal aorta and inferior vena cava at the level of the third lumbar vertebra. The superior mesenteric vessels lie anterior to the duodenum at this location.

References

- Upper gastrointestinal bleeding due to superior mesenteric artery to duodenum fistula: rare complication of metastatic lung carcinoma.

Anatomy	Gastrointestinal & Nutrition	Gastrointestinal blood supply
Subject	System	Topic

Copyright © UWorld. All rights reserved.

A 58-year-old man is being evaluated for constipation and weight loss over the last several months. During the past 2 weeks, he has had several episodes of rectal bleeding. The patient has never had a screening colonoscopy. Examination shows a soft and nontender abdomen without masses or organomegaly. Digital rectal examination reveals a firm palpable mass in the rectal vault. Flexible rectosigmoidoscopy shows a large ulcerative mass in the middle third of the rectum extending to the rectosigmoid junction. He undergoes surgical resection of the rectosigmoid colon. Frozen section analysis reveals clear margins of the colon specimen with metastases in the pararectal lymph nodes. Which of the following lymph node groups should be sampled in this patient for further assessment of metastatic disease?

A. Celiac
B. Internal iliac
C. Left colic
D. Right colic
E. Superficial inguinal
F. Superior mesenteric
G. Supraclavicular

Submit

A 58-year-old man is being evaluated for constipation and weight loss over the last several months. During the past 2 weeks, he has had several episodes of rectal bleeding. The patient has never had a screening colonoscopy. Examination shows a soft and nontender abdomen without masses or organomegaly. Digital rectal examination reveals a firm palpable mass in the rectal vault. Flexible rectosigmoidoscopy shows a large ulcerative mass in the middle third of the rectum extending to the rectosigmoid junction. He undergoes surgical resection of the rectosigmoid colon. Frozen section analysis reveals clear margins of the colon specimen with metastases in the pararectal lymph nodes. Which of the following lymph node groups should be sampled in this patient for further assessment of metastatic disease?

- A. Celiac (1%)
- ✓ B. Internal iliac (53%)
- C. Left colic (18%)
- D. Right colic (1%)
- E. Superficial inguinal (13%)
- F. Superior mesenteric (7%)
- G. Supraclavicular (4%)

Omitted
Correct answer
B

53%
Answered correctly

02 secs
Time Spent

06/06/2020
Last Updated

Explanation

Lymph nodes & vessels of large intestine

1
2
3
4
5
6
7
8
9
10
11
12
13
14
15
16
17
18
19
20
21
22
23
24
25
26
27
28
29
30
31

Lymph nodes & vessels of large intestine

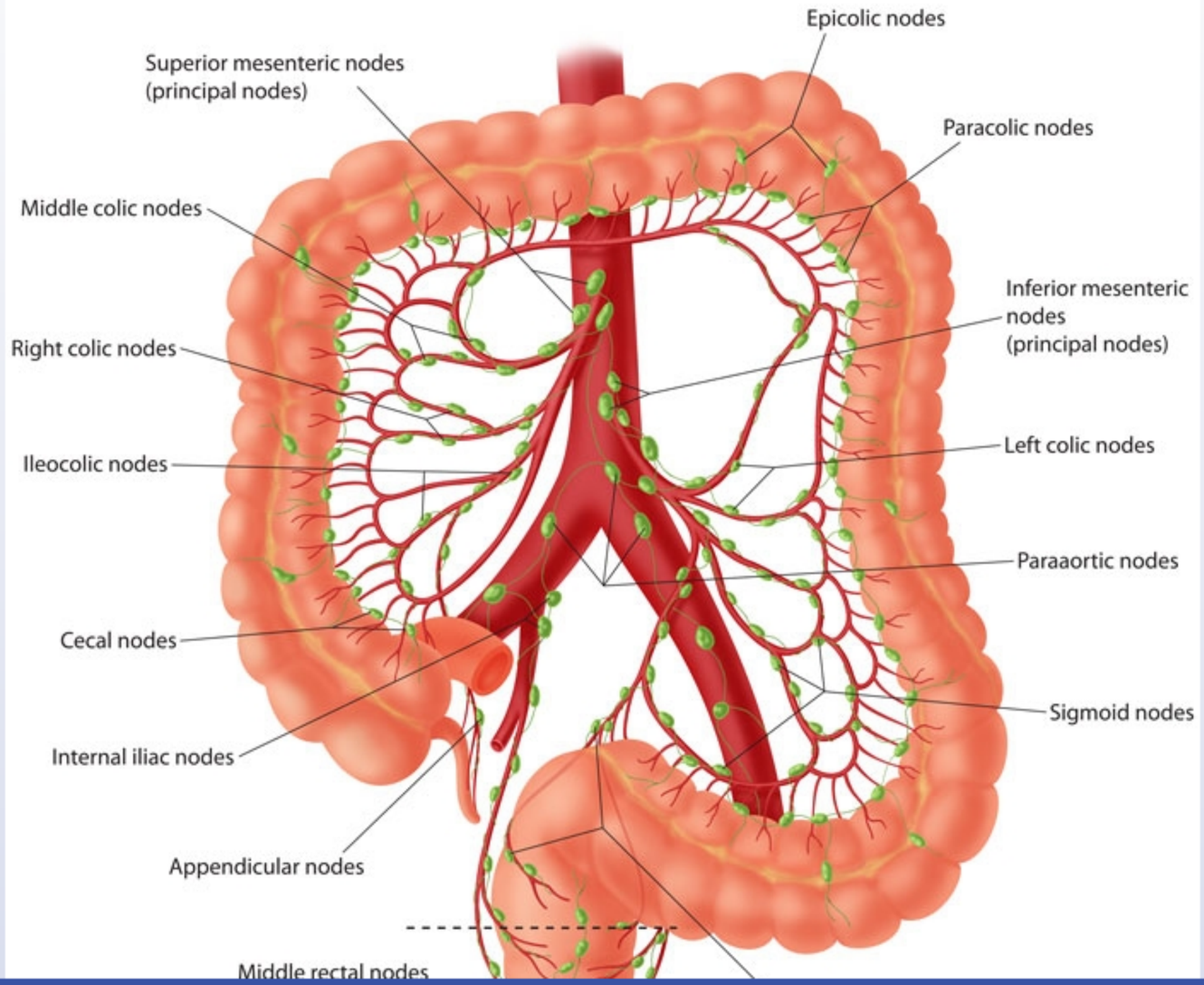

1
2
3
4
5
6
7
8
9
10
11
12
13
14
15
16
17
18
19
20
21
22
23
24
25
26
27
28
29
30
31

Exhibit Display

Lymph nodes & vessels of large intestine

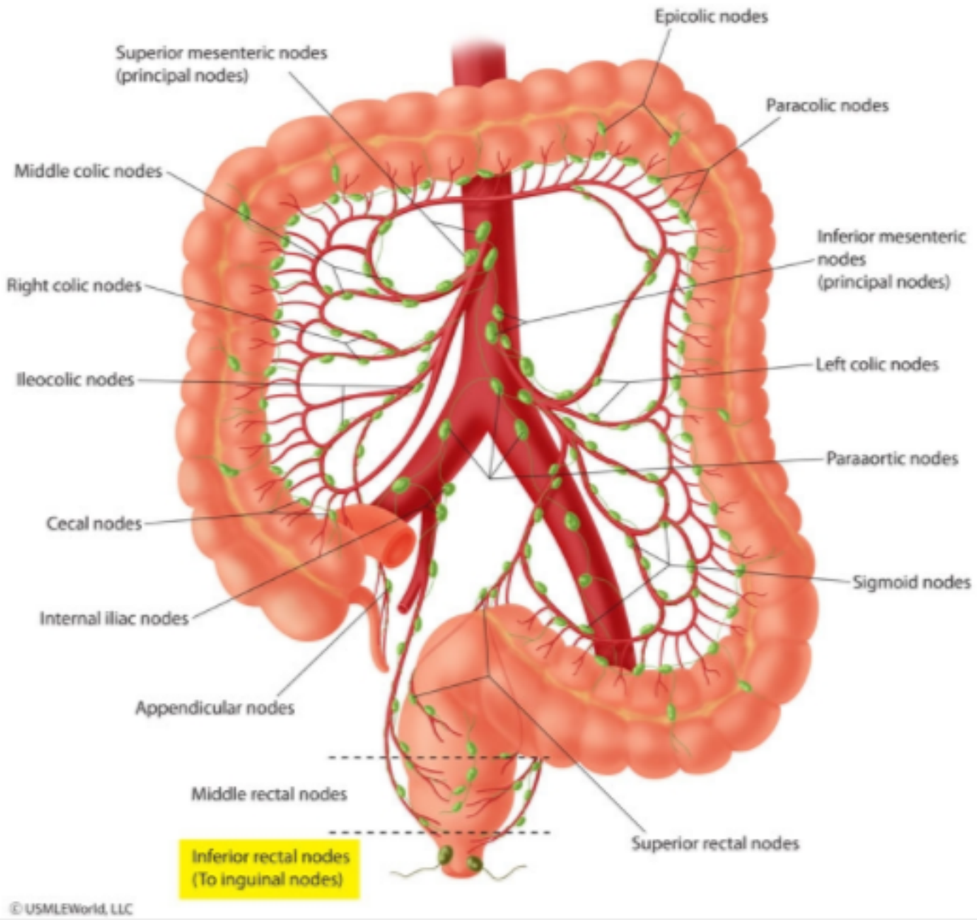

Zoom In | Zoom Out | Reset | Add To New Card | Existing Card

© USMLEWorld, LLC

Lymphatic drainage of the colon generally follows the arterial supply. Lymph nodes are located on the bowel wall (epicolic nodes), inner bowel margins along the arterial arcades (paracolic nodes), around the corresponding mesenteric vessels (intermediate nodes), and at the origin of the superior and inferior mesenteric arteries (principal nodes). The sentinel lymph nodes (first 1-4 lymph nodes draining a specific colonic segment) are usually the first site for colon cancer metastasis.

Lymphatic channels **proximal** to the anal **dentate line** drain into the **inferior mesenteric** and **internal iliac lymph nodes**. The upper rectum and superior part of the middle rectum follow the superior rectal nodes along the superior rectal artery into the inferior mesenteric lymph nodes. The middle to lower third of the rectum can drain upward into the inferior mesenteric nodes or follow the middle rectal nodes along the middle rectal artery to the internal iliac lymph nodes. Areas **distal** to the anal dentate line drain primarily into the **inguinal nodes**, although some lymph can also reach the inferior mesenteric and internal iliac nodes.

(Choice A) The celiac lymph nodes are located around the celiac trunk and drain lymph from the gastric, hepatic, and splenic nodes. These in turn drain their respective organ systems (not the colon).

(Choice C) The left colic lymph nodes and their branches are located along the left colic artery and drain the left colonic flexure and upper descending colon.

(Choice D) The right colic lymph nodes are found along the right colic artery and primarily drain the upper ascending colon.

(Choice E) The superficial inguinal lymph nodes lie below the inguinal ligament and are bordered by the sartorius and adductor longus muscles. They drain parts of the genitalia (eg, penis, scrotum, perineum, and vulva), buttocks, anus below the dentate line, and abdominal wall below the umbilicus.

(Choice F) The superior mesenteric lymph nodes (mesenteric, ileocolic, and mesocolic) mainly drain the ileum, jejunum, vermiform process, and parts of the ascending and transverse colon.

(Choice G) Lymph node metastasis typically occurs sequentially through the epicolic/paracolic, intermediate, and paraaortic lymph nodes. Later in the disease course, the cancer can spread via the thoracic duct to the supraclavicular lymph node (Virchow node).

Educational objective:
Lymphatic drainage of the rectum proximal to the anal dentate line occurs via the inferior mesenteric and internal iliac lymph nodes. Areas distal to the dentate line drain primarily into the inguinal nodes.

superior part of the middle rectum follow the superior rectal nodes along the superior rectal artery into the inferior mesenteric lymph nodes. The middle to lower third of the rectum can drain upward into the inferior mesenteric nodes or follow the middle rectal nodes along the middle rectal artery to the internal iliac lymph nodes. Areas **distal** to the anal dentate line drain primarily into the **inguinal nodes**, although some lymph can also reach the inferior mesenteric and internal iliac nodes.

(Choice A) The celiac lymph nodes are located around the celiac trunk and drain lymph from the gastric, hepatic, and splenic nodes. These in turn drain their respective organ systems (not the colon).

(Choice C) The left colic lymph nodes and their branches are located along the left colic artery and drain the left colonic flexure and upper descending colon.

(Choice D) The right colic lymph nodes are found along the right colic artery and primarily drain the upper ascending colon.

(Choice E) The superficial inguinal lymph nodes lie below the inguinal ligament and are bordered by the sartorius and adductor longus muscles. They drain parts of the genitalia (eg, penis, scrotum, perineum, and vulva), buttocks, anus below the dentate line, and abdominal wall below the umbilicus.

(Choice F) The superior mesenteric lymph nodes (mesenteric, ileocolic, and mesocolic) mainly drain the ileum, jejunum, vermiform process, and parts of the ascending and transverse colon.

(Choice G) Lymph node metastasis typically occurs sequentially through the epicolic/paracolic, intermediate, and paraaortic lymph nodes. Later in the disease course, the cancer can spread via the thoracic duct to the supraclavicular lymph node (Virchow node).

Educational objective:
Lymphatic drainage of the rectum proximal to the anal dentate line occurs via the inferior mesenteric and internal iliac lymph nodes. Areas distal to the dentate line drain primarily into the inguinal nodes.

Anatomy	Gastrointestinal & Nutrition	Lymphatic drainage
Subject	System	Topic

Copyright © UWorld. All rights reserved.

A 56-year-old man comes to the physician complaining of early satiety, nausea, and vague epigastric pain for the past 4 months. He has a 36-pack-year smoking history and admits to drinking alcohol daily for the past 15 years. On physical examination, the patient appears thin and cachectic. Palpation of his abdomen reveals splenomegaly. Abdominal CT scan shows a large irregular mass extending posteriorly from the greater curvature of the stomach, impinging on the splenic artery and vein as they pass below. Tissues supplied by which of the following arteries would most likely be affected by compression of the splenic artery?

A. Gastroduodenal

B. Left gastroepiploic

C. Right gastric

D. Right gastroepiploic

E. Short gastric

Submit

A 56-year-old man comes to the physician complaining of early satiety, nausea, and vague epigastric pain for the past 4 months. He has a 36-pack-year smoking history and admits to drinking alcohol daily for the past 15 years. On physical examination, the patient appears thin and cachectic. Palpation of his abdomen reveals splenomegaly. Abdominal CT scan shows a large irregular mass extending posteriorly from the greater curvature of the stomach, impinging on the splenic artery and vein as they pass below. Tissues supplied by which of the following arteries would most likely be affected by compression of the splenic artery?

- A. Gastroduodenal (4%)
- B. Left gastroepiploic (31%)
- C. Right gastric (4%)
- D. Right gastroepiploic (5%)
- ✓ E. Short gastric (54%)

Omitted
Correct answer
E

54%
Answered correctly

02 secs
Time Spent

06/14/2020
Last Updated

Explanation

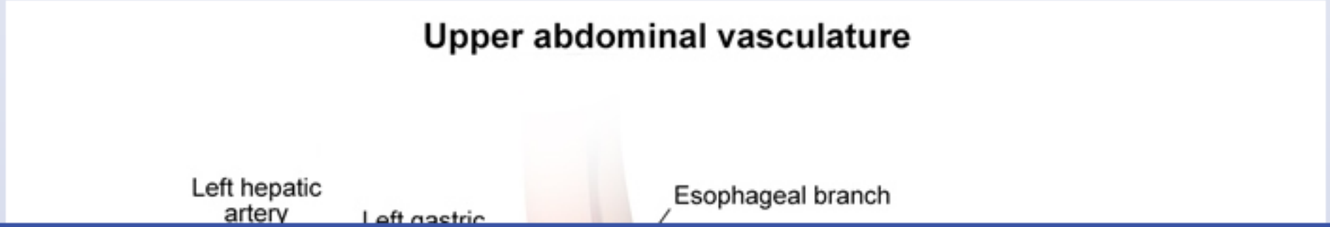

1
2
3
4
5
6
7
8
9
10
11
12
13
14
15
16
17
18
19
20
21
22
23
24
25
26
27
28
29
30
31

Upper abdominal vasculature

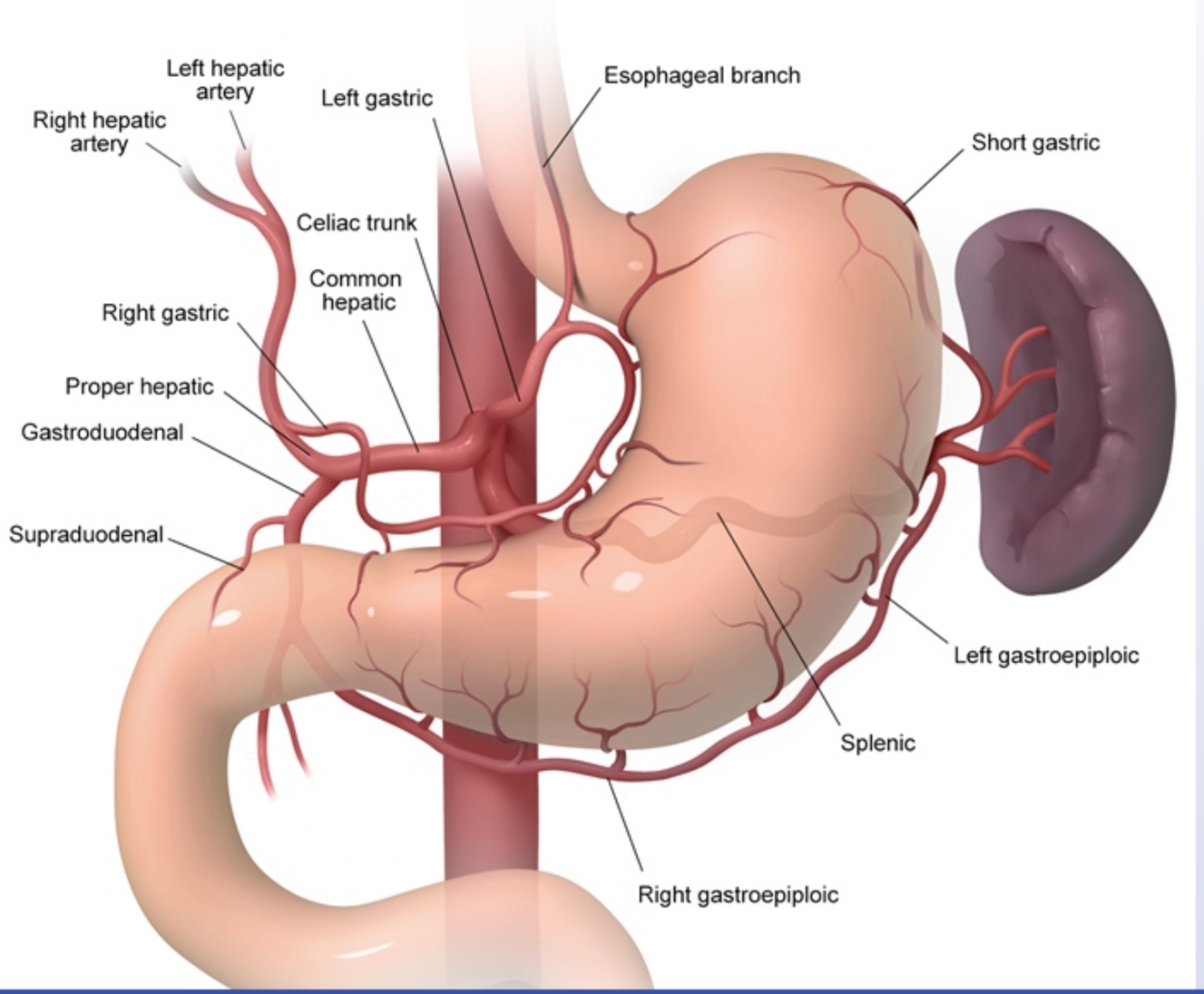

The splenic artery originates from the celiac artery and courses superior to the pancreas. Along its route, it gives off several branches to the stomach and pancreas before reaching the spleen. The short gastric arteries and the left gastroepiploic artery arise from the splenic artery immediately after it passes the greater curvature of the stomach. The short gastric arteries have very poor anastomoses, and the tissue supplied by them is vulnerable to ischemic injury following splenic artery blockage. In contrast, tissues supplied by the left gastroepiploic artery can be alternatively supplemented by its strong anastomotic connection with the right gastroepiploic artery **(Choice B)**.

(Choice A) The gastroduodenal artery supplies blood to the pylorus and the proximal part of the duodenum. It arises from the common hepatic artery.

(Choice C) The right gastric artery supplies blood to the distal lesser curvature of the stomach. It arises from the proper hepatic artery.

(Choice D) The right gastroepiploic artery arises from the gastroduodenal artery and perfuses the distal greater curvature of the stomach. It forms an anastomosis with the left gastroepiploic artery.

Educational objective:
The splenic artery originates from the **celiac artery** and gives off several branches to the stomach and pancreas (pancreatic, short gastric, and left gastroepiploic arteries) before finally reaching the spleen. Due to poor anastomoses, the gastric tissue supplied by the short gastric arteries is vulnerable to ischemic injury following splenic artery blockage.

Anatomy	Gastrointestinal & Nutrition	Gastrointestinal blood supply
Subject	System	Topic

Copyright © UWorld. All rights reserved.

1
2
3
4
5
6
7
8
9
10
11
12
13
14
15
16
17
18
19
20
21
22
23
24
25
26
27
28
29
30
31

A 53-year-old man who has not seen a physician in years presents to your office complaining of abdominal distention. He states "Last month my stomach started to swell up and it hasn't gotten any better". He has no other medical problems. The patient admits to drinking 10-12 beers a day for the last 20 years. His temperature is 36.7 C (98 F), blood pressure is 116/72 mm Hg, pulse is 78/min and respirations are 20/min. On examination his abdomen is distended with engorged paraumbilical veins. There is also palmar erythema and multiple spider angiomas are present. You decided to place him on a low-salt diet and start therapy with furosemide and spironolactone, with subsequent improvement of his abdominal distention. Before beginning this patient's treatment, which of the following structures labeled on the image below is expected to have an increased pressure?

A A

1
2
3
4
5
6
7
8
9
10
11
12
13
14
15
16
17
18
19
20
21
22
23
24
25
26
27
28
29
30
31

A. A

B. B

C. C

D. D

Submit

1
2
3
4
5
6
7
8
9
10
11
12
13
14
15
16
17
18
19
20
21
22
23
24
25
26
27
28
29
30
31

A. A (3%)

B. B (18%)

✓ C. C (71%)

D. D (5%)

Omitted
Correct answer

71%
Answered correctly

03 secs
Time Spent

01/21/2020
Last Updated

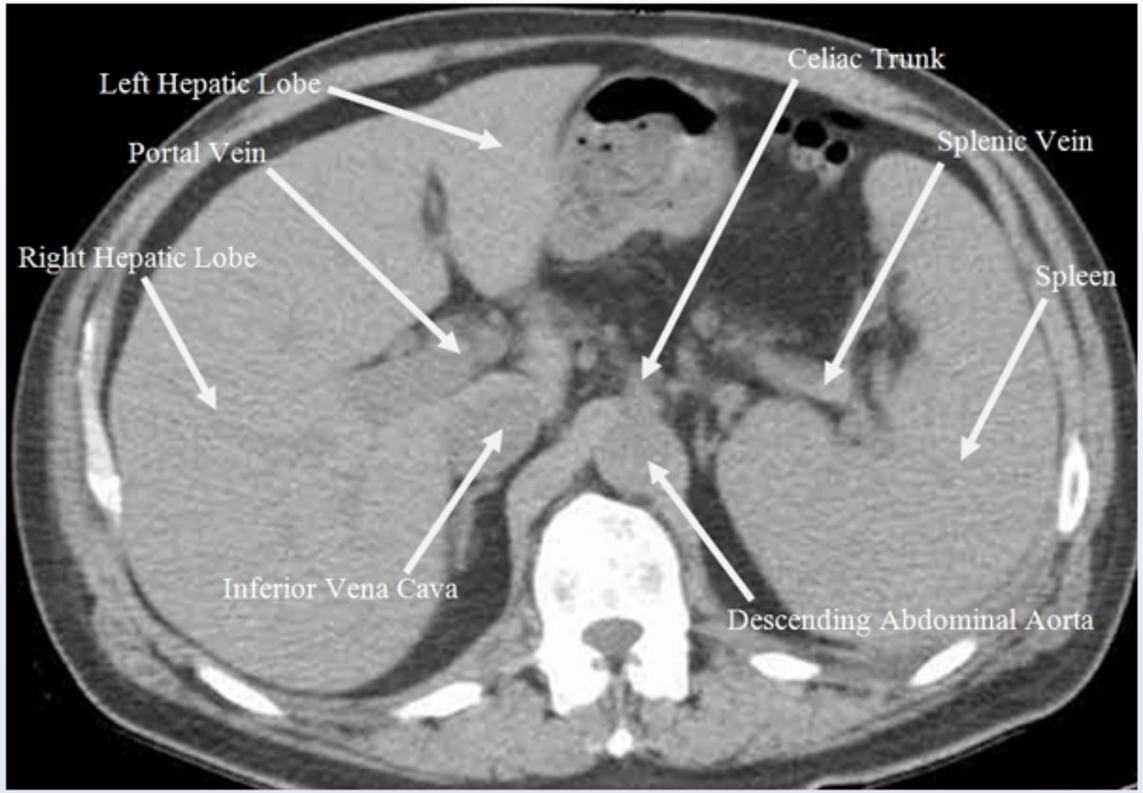

The patient described in the question stem is likely suffering from alcoholic cirrhosis. Alcoholic cirrhosis is a form of micronodular cirrhosis associated with hepatocyte death followed by fine fibrosis of the liver. As cirrhosis worsens and the number of functioning hepatocytes decreases, the functional ability of the liver diminishes. In advanced disease, portal blood has an increasingly difficult time passing through the liver because the vasculature becomes compromised by the progressive fibrosis, causing portal hypertension. Of the structures identified on the image above, only the portal and splenic veins are part of the portal venous system. In this patient, high pressure would be expected throughout the portal system, including the superior mesenteric, portal, and splenic veins. The effects of prolonged portal hypertension include varices at the four sites of portocaval anastomoses (esophagus, rectum, umbilicus, and retroperitoneal), as well as ascites.

The pathogenesis of ascites in patients with cirrhosis is complex. In addition to mechanical compromise of portal vein flow by fibrotic tissue,

The patient described in the question stem is likely suffering from alcoholic cirrhosis. Alcoholic cirrhosis is a form of micronodular cirrhosis associated with hepatocyte death followed by fine fibrosis of the liver. As cirrhosis worsens and the number of functioning hepatocytes decreases, the functional ability of the liver diminishes. In advanced disease, portal blood has an increasingly difficult time passing through the liver because the vasculature becomes compromised by the progressive fibrosis, causing portal hypertension. Of the structures identified on the image above, only the portal and splenic veins are part of the portal venous system. In this patient, high pressure would be expected throughout the portal system, including the superior mesenteric, portal, and splenic veins. The effects of prolonged portal hypertension include varices at the four sites of portocaval anastomoses (esophagus, rectum, umbilicus, and retroperitoneal), as well as ascites.

The pathogenesis of ascites in patients with cirrhosis is complex. In addition to mechanical compromise of portal vein flow by fibrotic tissue, vasoactive agents also play a role by causing dilatation of the splanchnic arterial vasculature and further intrahepatic vasoconstriction. These processes result in increased portal vein hydrostatic pressure leading to ascitic fluid formation, as well as decreased systemic perfusion pressure. The kidney senses the decreased perfusion pressure (accentuated by renal vasoconstriction in hepatorenal syndrome) and responds with avid retention of sodium and water, thus promoting further increase in ascitic fluid formation. Treatment of ascites secondary to cirrhosis involves restriction of sodium intake combined with diuretics. The most commonly prescribed initial therapy is a combination of furosemide and spironolactone.

(Choice A) The descending abdominal aorta will have elevated pressures in patients with systemic hypertension.

(Choice B) The inferior vena cava experiences increased pressure in cases of heart failure. This patient does not present with the typical symptoms associated with heart failure, such as lower extremity edema and shortness of breath.

(Choice D) The celiac trunk emerges from the aorta at this level (T12 / L1).

Educational Objective:
The portal vein can be identified on cross-sectional scans lying medial to (or just within) the right lobe of the liver and anterior to the inferior vena cava. The pressure in the portal system is elevated in liver cirrhosis.

Anatomy	Gastrointestinal & Nutrition	Portal hypertension
Subject	System	Topic

Copyright © UWorld. All rights reserved.

1
2
3
4
5
6
7
8
9
10
11
12
13
14
15
16
17
18
19
20
21
22
23
24
25
26
27
28
29
30
31

A 54-year-old man comes to the office due to several months of heartburn, acid regurgitation, and dysphagia. He has taken antacids and over-the-counter medications without relief. Medical history includes hypertension and hyperlipidemia. The patient does not use tobacco, alcohol, or illicit drugs. Vital signs are within normal limits. BMI is 32 kg/m^2. Physical examination is unremarkable. Upright chest x-ray shows an opacity with an air-fluid level behind the heart. A subsequent barium swallow reveals the proximal stomach herniating through the esophageal hiatus. Which of the following pathophysiological changes most likely contributed to this patient's current condition?

A. Cephalad migration of the squamocolumnar junction with a fixed gastroesophageal junction

B. Circumferential laxity of the phrenoesophageal membrane

C. Diaphragmatic muscle paralysis due to C3-5 motor nerve injury

D. Failure of the posterolateral diaphragmatic foramina to fuse

E. Herniation of abdominal contents through the omental foramen

Submit

A 54-year-old man comes to the office due to several months of heartburn, acid regurgitation, and dysphagia. He has taken antacids and over-the-counter medications without relief. Medical history includes hypertension and hyperlipidemia. The patient does not use tobacco, alcohol, or illicit drugs. Vital signs are within normal limits. BMI is 32 kg/m^2. Physical examination is unremarkable. Upright chest x-ray shows an opacity with an air-fluid level behind the heart. A subsequent barium swallow reveals the proximal stomach herniating through the esophageal hiatus. Which of the following pathophysiological changes most likely contributed to this patient's current condition?

- A. Cephalad migration of the squamocolumnar junction with a fixed gastroesophageal junction (20%)
- ✓ B. Circumferential laxity of the phrenoesophageal membrane (59%)
- C. Diaphragmatic muscle paralysis due to C3-5 motor nerve injury (1%)
- D. Failure of the posterolateral diaphragmatic foramina to fuse (9%)
- E. Herniation of abdominal contents through the omental foramen (8%)

Omitted
Correct answer
B

59%
Answered correctly

02 secs
Time Spent

04/07/2020
Last Updated

Explanation

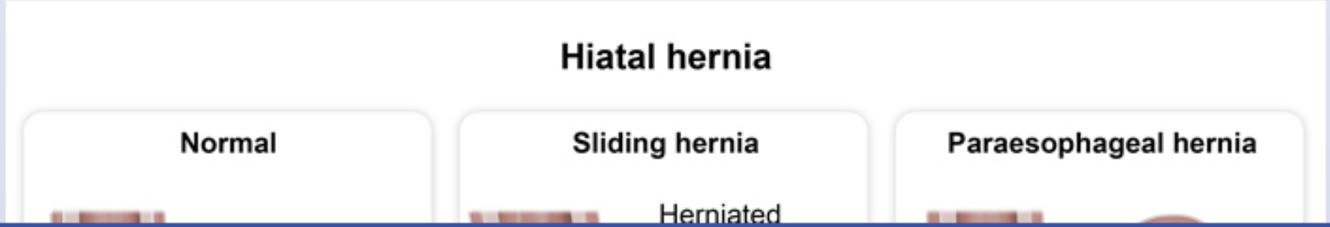

1
2
3
4
5
6
7
8
9
10
11
12
13
14
15
16
17
18
19
20
21
22
23
24
25
26
27
28
29
30
31

Hiatal hernia

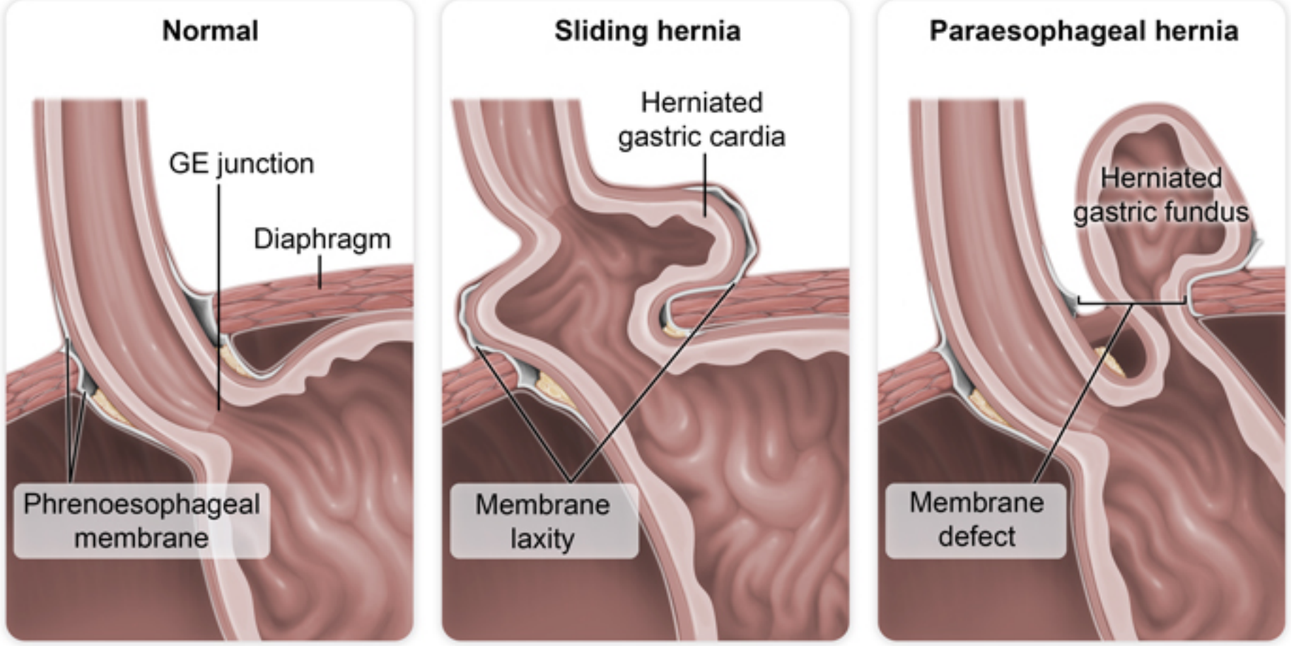

GE = gastroesophageal.

©UWorld

This patient has a **hiatal hernia**, a common disorder in which the contents of the abdominal cavity herniate through the diaphragm into the thoracic cavity at the esophageal hiatus. The distal esophagus is normally attached circumferentially to the diaphragm by the **phrenoesophageal membrane** at the gastroesophageal (GE) junction; disruptions in membrane integrity can result in hernia formation:

- **Sliding** hiatal hernias are the most common form and occur due to **laxity** of the phrenoesophageal membrane, which typically results from repetitive stress on the membrane (eg, coughing, vomiting). This allows the **GE junction** and **proximal stomach** to slide upward into the thoracic cavity and predisposes patients to reflux symptoms (eg, heartburn, regurgitation, epigastric/chest pain) due to incompetence of the lower esophageal sphincter.

- **Sliding** hiatal hernias are the most common form and occur due to **laxity** of the phrenoesophageal membrane, which typically results from repetitive stress on the membrane (eg, coughing, vomiting). This allows the **GE junction** and **proximal stomach** to slide upward into the thoracic cavity and predisposes patients to reflux symptoms (eg, heartburn, regurgitation, epigastric/chest pain) due to incompetence of the lower esophageal sphincter.
- **Paraesophageal** hernias are rarer and occur due to a **defect** (hole) in the phrenoesophageal membrane. Laxity of the gastrocolic and gastrosplenic ligaments (which anchor the stomach in the abdomen) allows the **gastric fundus** to migrate into the thoracic cavity. Larger defects can also result in the subsequent herniation of the GE junction and surrounding structures (eg, bowel, spleen) into the chest. This predisposes patients to gastric volvulus, ulcerations, and respiratory complications (due to lung compression).

(Choice A) Barrett esophagus is the metaplastic replacement of normal squamous cells in the distal esophagus with squamocolumnar cells and occurs as a result of chronic acid reflux. Patients with Barrett esophagus are at increased risk of esophageal cancer, but it does not cause herniation.

(Choice C) Diaphragmatic muscle paralysis due to C3-5 motor nerve injury causes an elevated hemidiaphragm. Patients are typically asymptomatic (due to compensation by the other respiratory muscles), but dyspnea or orthopnea can occur. It is not associated with herniation of intrabdominal contents into the chest.

(Choice D) Failure of the posterolateral diaphragmatic foramina to fuse can cause a Bochdalek hernia. This congenital hernia is typically diagnosed pre- or perinatally; pulmonary hypoplasia with neonatal respiratory distress is common.

(Choice E) Herniation of the viscera through the omental foramen (foramen of Winslow) causes an intraabdominal hernia known as lesser sac hernia. Lesser sac hernias are very rare, typically involve the small bowel, and cause severe abdominal pain due to bowel strangulation or obstruction.

Educational objective:
Hiatal hernias occur when contents of the abdominal cavity herniate through the diaphragm at the esophageal hiatus into the thoracic cavity. Sliding hiatal hernias occur due to laxity of the phrenoesophageal membrane, leading to herniation of the gastroesophageal junction and proximal stomach, whereas paraesophageal hernias occur due to defects in the membrane, resulting in the gastric fundus herniation.

lower esophageal sphincter.

- **Paraesophageal** hernias are rarer and occur due to a **defect** (hole) in the phrenoesophageal membrane. Laxity of the gastrocolic and gastrosplenic ligaments (which anchor the stomach in the abdomen) allows the **gastric fundus** to migrate into the thoracic cavity. Larger defects can also result in the subsequent herniation of the GE junction and surrounding structures (eg, bowel, spleen) into the chest. This predisposes patients to gastric volvulus, ulcerations, and respiratory complications (due to lung compression).

(Choice A) Barrett esophagus is the metaplastic replacement of normal squamous cells in the distal esophagus with squamocolumnar cells and occurs as a result of chronic acid reflux. Patients with Barrett esophagus are at increased risk of esophageal cancer, but it does not cause herniation.

(Choice C) Diaphragmatic muscle paralysis due to C3-5 motor nerve injury causes an elevated hemidiaphragm. Patients are typically asymptomatic (due to compensation by the other respiratory muscles), but dyspnea or orthopnea can occur. It is not associated with herniation of intrabdominal contents into the chest.

(Choice D) Failure of the posterolateral diaphragmatic foramina to fuse can cause a Bochdalek hernia. This congenital hernia is typically diagnosed pre- or perinatally; pulmonary hypoplasia with neonatal respiratory distress is common.

(Choice E) Herniation of the viscera through the omental foramen (foramen of Winslow) causes an intraabdominal hernia known as lesser sac hernia. Lesser sac hernias are very rare, typically involve the small bowel, and cause severe abdominal pain due to bowel strangulation or obstruction.

Educational objective:
Hiatal hernias occur when contents of the abdominal cavity herniate through the diaphragm at the esophageal hiatus into the thoracic cavity. Sliding hiatal hernias occur due to laxity of the phrenoesophageal membrane, leading to herniation of the gastroesophageal junction and proximal stomach, whereas paraesophageal hernias occur due to defects in the membrane, resulting in the gastric fundus herniation.

Anatomy	Gastrointestinal & Nutrition	Hiatal hernia
Subject	System	Topic

Copyright © UWorld. All rights reserved.

1
2
3
4
5
6
7
8
9
10
11
12
13
14
15
16
17
18
19
20
21
22
23
24
25
26
27
28
29
30
31

A 26-year-old previously healthy man is brought to the emergency department after a motor vehicle collision. The patient was driving while wearing a seatbelt when his car was hit on the left side by another vehicle. He has since had persistent left shoulder pain. He also has nausea and hiccups. The patient's blood pressure is 90/60 mm Hg and pulse is 115/min. On examination, he has a bruise on the left lower chest wall with tenderness to palpation along the area. Chest auscultation reveals normal heart sounds and bilaterally equal breath sounds. He has a rigid and tender abdomen. Which of the following is the most likely diagnosis?

- A. Aortic rupture
- B. Hemopericardium
- C. Humerus fracture
- D. Lung contusion
- E. Myocardial contusion
- F. Pneumothorax
- G. Splenic laceration

Submit

A 26-year-old previously healthy man is brought to the emergency department after a motor vehicle collision. The patient was driving while wearing a seatbelt when his car was hit on the left side by another vehicle. He has since had persistent left shoulder pain. He also has nausea and hiccups. The patient's blood pressure is 90/60 mm Hg and pulse is 115/min. On examination, he has a bruise on the left lower chest wall with tenderness to palpation along the area. Chest auscultation reveals normal heart sounds and bilaterally equal breath sounds. He has a rigid and tender abdomen. Which of the following is the most likely diagnosis?

A. Aortic rupture (3%)
B. Hemopericardium (4%)
C. Humerus fracture (0%)
D. Lung contusion (3%)
E. Myocardial contusion (1%)
F. Pneumothorax (1%)
✓ G. Splenic laceration (85%)

Omitted
Correct answer
G

85%
Answered correctly

02 secs
Time Spent

04/25/2020
Last Updated

Explanation

This patient's rigid abdomen with associated left shoulder pain, hypotension, and tachycardia suggests a possible **splenic laceration** and hemoperitoneum. The shoulder pain likely represents referred pain due to peritoneal irritation (**Kehr sign**).

This patient's rigid abdomen with associated left shoulder pain, hypotension, and tachycardia suggests a possible **splenic laceration** and hemoperitoneum. The shoulder pain likely represents referred pain due to peritoneal irritation (**Kehr sign**).

The phrenic nerves originate from C3-C5 and pass between the lung and heart to provide motor function to the diaphragm. The phrenic nerves also provide sensory fibers to the pericardium, mediastinal pleura, and diaphragmatic peritoneum. The supraclavicular nerves originate from C3-C4 and their branches innervate the sternoclavicular joint, local muscles (eg, sternocleidomastoid), and the skin of the upper and posterior shoulder. Any abdominal process (eg, ruptured spleen, peritonitis, hemoperitoneum) irritating the sensory fibers around the diaphragm can cause **referred pain** via the phrenic nerve to the C3-C5 shoulder region. Phrenic nerve irritation can also cause **hiccups** due to spasmodic diaphragmatic contraction pulling air against a closed larynx.

(Choice A) Traumatic aortic rupture presents with chest wall contusions and hypotension, but it is not typically associated with persistent left shoulder pain or hiccups.

(Choices B and D) Hemopericardium (blood accumulation in the pericardial sac) typically presents with shortness of breath, tachycardia, jugular venous distention, and possible hypotension. Lung contusion usually presents gradually with shortness of breath, chest pain, and consolidation on lung imaging. However, persistent shoulder pain is not commonly associated with either condition.

(Choice C) Humerus fracture typically presents with acute shoulder pain that is increased with movement. Examination can show a deformed shoulder joint. This patient's rigid abdomen and absence of obvious shoulder abnormalities make this less likely.

(Choice E) Myocardial contusion after chest wall trauma typically presents with mid-anterior chest wall pain, shortness of breath, persistent tachycardia, and new conduction defects on ECG (eg, bundle branch block). It is not typically associated with persistent abdominal or shoulder pain.

(Choice F) Pneumothorax after chest trauma usually presents with tachypnea, shortness of breath, decreased or absent breath sounds, unilateral hyperresonance to percussion, and pleuritic chest pain. This patient's bilaterally equal breath sounds make this unlikely.

Educational objective:
Any abdominal process (eg, ruptured spleen, peritonitis, hemoperitoneum) irritating the phrenic nerve sensory fibers around the diaphragm can cause referred pain to the C3-C5 shoulder region (Kehr sign).

1
2
3
4
5
6
7
8
9
10
11
12
13
14
15
16
17
18
19
20
21
22
23
24
25
26
27
28
29
30
31

referred pain via the phrenic nerve to the C3-C5 shoulder region. Phrenic nerve irritation can also cause **hiccups** due to spasmodic diaphragmatic contraction pulling air against a closed larynx.

(Choice A) Traumatic aortic rupture presents with chest wall contusions and hypotension, but it is not typically associated with persistent left shoulder pain or hiccups.

(Choices B and D) Hemopericardium (blood accumulation in the pericardial sac) typically presents with shortness of breath, tachycardia, jugular venous distention, and possible hypotension. Lung contusion usually presents gradually with shortness of breath, chest pain, and consolidation on lung imaging. However, persistent shoulder pain is not commonly associated with either condition.

(Choice C) Humerus fracture typically presents with acute shoulder pain that is increased with movement. Examination can show a deformed shoulder joint. This patient's rigid abdomen and absence of obvious shoulder abnormalities make this less likely.

(Choice E) Myocardial contusion after chest wall trauma typically presents with mid-anterior chest wall pain, shortness of breath, persistent tachycardia, and new conduction defects on ECG (eg, bundle branch block). It is not typically associated with persistent abdominal or shoulder pain.

(Choice F) Pneumothorax after chest trauma usually presents with tachypnea, shortness of breath, decreased or absent breath sounds, unilateral hyperresonance to percussion, and pleuritic chest pain. This patient's bilaterally equal breath sounds make this unlikely.

Educational objective:
Any abdominal process (eg, ruptured spleen, peritonitis, hemoperitoneum) irritating the phrenic nerve sensory fibers around the diaphragm can cause referred pain to the C3-C5 shoulder region (Kehr sign).

References

- Traditional Kehr's sign: Left shoulder pain related to splenic abscess.

Anatomy	Gastrointestinal & Nutrition	Spleen rupture
Subject	System	Topic

Copyright © UWorld. All rights reserved.

A 65-year-old man with a history of hypertension, type 2 diabetes mellitus, and tobacco smoking comes to the office reporting mild back pain. Abdominal examination reveals a bruit, but no pulsatile mass is palpated. Femoral and pedal pulses are symmetric. The patient is sent for ultrasound and is found to have a large infrarenal abdominal aortic aneurysm. Open aneurysm repair is performed. During the procedure, the inferior mesenteric artery is ligated, the diseased portion of the aorta is dissected, and a graft is placed from below the renal arteries to the bifurcation of the aorta. Collateral circulation from which of the following vessels is most likely responsible for preventing ischemia of the descending colon?

- A. Celiac trunk
- B. External iliac artery
- C. Inferior vena cava
- D. Internal iliac artery
- E. Portal vein
- F. Renal artery
- G. Superior mesenteric artery

Submit

A 65-year-old man with a history of hypertension, type 2 diabetes mellitus, and tobacco smoking comes to the office reporting mild back pain. Abdominal examination reveals a bruit, but no pulsatile mass is palpated. Femoral and pedal pulses are symmetric. The patient is sent for ultrasound and is found to have a large infrarenal abdominal aortic aneurysm. Open aneurysm repair is performed. During the procedure, the inferior mesenteric artery is ligated, the diseased portion of the aorta is dissected, and a graft is placed from below the renal arteries to the bifurcation of the aorta. Collateral circulation from which of the following vessels is most likely responsible for preventing ischemia of the descending colon?

- A. Celiac trunk (2%)
- B. External iliac artery (6%)
- C. Inferior vena cava (0%)
- D. Internal iliac artery (20%)
- E. Portal vein (1%)
- F. Renal artery (2%)
- ✓ G. Superior mesenteric artery (65%)

Omitted
Correct answer
G

65%
Answered correctly

02 secs
Time Spent

02/06/2020
Last Updated

Explanation

Arteries of the large intestine

1
2
3
4
5
6
7
8
9
10
11
12
13
14
15
16
17
18
19
20
21
22
23
24
25
26
27
28
29
30
31

Arteries of the large intestine

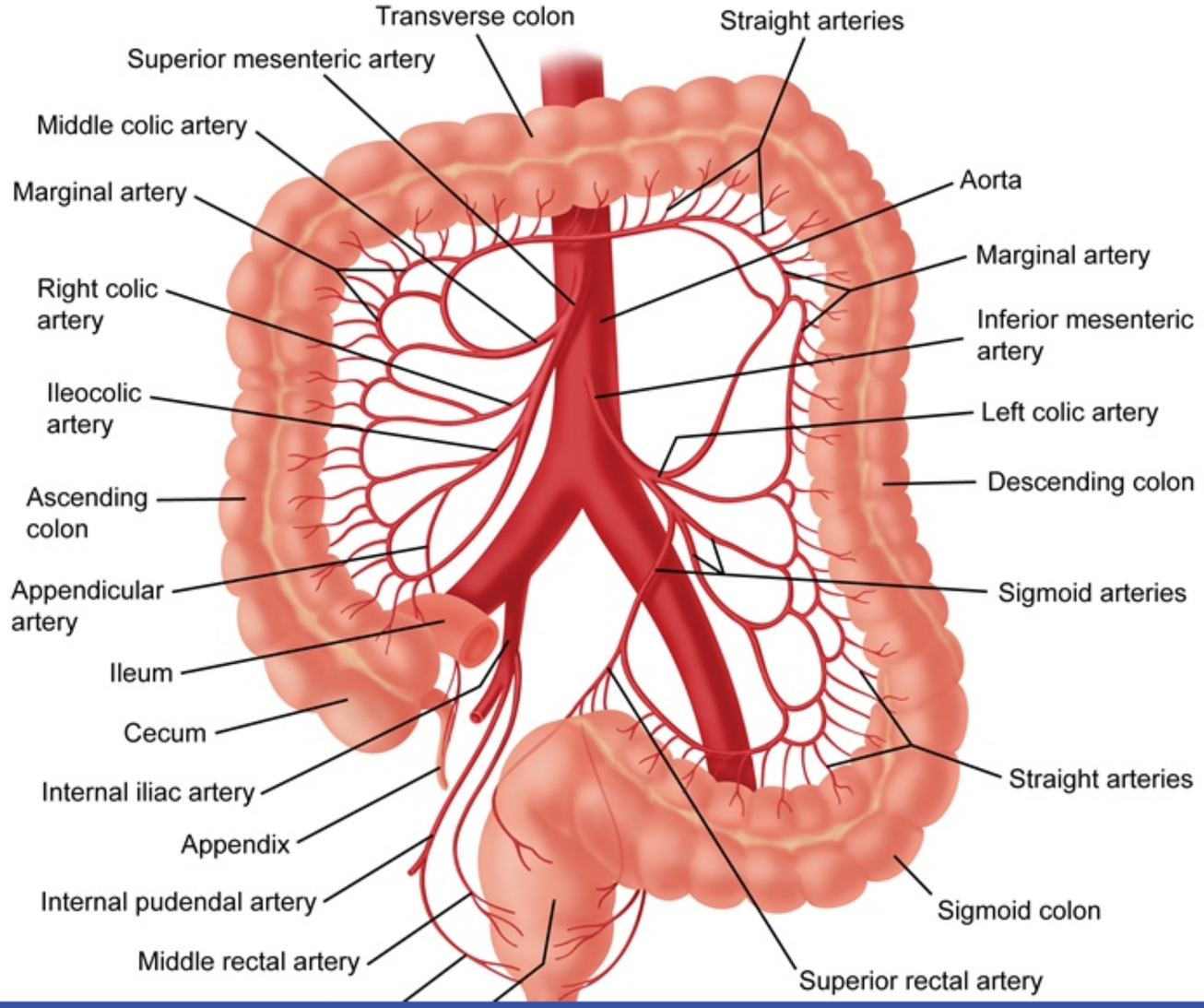

The gastrointestinal tract receives its blood supply from 3 main arteries:

- Celiac trunk
- **Superior mesenteric artery** (SMA)
- **Inferior mesenteric artery** (IMA)

The celiac trunk supplies the stomach, part of the duodenum, gallbladder, liver, spleen, and pancreas **(Choice A)**. The SMA and IMA are the 2 main vessels supplying the small and large intestines and are connected by a pair of anastomoses: the **marginal artery** of Drummond, which is the principal **anastomosis**, and the inconsistently present arc of Riolan (mesenteric meandering artery). These anastomoses protect the intestines from ischemia and, due to the marginal artery, the IMA is not always reconnected during aortic aneurysm repair.

(Choice B) The external iliac artery supplies the inferior epigastric artery and the deep circumflex iliac artery before becoming the femoral artery. Although the inferior epigastric artery anastomoses with the superior epigastric artery, these provide blood supply to the abdominal wall, not the intestines.

(Choices C and E) The inferior vena cava (IVC) has little role in the direct drainage of the intestines except from the rectum, which partially drains via the middle and inferior rectal veins into the internal iliac veins. The remainder of the venous drainage occurs via the superior and inferior mesenteric veins, which drain into the portal vein. After perfusing the liver, the portal vein drains into the IVC via the hepatic veins.

(Choice D) The internal iliac artery supplies part of the rectum via the middle rectal artery. An anastomosis exists between the superior and middle rectal arteries, which can help prevent rectal ischemia after IMA occlusion. However, the SMA is more likely to prevent ischemia in the descending colon due to its proximity and the extensive collateral arcades between the SMA and IMA.

(Choice F) Although the renal arteries arise from the abdominal aorta just inferior to the SMA, they do not provide collateral circulation to the intestines.

Educational objective:
The superior mesenteric artery and inferior mesenteric artery are the 2 main vessels supplying the small and large intestines. They are connected by a pair of anastomoses: the marginal artery of Drummond, which is the principal anastomosis, and the inconsistently present arc of Riolan (mesenteric meandering artery).

References

- Clinical interest of digestive arterial trunk anastomoses

the principal **anastomosis**, and the inconsistently present arc of Riolan (mesenteric meandering artery). These anastomoses protect the intestines from ischemia and, due to the marginal artery, the IMA is not always reconnected during aortic aneurysm repair.

(Choice B) The external iliac artery supplies the inferior epigastric artery and the deep circumflex iliac artery before becoming the femoral artery. Although the inferior epigastric artery anastomoses with the superior epigastric artery, these provide blood supply to the abdominal wall, not the intestines.

(Choices C and E) The inferior vena cava (IVC) has little role in the direct drainage of the intestines except from the rectum, which partially drains via the middle and inferior rectal veins into the internal iliac veins. The remainder of the venous drainage occurs via the superior and inferior mesenteric veins, which drain into the portal vein. After perfusing the liver, the portal vein drains into the IVC via the hepatic veins.

(Choice D) The internal iliac artery supplies part of the rectum via the middle rectal artery. An anastomosis exists between the superior and middle rectal arteries, which can help prevent rectal ischemia after IMA occlusion. However, the SMA is more likely to prevent ischemia in the descending colon due to its proximity and the extensive collateral arcades between the SMA and IMA.

(Choice F) Although the renal arteries arise from the abdominal aorta just inferior to the SMA, they do not provide collateral circulation to the intestines.

Educational objective:
The superior mesenteric artery and inferior mesenteric artery are the 2 main vessels supplying the small and large intestines. They are connected by a pair of anastomoses: the marginal artery of Drummond, which is the principal anastomosis, and the inconsistently present arc of Riolan (mesenteric meandering artery).

References

- Clinical interest of digestive arterial trunk anastomoses.
- Rare case of "wandering artery of drummond" as a result of chronic triple mesenteric vessel occlusion treated by isolated angioplasty and stenting of the inferior mesenteric artery.

Anatomy	Gastrointestinal & Nutrition	Aortic aneurysm
Subject	System	Topic

the principal **anastomosis**, and the inconsistently present arc of Riolan (mesenteric meandering artery). These anastomoses protect the

Exhibit Display

Branches of common iliac artery

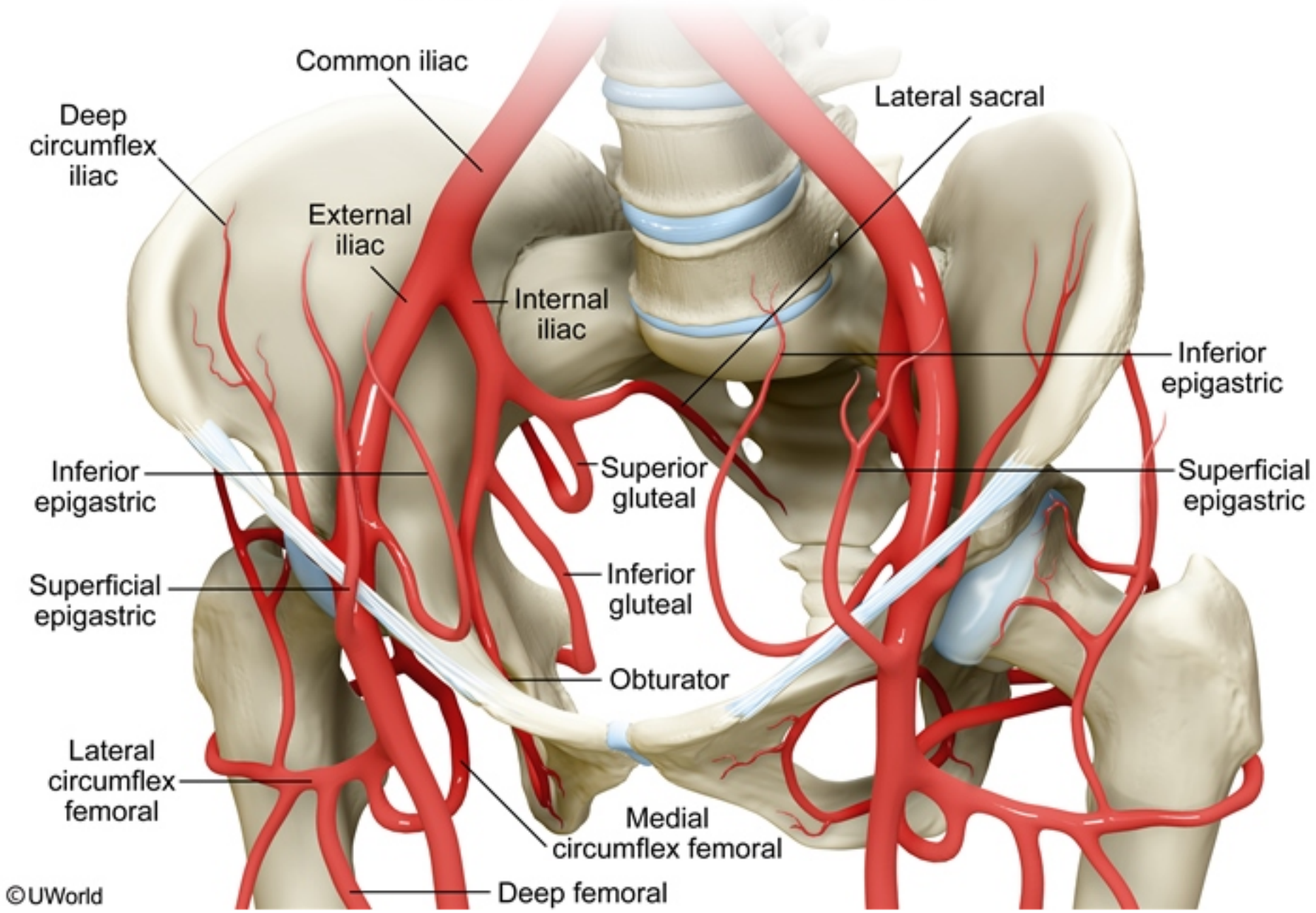

Zoom In | Zoom Out | Reset | Add To New Card | Existing Card

the principal **anastomosis**, and the inconsistently present arc of Riolan (mesenteric meandering artery). These anastomoses protect the

Exhibit Display

Portal venous system

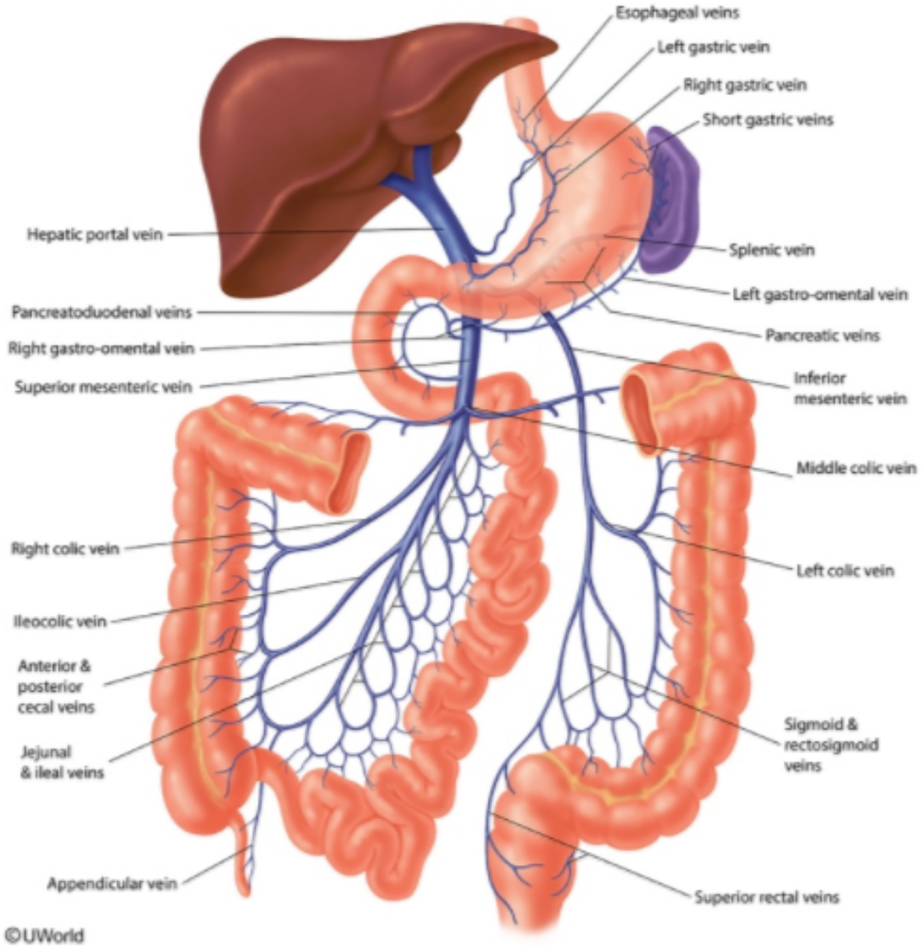

Zoom In | Zoom Out | Reset | Add To New Card | Existing Card

A 46-year-old man comes to the emergency department due to severe anal pain. He has a history of chronic constipation and on several occasions has noticed streaks of blood on the tissue paper after wiping. He has no abdominal pain, nausea, vomiting, or weight loss and has no family history of malignancy. His temperature is 36.7 C (98 F). On examination, there are several large, purplish-blue sacs bulging into the anal canal, one of which originates below the dentate line and is extremely tender. Excision of the tender lesion under local anesthesia is planned. The anesthetic agent most likely blocks sensory impulses carried by which of the following structures?

- A. Ilioinguinal nerve
- B. Inferior gluteal nerve
- C. Inferior hypogastric plexus
- D. Pelvic splanchnic nerves
- E. Pudendal nerve

Submit

A 46-year-old man comes to the emergency department due to severe anal pain. He has a history of chronic constipation and on several occasions has noticed streaks of blood on the tissue paper after wiping. He has no abdominal pain, nausea, vomiting, or weight loss and has no family history of malignancy. His temperature is 36.7 C (98 F). On examination, there are several large, purplish-blue sacs bulging into the anal canal, one of which originates below the dentate line and is extremely tender. Excision of the tender lesion under local anesthesia is planned. The anesthetic agent most likely blocks sensory impulses carried by which of the following structures?

- A. Ilioinguinal nerve (3%)
- B. Inferior gluteal nerve (5%)
- C. Inferior hypogastric plexus (3%)
- D. Pelvic splanchnic nerves (5%)
- ✓ E. Pudendal nerve (83%)

Omitted
Correct answer
E

83%
Answered correctly

01 sec
Time Spent

05/04/2020
Last Updated

Explanation

This patient has both internal and **external hemorrhoids**, which each have a distinct epithelial lining and innervation. Internal hemorrhoids originate above the dentate line and are covered by columnar epithelium. They have autonomic innervation from the inferior hypogastric plexus, which is only sensitive to stretch and not pain, temperature, or touch.

External hemorrhoids, which originate below the dentate line, are covered by modified squamous epithelium and have cutaneous (somatic)

1
2
3
4
5
6
7
8
9
10
11
12
13
14
15
16
17
18
19
20
21
22
23
24
25
26
27
28
29
30
31

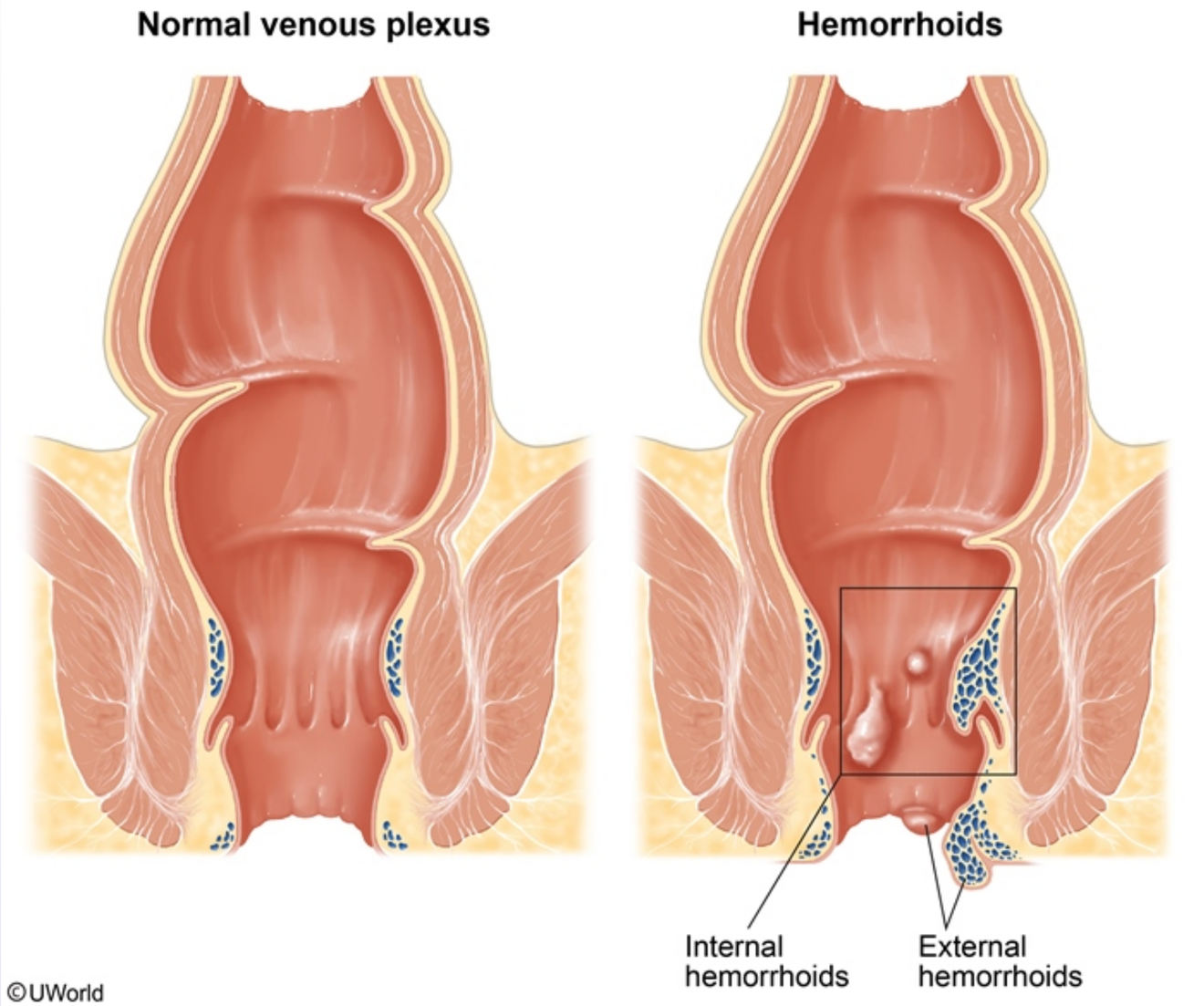

This patient has both internal and **external hemorrhoids**, which each have a distinct epithelial lining and innervation. Internal hemorrhoids originate above the dentate line and are covered by columnar epithelium. They have autonomic innervation from the inferior hypogastric plexus.

This patient has both internal and **external hemorrhoids**, which each have a distinct epithelial lining and innervation. Internal hemorrhoids originate above the dentate line and are covered by columnar epithelium. They have autonomic innervation from the inferior hypogastric plexus, which is only sensitive to stretch and not pain, temperature, or touch.

External hemorrhoids, which originate below the dentate line, are covered by modified squamous epithelium and have cutaneous (somatic) nervous innervation from the inferior rectal nerve, a branch of the pudendal nerve. **Branches** of the **pudendal nerve** supply the perineum and external genitalia in males and females and are very sensitive to touch, temperature, and **pain**. External hemorrhoids are generally asymptomatic but can become exquisitely painful if they thrombose, as in this case.

(Choice A) The ilioinguinal nerve is mostly sensory, derived from L1, and carries sensation from skin of the upper and medial part of the thigh, the root of the penis and upper part of the scrotum in males, and the mons pubis and labia majora in females.

(Choice B) The inferior gluteal nerve, composed of branches of L5, S1, and S2, is the main nerve supplying motor functions to the gluteus maximus muscle.

(Choice C) The inferior hypogastric plexus, which has both sympathetic and parasympathetic components, innervates the internal pelvic viscera but not the external perirectal area.

(Choice D) The pelvic splanchnic nerves are derived from S2, S3, and S4 and provide parasympathetic innervation to the pelvic and genital organs.

Educational objective:
External hemorrhoids, which originate below the dentate line, are covered by modified squamous epithelium and have cutaneous (somatic) nervous innervation from the inferior rectal nerve, a branch of the pudendal nerve.

References

- Hemorrhoids.
- Hemorrhoids.

Anatomy	Gastrointestinal & Nutrition	Hemorrhoids
Subject	System	Topic

1
2
3
4
5
6
7
8
9
10
11
12
13
14
15
16
17
18
19
20
21
22
23
24
25
26
27
28
29
30
31

A 47-year-old man comes to the office due to dysphagia. The patient says that it feels like food has been getting stuck in his throat over the last month. He has changed his diet to accommodate his symptoms and now consumes only liquid foods. The patient has a long history of postprandial heartburn that sometimes awakens him from sleep. He has treated his heartburn with over-the-counter antacids but usually only has partial relief. A thoracic CT image near the level of the aortic arch is shown below. This patient's symptoms are most likely related to pathology involving which of the following structures?

A. A

B. B

C. C

D. D

4
5
6
7
8
9
10
11
12
13
14
15
16
17
18
19
20
21
22
23
24
25
26
27
28
29
30
31
32
33
34

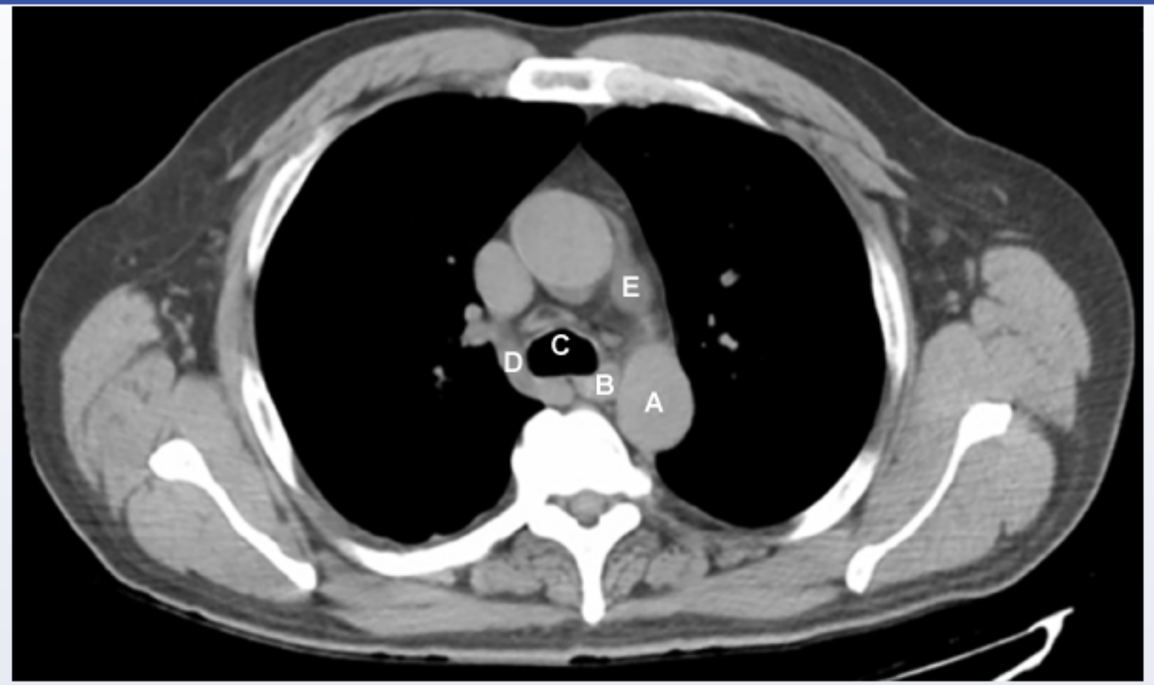

A. A

B. B

C. C

D. D

E. E

Submit

4
5
6
7
8
9
10
11
12
13
14
15
16
17
18
19
20
21
22
23
24
25
26
27
28
29
30
31
32
33
34

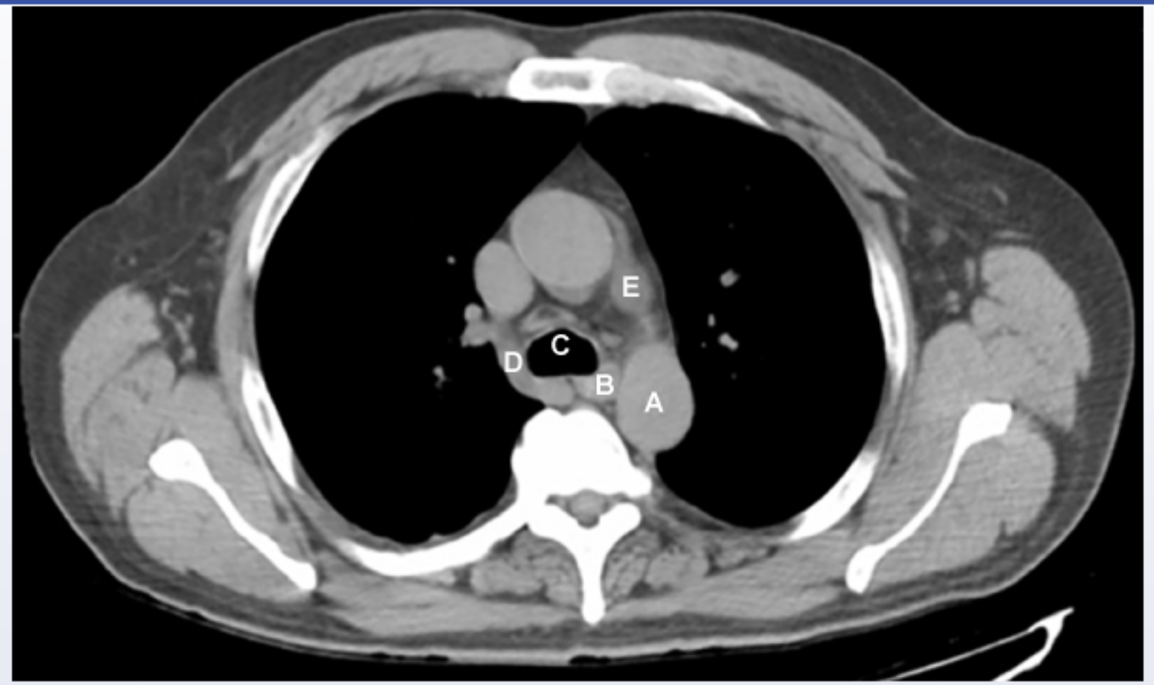

A. A (3%)

✓ B. B (56%)

C. C (26%)

D. D (8%)

E. E (4%)

Omitted
Correct answer

56%
Answered correctly

06 secs
Time Spent

05/04/2020
Last Updated

4
5
6
7
8
9
10
11
12
13
14
15
16
17
18
19
20
21
22
23
24
25
26
27
28
29
30
31
32
33
34

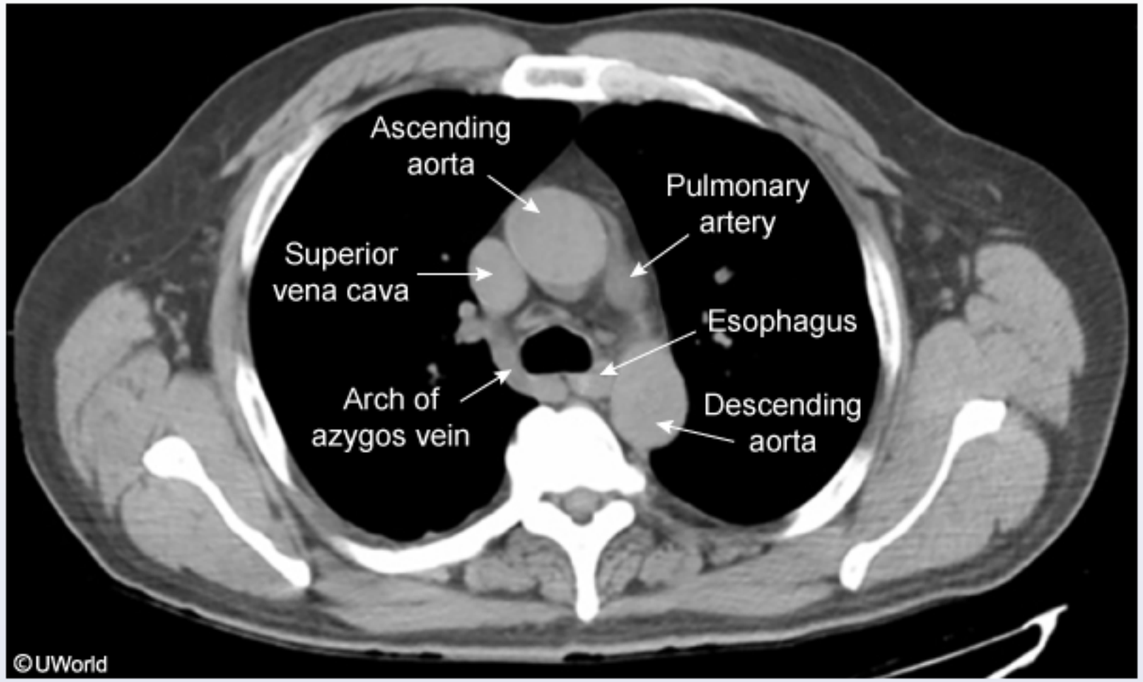

This patient's prolonged history of heartburn is suggestive of **gastroesophageal reflux disease** (GERD), a condition that affects the esophagus. **Dysphagia** (ie, difficulty swallowing) is common in patients with longstanding GERD and can be caused by impaired peristalsis, esophageal inflammation/stricture, or malignancy.

In the thorax, the **esophagus** courses between the **trachea and vertebral bodies** and is typically collapsed with **no visible lumen**. The trachea serves as a good landmark because the radiolucency of the air in this structure allows one to differentiate it from the esophagus posteriorly and the great vessels anteriorly **(Choice C)**.

(Choice A) This is the descending aorta.

(Choice D) This is the arch of the azygos vein as it curves over the right main bronchus to join with the superior vena cava. The azygos vein itself ascends along the thoracic vertebral column to the right of the esophagus.

4
5
6
7
8
9
10
11
12
13
14
15
16
17
18
19
20
21
22
23
24
25
26
27
28
29
30
31
32
33
34

This patient's prolonged history of heartburn is suggestive of **gastroesophageal reflux disease** (GERD), a condition that affects the esophagus. **Dysphagia** (ie, difficulty swallowing) is common in patients with longstanding GERD and can be caused by impaired peristalsis, esophageal inflammation/stricture, or malignancy.

In the thorax, the **esophagus** courses between the **trachea and vertebral bodies** and is typically collapsed with **no visible lumen**. The trachea serves as a good landmark because the radiolucency of the air in this structure allows one to differentiate it from the esophagus posteriorly and the great vessels anteriorly **(Choice C)**.

(Choice A) This is the descending aorta.

(Choice D) This is the arch of the azygos vein as it curves over the right main bronchus to join with the superior vena cava. The azygos vein itself ascends along the thoracic vertebral column to the right of the esophagus.

(Choice E) This is a section of the top of the pulmonary artery as it passes underneath the aortic arch.

Educational objective:
The esophagus is located between the trachea and the vertebral bodies in the superior thorax. It is typically collapsed with no visible lumen on CT images of the chest.

Anatomy	Gastrointestinal & Nutrition	Gastroesophageal reflux disease
Subject	System	Topic

Copyright © UWorld. All rights reserved.

4
5
6
7
8
9
10
11
12
13
14
15
16
17
18
19
20
21
22
23
24
25
26
27
28
29
30
31
32
33
34

A 64-year-old man comes to the emergency department after an episode of hematemesis. He also reports dark stools and abdominal pain for the past several days. The patient has a history of chronic pancreatitis. Abdominal examination shows epigastric tenderness to palpation. Rectal examination is notable for black, guaiac-positive feces. Upper gastrointestinal endoscopy reveals a bleeding spot within a cluster of enlarged tortuous veins in the gastric fundus. The rest of the stomach and esophagus appears normal. Increased pressure in which of the following vascular structures is the most likely cause of this patient's condition?

A. Azygos vein
B. Left gastric vein
C. Pancreaticoduodenal vein
D. Splenic vein
E. Superior mesenteric vein

Submit

4
5
6
7
8
9
10
11
12
13
14
15
16
17
18
19
20
21
22
23
24
25
26
27
28
29
30
31
32
33
34

A 64-year-old man comes to the emergency department after an episode of hematemesis. He also reports dark stools and abdominal pain for the past several days. The patient has a history of chronic pancreatitis. Abdominal examination shows epigastric tenderness to palpation. Rectal examination is notable for black, guaiac-positive feces. Upper gastrointestinal endoscopy reveals a bleeding spot within a cluster of enlarged tortuous veins in the gastric fundus. The rest of the stomach and esophagus appears normal. Increased pressure in which of the following vascular structures is the most likely cause of this patient's condition?

A. Azygos vein (6%)
B. Left gastric vein (51%)
C. Pancreaticoduodenal vein (7%)
✓ D. Splenic vein (30%)
E. Superior mesenteric vein (3%)

Omitted
Correct answer
D

30%
Answered correctly

02 secs
Time Spent

05/26/2020
Last Updated

Explanation

4
5
6
7
8
9
10
11
12
13
14
15
16
17
18
19
20
21
22
23
24
25
26
27
28
29
30
31
32
33
34

Splenic vein thrombosis

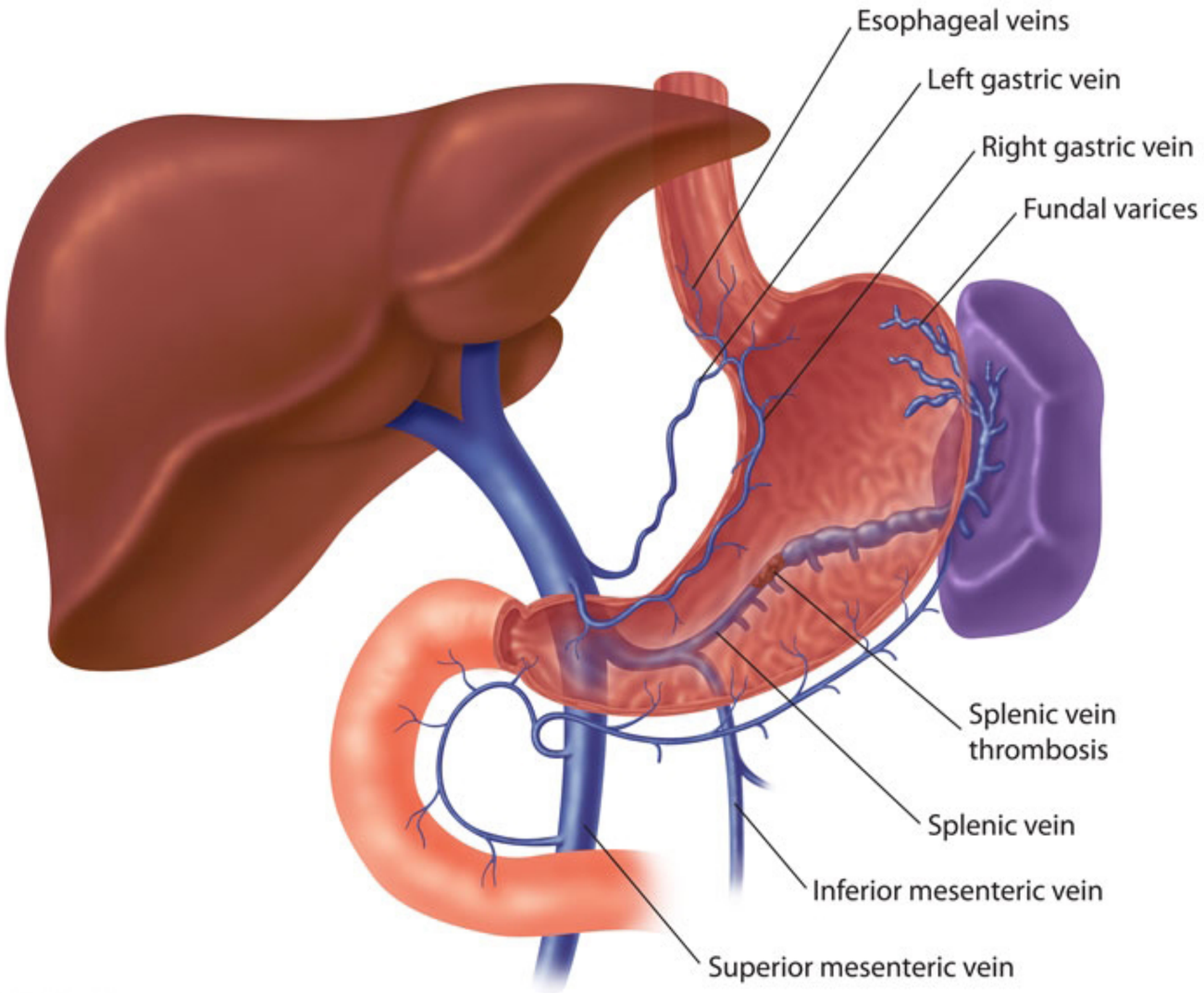

©UWorld

4
5
6
7
8
9
10
11
12
13
14
15
16
17
18
19
20
21
22
23
24
25
26
27
28
29
30
31
32
33
34

Superior mesenteric vein

©UWorld

Gastric varices are dilated submucosal veins that can cause life-threatening bleeding in the upper gastrointestinal tract. The varices are commonly due to portal hypertension, which can be a complication of cirrhosis. Gastric varices can also be seen with **splenic vein thrombosis** due to chronic pancreatitis, pancreatic cancer, and abdominal tumors. The splenic vein runs along the posterior surface of the pancreas and can develop a blood clot from pancreatic inflammation. The **short gastric veins** drain the fundus of the stomach into the splenic vein. Splenic vein thrombosis can increase pressure in the short gastric veins and cause **gastric varices** only in the **fundus**. The rest of the stomach and esophagus are usually not affected.

(Choice A) The azygos vein drains blood from the esophageal veins into the superior vena cava. The formation of esophageal varices in the setting of portal hypertension provides collateral drainage from the portal venous system to the azygos system. The azygos vein also provides collateral circulation between the superior and inferior vena cava and can become enlarged with caval obstruction.

(Choice B) The left gastric vein drains blood from the upper stomach and lower esophagus into the portal vein. Portal hypertension can increase pressure in the left gastric veins and usually causes both gastric and esophageal varices.

(Choices C and E) The pancreaticoduodenal vein drains the pancreas and duodenum into the superior mesenteric vein (SMV). The SMV also drains blood from the lower stomach (via the right gastroepiploic vein) and small intestine. Blockage of the SMV could lead to variceal formation in the lower stomach, but not the upper regions.

Educational objective:
The short gastric veins drain blood from the gastric fundus into the splenic vein. Pancreatic inflammation (eg, pancreatitis, pancreatic cancer) can cause a blood clot within the splenic vein, which can increase pressure in the short gastric veins and lead to gastric varices only in the fundus.

References

- Repeated pancreatitis-induced splenic vein thrombosis leads to intractable gastric variceal bleeding: A case report and review.

Anatomy	Gastrointestinal & Nutrition	Chronic pancreatitis
Subject	System	Topic

Copyright © UWorld. All rights reserved.

4
5
6
7
8
9
10
11
12
13
14
15
16
17
18
19
20
21
22
23
24
25
26
27
28
29
30
31
32
33
34

A 56-year-old man comes to the cardiology clinic because of fatigue, palpitations, and exertional dyspnea over the last several weeks. On physical examination, his heart rate is irregular and measures 122 beats per minute, while his blood pressure is 110/70 mm Hg. The patient undergoes further work-up, including ECG, radiographic studies, and laboratory studies. His ECG shows atrial fibrillation and trans-esophageal echocardiography reveals a thrombus in a dilated left atrium. In the event of an interruption of blood flow secondary to arterial occlusion, which of the following organs would be least vulnerable to infarction?

A. Spleen
B. Brain
C. Kidney
D. Liver
E. Heart

Submit

A 56-year-old man comes to the cardiology clinic because of fatigue, palpitations, and exertional dyspnea over the last several weeks. On physical examination, his heart rate is irregular and measures 122 beats per minute, while his blood pressure is 110/70 mm Hg. The patient undergoes further work-up, including ECG, radiographic studies, and laboratory studies. His ECG shows atrial fibrillation and trans-esophageal echocardiography reveals a thrombus in a dilated left atrium. In the event of an interruption of blood flow secondary to arterial occlusion, which of the following organs would be least vulnerable to infarction?

- A. Spleen (9%)
- B. Brain (7%)
- C. Kidney (4%)
- ✓ D. Liver (67%)
- E. Heart (11%)

Omitted
Correct answer
D

67%
Answered correctly

02 secs
Time Spent

05/18/2020
Last Updated

Explanation

Infarcts in an otherwise normal liver are rare because it has a dual blood supply: the portal vein and hepatic artery. Should the hepatic artery become occluded, the portal venous supply and retrograde arterial flow through accessory vessels (e.g., from the inferior phrenic, adrenal, intercostal arteries, etc.) is typically sufficient to sustain the liver parenchyma. The notable exception is when a transplanted liver undergoes hepatic artery thrombosis. In this case, the liver can develop biliary tree infarction and organ failure because the collateral blood supply is severed during transplantation.

Infarcts in an otherwise normal liver are rare because it has a dual blood supply: the portal vein and hepatic artery. Should the hepatic artery become occluded, the portal venous supply and retrograde arterial flow through accessory vessels (e.g., from the inferior phrenic, adrenal, intercostal arteries, etc.) is typically sufficient to sustain the liver parenchyma. The notable exception is when a transplanted liver undergoes hepatic artery thrombosis. In this case, the liver can develop biliary tree infarction and organ failure because the collateral blood supply is severed during transplantation.

(Choice A) The spleen is relatively vulnerable to infarction because the perfusion via the splenic artery is end-arterial. Wedge-shaped, capsule-based splenic infarcts occur and are a known complication of sickle cell anemia, infective endocarditis, and cardiac mural thrombosis.

(Choice B) Irreversible damage appears to occur in the most vulnerable of neurons after approximately 5 minutes of complete ischemia.

(Choice C) The kidney, similar to the spleen, has an end-arterial blood supply, and is generally able to tolerate warm ischemia for at least 30 minutes. Longer periods of complete ischemia result in immediate functional loss; late recovery of renal function is incomplete or absent.

(Choice E) The myocardium can endure complete arterial ischemia for twenty or thirty minutes without severe consequences. Briefer periods of ischemia do not result in necrosis, but rather myocardial stunning. Coronary artery embolism is an uncommon cause of myocardial infarction; nonetheless, it should be considered in myocardial-infarcted patients with atrial fibrillation, infective endocarditis, left atrial or ventricular thrombus, and in patients undergoing cardiac catheterization.

Educational objective:
Organ susceptibility to infarction after occlusion of a feeding artery is ranked from greatest to least as follows: central nervous system, myocardium, kidney, spleen, and liver. The presence of a dual and/or collateral blood supply (as seen in the liver, which is supplied by the hepatic artery and portal vein) enables an organ to tolerate arterial occlusion better than those with end-arterial circulations.

References

- Regulation of hepatic blood flow: the hepatic arterial buffer response revisited.

Anatomy	Gastrointestinal & Nutrition	Ischemic hepatitis
Subject	System	Topic

Copyright © UWorld. All rights reserved.

4
5
6
7
8
9
10
11
12
13
14
15
16
17
18
19
20
21
22
23
24
25
26
27
28
29
30
31
32
33
34

A 71-year-old man comes to the emergency department due to several episodes of bright red blood per rectum. His recent colonoscopy revealed numerous colonic diverticula. Laboratory studies on admission are notable for a hemoglobin of 8.2 g/dL with an unremarkable coagulation profile. An abdominal angiogram shows active bleeding from the sigmoid colon. Catheter embolization is planned via the femoral artery. During the procedure, the arterial catheter is most likely to proceed in which of the following orders?

A. External iliac, common iliac, abdominal aorta, celiac

B. External iliac, common iliac, abdominal aorta, inferior mesenteric

C. External iliac, common iliac, abdominal aorta, superior mesenteric

D. External iliac, internal iliac, internal pudendal

E. External iliac, internal iliac, middle rectal

Submit

4
5
6
7
8
9
10
11
12
13
14
15
16
17
18
19
20
21
22
23
24
25
26
27
28
29
30
31
32
33
34

A 71-year-old man comes to the emergency department due to several episodes of bright red blood per rectum. His recent colonoscopy revealed numerous colonic diverticula. Laboratory studies on admission are notable for a hemoglobin of 8.2 g/dL with an unremarkable coagulation profile. An abdominal angiogram shows active bleeding from the sigmoid colon. Catheter embolization is planned via the femoral artery. During the procedure, the arterial catheter is most likely to proceed in which of the following orders?

A. External iliac, common iliac, abdominal aorta, celiac (1%)

✓ B. External iliac, common iliac, abdominal aorta, inferior mesenteric (86%)

C. External iliac, common iliac, abdominal aorta, superior mesenteric (5%)

D. External iliac, internal iliac, internal pudendal (3%)

E. External iliac, internal iliac, middle rectal (3%)

Omitted
Correct answer
B

86%
Answered correctly

02 secs
Time Spent

04/14/2020
Last Updated

Explanation

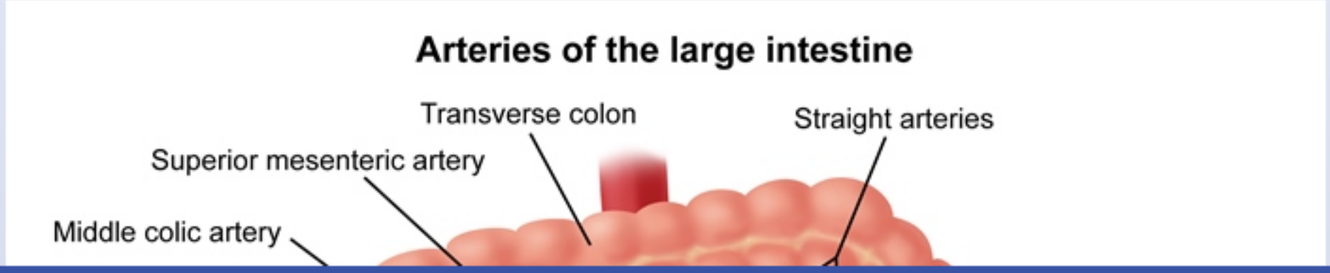

4
5
6
7
8
9
10
11
12
13
14
15
16
17
18
19
20
21
22
23
24
25
26
27
28
29
30
31
32
33
34

Arteries of the large intestine

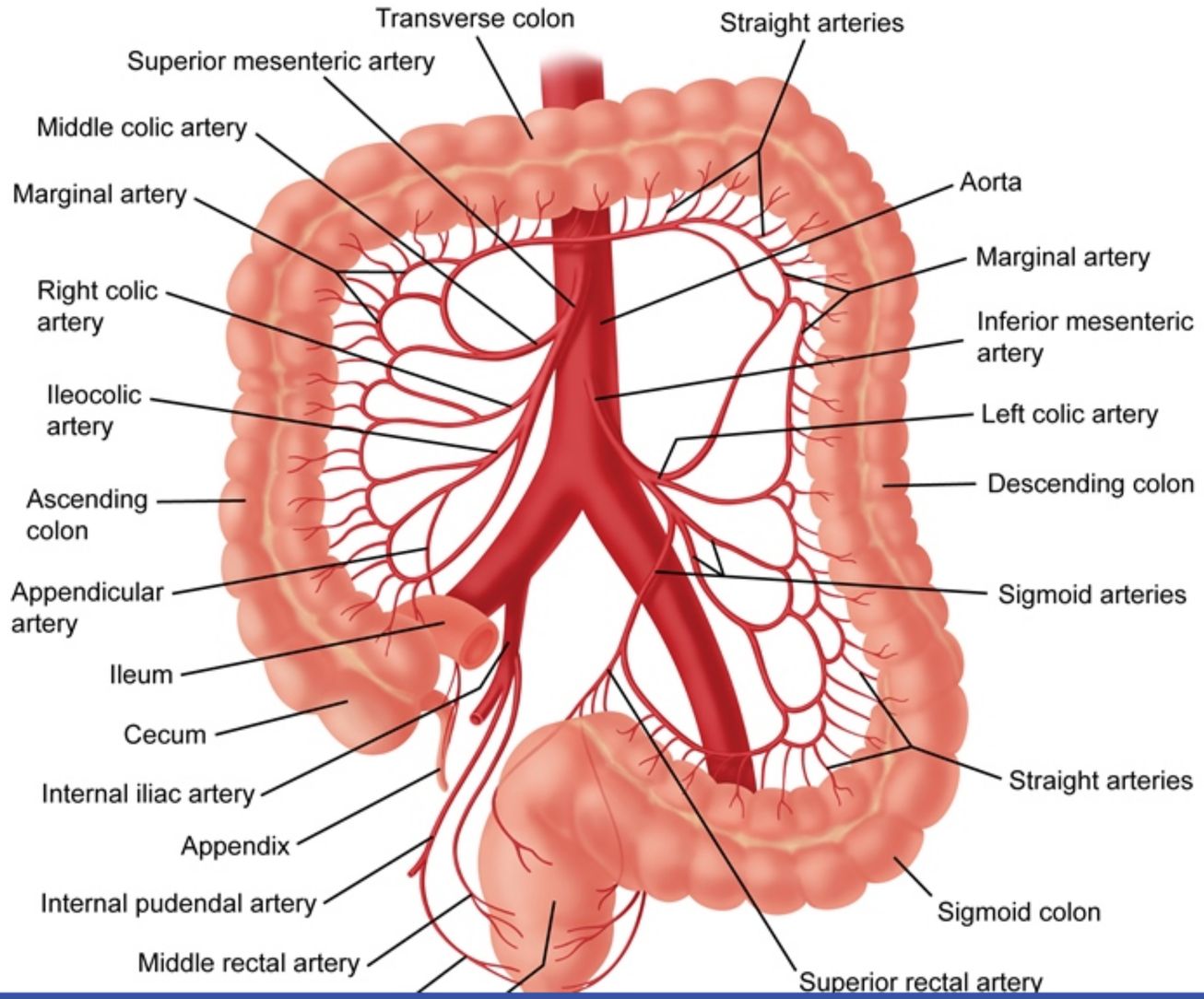

4
5
6
7
8
9
10
11
12
13
14
15
16
17
18
19
20
21
22
23
24
25
26
27
28
29
30
31
32
33
34

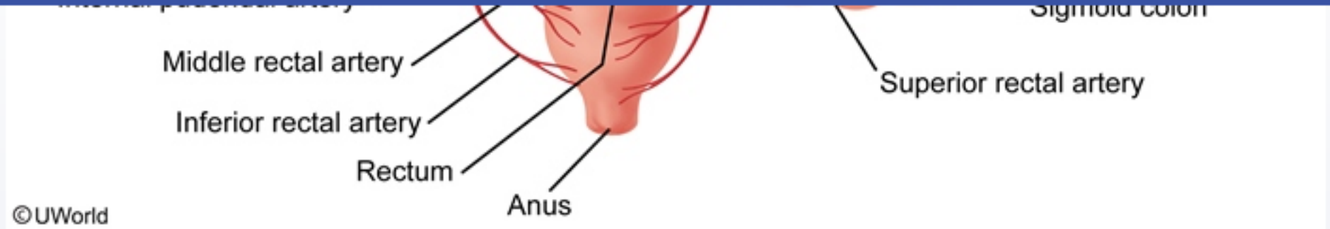

In this patient with recurrent gastrointestinal bleeding, arterial embolization (mechanical occlusion of the artery using coils or absorbable substances) is planned to stop the active bleeding originating from his sigmoid colon. The distal one-third of the transverse colon, descending colon, **sigmoid** colon, and rectum are all **hindgut** derivatives. Hindgut structures receive blood from the **inferior mesenteric artery** (IMA), a branch of the aorta. These structures are drained by the inferior mesenteric vein (IMV), which does not course with the IMA. The IMV drains blood from the hindgut into the splenic vein, which drains into the portal vein.

(Choice A) The celiac trunk supplies blood to most foregut structures from the lower esophagus to the second part of the duodenum. Foregut derivatives include the liver, pancreas, and gallbladder. The celiac trunk also supplies the spleen.

(Choice C) The superior mesenteric artery supplies blood to the midgut, which spans from the third part of the duodenum to the proximal two-thirds of the transverse colon.

(Choices D and E) The internal iliac artery supplies portions of the gut through branches such as the inferior rectal artery (a branch of the internal pudendal artery, which arises from the internal iliac artery) and the middle rectal artery (arises from the internal iliac). The internal pudendal artery supplies blood to the external genitalia. The superior rectal artery is a continuation of the IMA.

Educational objective:
The hindgut encompasses the distal one-third of the transverse colon, the descending colon, the sigmoid colon, and the rectum. These structures receive their main arterial blood supply from the inferior mesenteric artery.

Anatomy	Gastrointestinal & Nutrition	Gastrointestinal hemorrhage
Subject	System	Topic

Copyright © UWorld. All rights reserved.

4
5
6
7
8
9
10
11
12
13
14
15
16
17
18
19
20
21
22
23
24
25
26
27
28
29
30
31
32
33
34

A 52-year-old man is brought to the emergency department for hematemesis that began an hour earlier. He has regularly consumed large amounts of alcohol for the last 20 years and has been hospitalized numerous times due to ethanol intoxication. Temperature is 36.7 C (98 F), blood pressure is 90/60 mm Hg, pulse is 106/min, and respirations are 22/min. Physical examination shows jaundice and scleral icterus. Examination of the abdomen reveals a palpable spleen and moderate ascites. Endoscopy reveals bleeding esophageal varices. This patient's current condition most likely resulted from chronic shunting of blood through which of the following veins?

A. Left gastric
B. Middle colic
C. Paraumbilical
D. Right gastroepiploic
E. Splenic
F. Superficial epigastric

Submit

4
5
6
7
8
9
10
11
12
13
14
15
16
17
18
19
20
21
22
23
24
25
26
27
28
29
30
31
32
33
34

A 52-year-old man is brought to the emergency department for hematemesis that began an hour earlier. He has regularly consumed large amounts of alcohol for the last 20 years and has been hospitalized numerous times due to ethanol intoxication. Temperature is 36.7 C (98 F), blood pressure is 90/60 mm Hg, pulse is 106/min, and respirations are 22/min. Physical examination shows jaundice and scleral icterus. Examination of the abdomen reveals a palpable spleen and moderate ascites. Endoscopy reveals bleeding esophageal varices. This patient's current condition most likely resulted from chronic shunting of blood through which of the following veins?

- ✓ A. Left gastric (71%)
- B. Middle colic (0%)
- C. Paraumbilical (5%)
- D. Right gastroepiploic (5%)
- E. Splenic (10%)
- F. Superficial epigastric (6%)

Omitted
Correct answer
A

71%
Answered correctly

02 secs
Time Spent

06/09/2020
Last Updated

Explanation

Veins of stomach

Hepatic veins

4
5
6
7
8
9
10
11
12
13
14
15
16
17
18
19
20
21
22
23
24
25
26
27
28
29
30
31
32
33
34

Veins of stomach

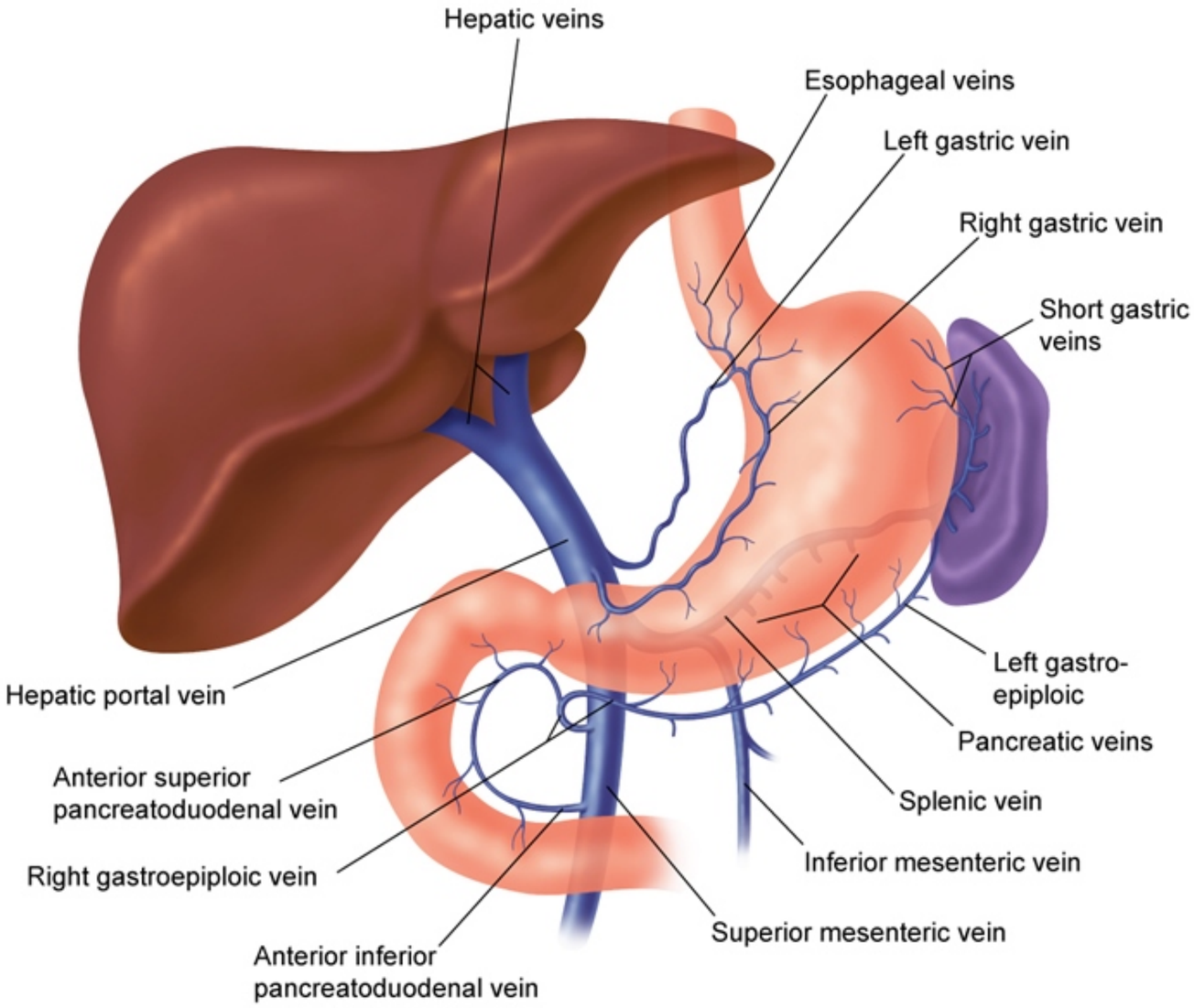

©UWorld

This patient has numerous cirrhotic stigmata including ascites, jaundice, and splenomegaly. An important cause of cirrhosis-related morbidity and mortality is the development of **variceal hemorrhaging** as a direct consequence of portal hypertension.

Cirrhosis (of any type) represents the end stage of progressive hepatic fibrosis. It is characterized by distortion of the hepatic architecture and formation of regenerative nodules. Cirrhosis is the most common cause of **portal hypertension**, which arises from increased resistance to portal flow at the hepatic sinusoids. Chronic portal hypertension leads to dilation of small, pre-existing vascular channels between the portal and systemic circulations. These dilated collateral vessels (portosystemic anastomoses) commonly form in the anterior abdomen (caput medusae), lower rectum (anorectal varices), and **inferior end of the esophagus** (esophageal varices).

Treatment sometimes includes inserting a transjugular intrahepatic portosystemic shunt (TIPS) between the portal vein and hepatic vein percutaneously, relieving portal hypertension by shunting blood to the systemic circulation.

(Choice B) The middle colic vein drains the transverse colon.

(Choices C and F) In cirrhosis, the paraumbilical veins can shunt blood from the portal system to superficial epigastric veins in the abdominal wall, causing caput medusae.

(Choice D) The right gastroepiploic vein drains venous blood from the inferior portions of the stomach. It runs along the greater curvature of the stomach.

(Choice E) The splenic vein drains blood from the spleen. It joins with the superior mesenteric vein to form the hepatic portal vein. Patients with portal hypertension can develop splenomegaly due to congestion of the splenic red pulp.

Educational objective:
In cirrhosis, portal hypertension arises from increased resistance to portal flow at the hepatic sinusoids. This causes increased pressure in the portosystemic collateral veins within the lower end of the esophagus, anterior abdomen, and lower rectum. Dilation of these collateral vessels is responsible for the esophageal varices, caput medusae, and anorectal varices commonly seen in patients with cirrhosis.

Anatomy	Gastrointestinal & Nutrition	Cirrhosis
Subject	System	Topic

mortality is the development of **variceal hemorrhaging** as a direct consequence of portal hypertension.

Cirrhosis (of any type) re d
formation of regenerative rtal
flow at the hepatic sinusoi
systemic circulations. The ,
lower rectum (anorectal va

Treatment sometimes incl
percutaneously, relieving

(Choice B) The middle c

(Choices C and F) In cir
wall, causing caput medus

(Choice D) The right gas he
stomach.

(Choice E) The splenic v with
portal hypertension can de

Educational objective:
In cirrhosis, portal hyperte
portosystemic collateral ve is
responsible for the esopha

Anatomy
Subject

Gastroint
System

Exhibit Display

Portacaval anastomoses		
Clinical manifestation	**Portal circulation**	**Systemic circulation**
Esophageal varices	Left gastric vein	Esophageal vein
Anorectal varices	Superior rectal vein	Middle & inferior rectal veins
Caput medusae	Paraumbilical veins	Superficial & inferior epigastric veins

Add To New Card | Existing Card

Copyright © UWorld. All rights reserved.

mortality is the development of **variceal hemorrhaging** as a direct consequence of portal hypertension

Exhibit Display

Zoom In Zoom Out Reset Add To New Card | Existing Card

4
5
6
7
8
9
10
11
12
13
14
15
16
17
18
19
20
21
22
23
24
25
26
27
28
29
30
31
32
33
34

A 32-year-old female presents to your office with severe nausea and recurrent bilious vomiting. Her symptoms initially began as postprandial epigastric pain and early satiety, but have progressed over the last two weeks. She works as an actress, and tells you that her symptoms only started when she "landed a role in a soap opera" and was inspired to lose 25 lbs. on a "crash diet". On physical exam, her abdomen is tender and slightly distended with high-pitched bowel sounds. Concerned about a small bowel obstruction, you admit the patient to the hospital. A laparotomy is performed, and it is observed that the angle between her superior mesenteric artery and her aorta is significantly decreased. Which of the following structures is most likely to be obstructed by the artery?

A. Ascending portion of the duodenum
B. Descending portion of the duodenum
C. Duodenal bulb
D. Duodenojejunal flexure
E. Gastric antrum
F. Transverse portion of the duodenum

Submit

A 32-year-old female presents to your office with severe nausea and recurrent bilious vomiting. Her symptoms initially began as postprandial epigastric pain and early satiety, but have progressed over the last two weeks. She works as an actress, and tells you that her symptoms only started when she "landed a role in a soap opera" and was inspired to lose 25 lbs. on a "crash diet". On physical exam, her abdomen is tender and slightly distended with high-pitched bowel sounds. Concerned about a small bowel obstruction, you admit the patient to the hospital. A laparotomy is performed, and it is observed that the angle between her superior mesenteric artery and her aorta is significantly decreased. Which of the following structures is most likely to be obstructed by the artery?

- A. Ascending portion of the duodenum (4%)
- B. Descending portion of the duodenum (9%)
- C. Duodenal bulb (5%)
- D. Duodenojejunal flexure (15%)
- E. Gastric antrum (2%)
- ✓ F. Transverse portion of the duodenum (62%)

Omitted
Correct answer
F

62%
Answered correctly

02 secs
Time Spent

06/23/2020
Last Updated

Explanation

The superior mesenteric artery (SMA) leaves the aorta at the level of L1 and supplies the intestine from the duodenum and pancreas to the left colic flexure. The transverse portion of the duodenum lies horizontally at the level of L3, between the aorta and superior mesenteric artery. Normally, the SMA and aorta form an approximately 45 degree angle. If this angle diminishes to less than 20 degrees, the transverse portion of

4
5
6
7
8
9
10
11
12
13
14
15
16
17
18
19
20
21
22
23
24
25
26
27
28
29
30
31
32
33
34

The superior mesenteric artery (SMA) leaves the aorta at the level of L1 and supplies the intestine from the duodenum and pancreas to the left colic flexure. The transverse portion of the duodenum lies horizontally at the level of L3, between the aorta and superior mesenteric artery. Normally, the SMA and aorta form an approximately 45 degree angle. If this angle diminishes to less than 20 degrees, the transverse portion of the duodenum can get entrapped between the SMA and aorta, leading to symptoms of partial small bowel obstruction. This condition is called superior mesenteric artery syndrome.

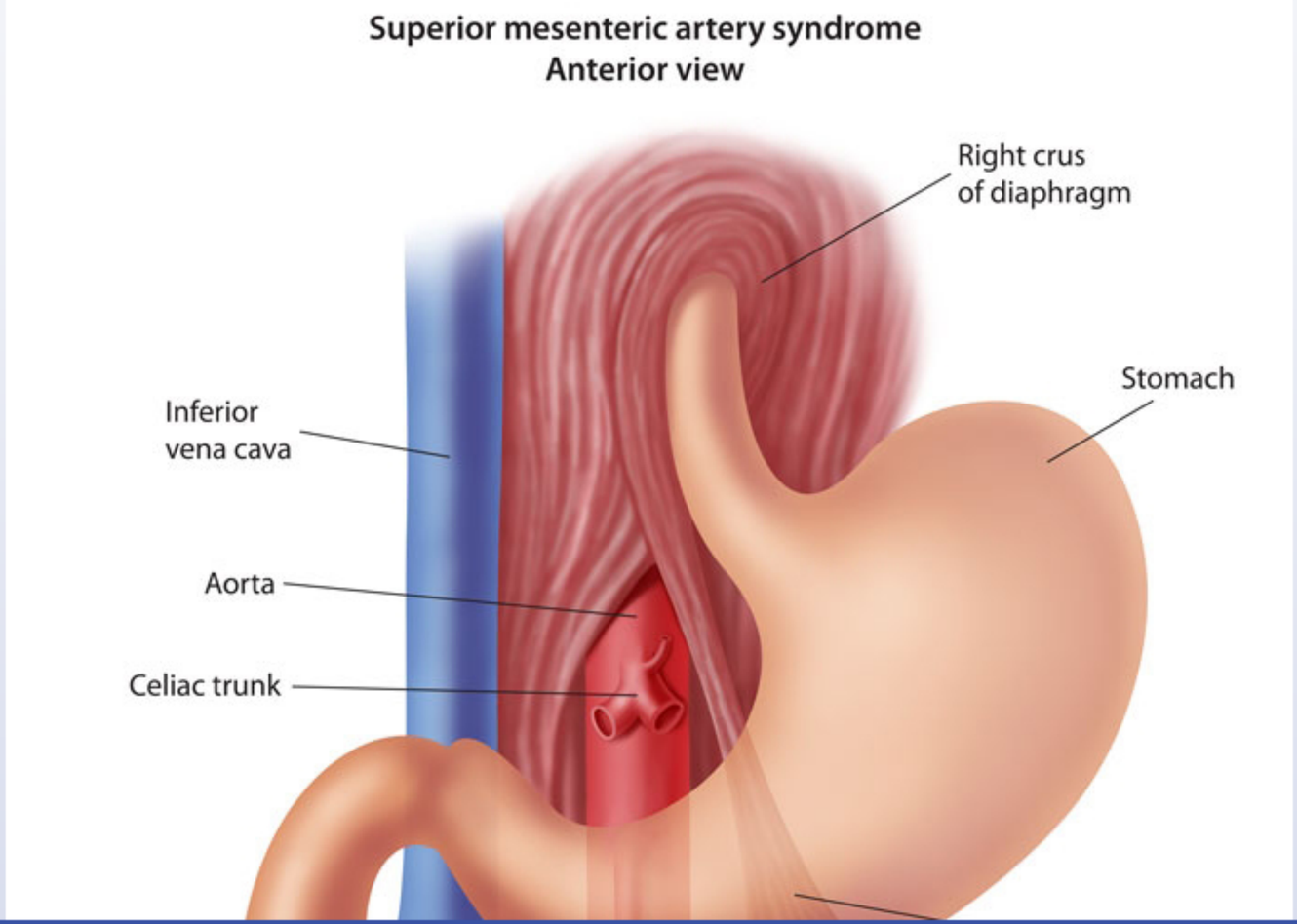

4
5
6
7
8
9
10
11
12
13
14
15
16
17
18
19
20
21
22
23
24
25
26
27
28
29
30
31
32
33
34

Exhibit Display

Superior mesenteric artery syndrome
Anterior view

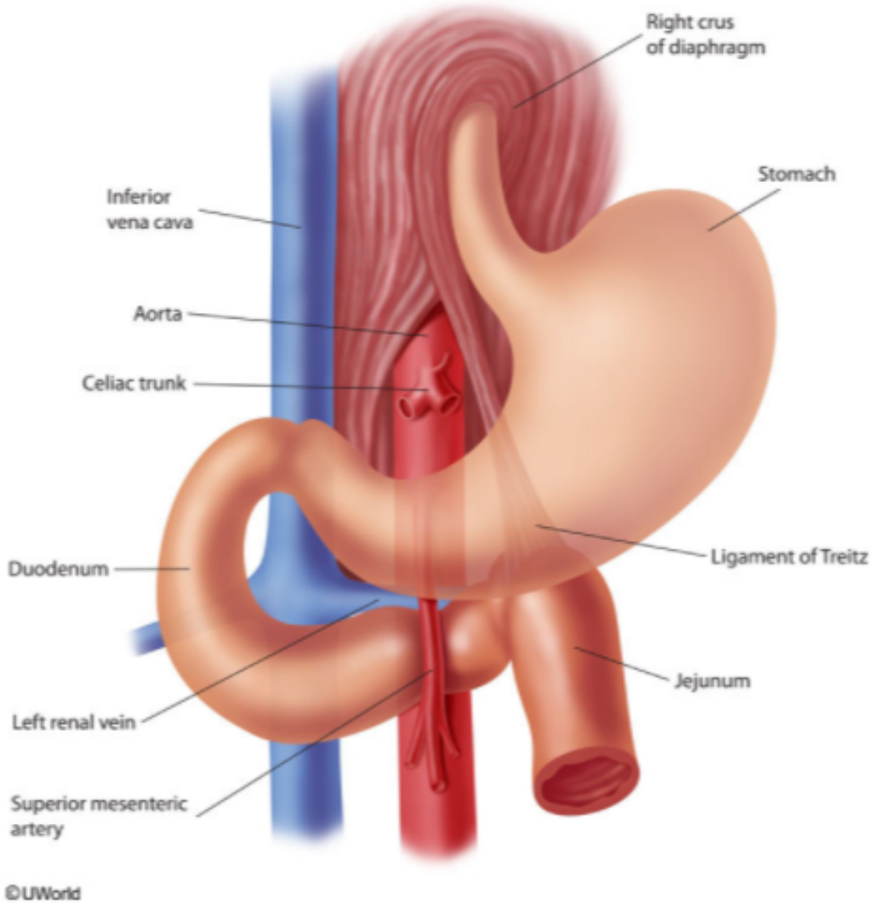

Zoom In | Zoom Out | Reset | Add To New Card | Existing Card

4
5
6
7
8
9
10
11
12
13
14
15
16
17
18
19
20
21
22
23
24
25
26
27
28
29
30
31
32
33
34

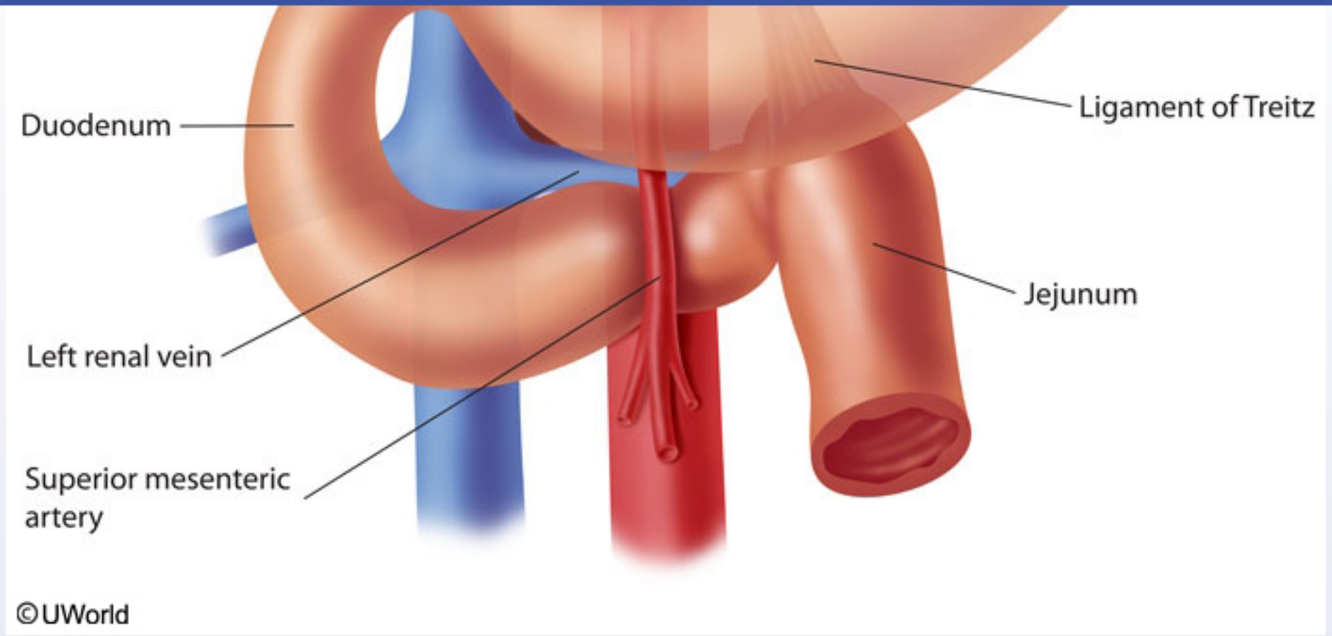

Narrowing of the aortomesenteric angle can occur with any condition that causes diminished mesenteric fat, including low body weight, recent weight loss, severe burns or other inducers of catabolism, and prolonged bed rest. It can also occur with pronounced lordosis or after surgical correction of scoliosis, as this procedure lengthens the spine resulting in decreased mobility of the SMA.

Educational Objective:

Superior mesenteric artery syndrome occurs when the transverse portion of the duodenum is entrapped between the SMA and aorta, causing symptoms of partial intestinal obstruction. This syndrome occurs when the aortomesenteric angle critically decreases, secondary to diminished mesenteric fat, pronounced lordosis, or surgical correction of scoliosis.

Anatomy	Gastrointestinal & Nutrition	Bowel obstruction
Subject	System	Topic

Copyright © UWorld. All rights reserved.

4
5
6
7
8
9
10
11
12
13
14
15
16
17
18
19
20
21
22
23
24
25
26
27
28
29
30
31
32
33
34

Exhibit Display

Superior mesenteric artery syndrome

Lateral view

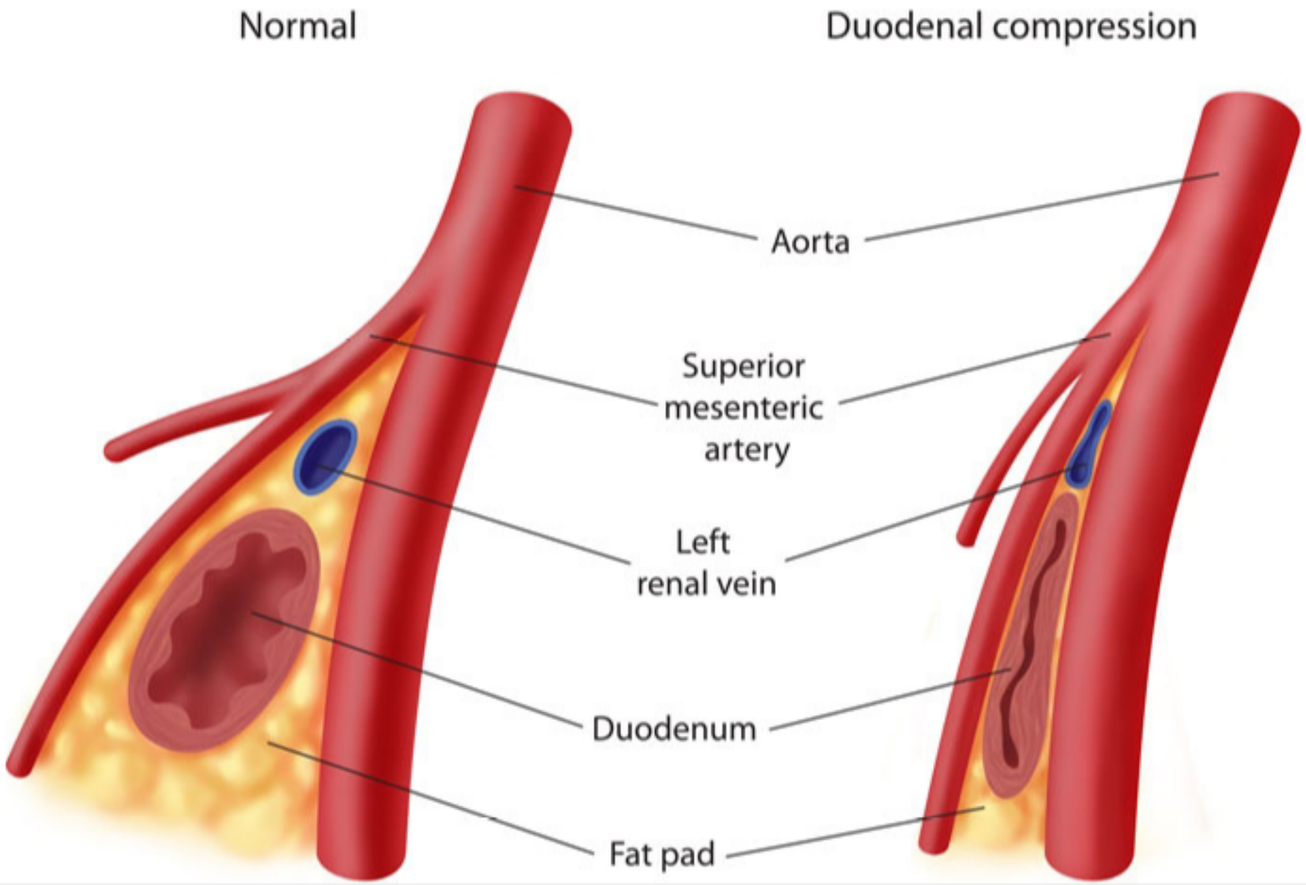

Zoom In | Zoom Out | Reset | Add To New Card | Existing Card

4
5
6
7
8
9
10
11
12
13
14
15
16
17
18
19
20
21
22
23
24
25
26
27
28
29
30
31
32
33
34

A 27-year-old woman, gravida 1 para 0, with gestational diabetes mellitus comes to the hospital at 38 weeks gestation for evaluation of abdominal pain. The patient is scheduled for an elective cesarean section at 39 weeks as a recent ultrasound revealed that the estimated fetal weight is 5200 g (11 lb 4 oz). Examination reveals that the patient is in active labor and the fetus is in breech presentation; an urgent cesarean section is performed. During the surgery, the rectus abdominus muscle is split vertically, but space appears to be limited. In anticipation of a large-for-gestational-age baby, a decision is made to transect the rectus abdominis muscle. If the rectus abdominis muscle is incised laterally, which of the following structures is at greatest risk of injury?

A. Deep circumflex iliac artery
B. Deep inguinal ring
C. Femoral sheath
D. Inferior epigastric artery
E. Lateral femoral cutaneous nerve
F. Superior epigastric artery

Submit

A 27-year-old woman, gravida 1 para 0, with gestational diabetes mellitus comes to the hospital at 38 weeks gestation for evaluation of abdominal pain. The patient is scheduled for an elective cesarean section at 39 weeks as a recent ultrasound revealed that the estimated fetal weight is 5200 g (11 lb 4 oz). Examination reveals that the patient is in active labor and the fetus is in breech presentation; an urgent cesarean section is performed. During the surgery, the rectus abdominus muscle is split vertically, but space appears to be limited. In anticipation of a large-for-gestational-age baby, a decision is made to transect the rectus abdominis muscle. If the rectus abdominis muscle is incised laterally, which of the following structures is at greatest risk of injury?

- A. Deep circumflex iliac artery (1%)
- B. Deep inguinal ring (4%)
- C. Femoral sheath (4%)
- ✓ D. Inferior epigastric artery (73%)
- E. Lateral femoral cutaneous nerve (4%)
- F. Superior epigastric artery (11%)

Omitted
Correct answer
D

73%
Answered correctly

02 secs
Time Spent

02/04/2020
Last Updated

Explanation

4
5
6
7
8
9
10
11
12
13
14
15
16
17
18
19
20
21
22
23
24
25
26
27
28
29
30
31
32
33
34

Vessels of the abdominal wall

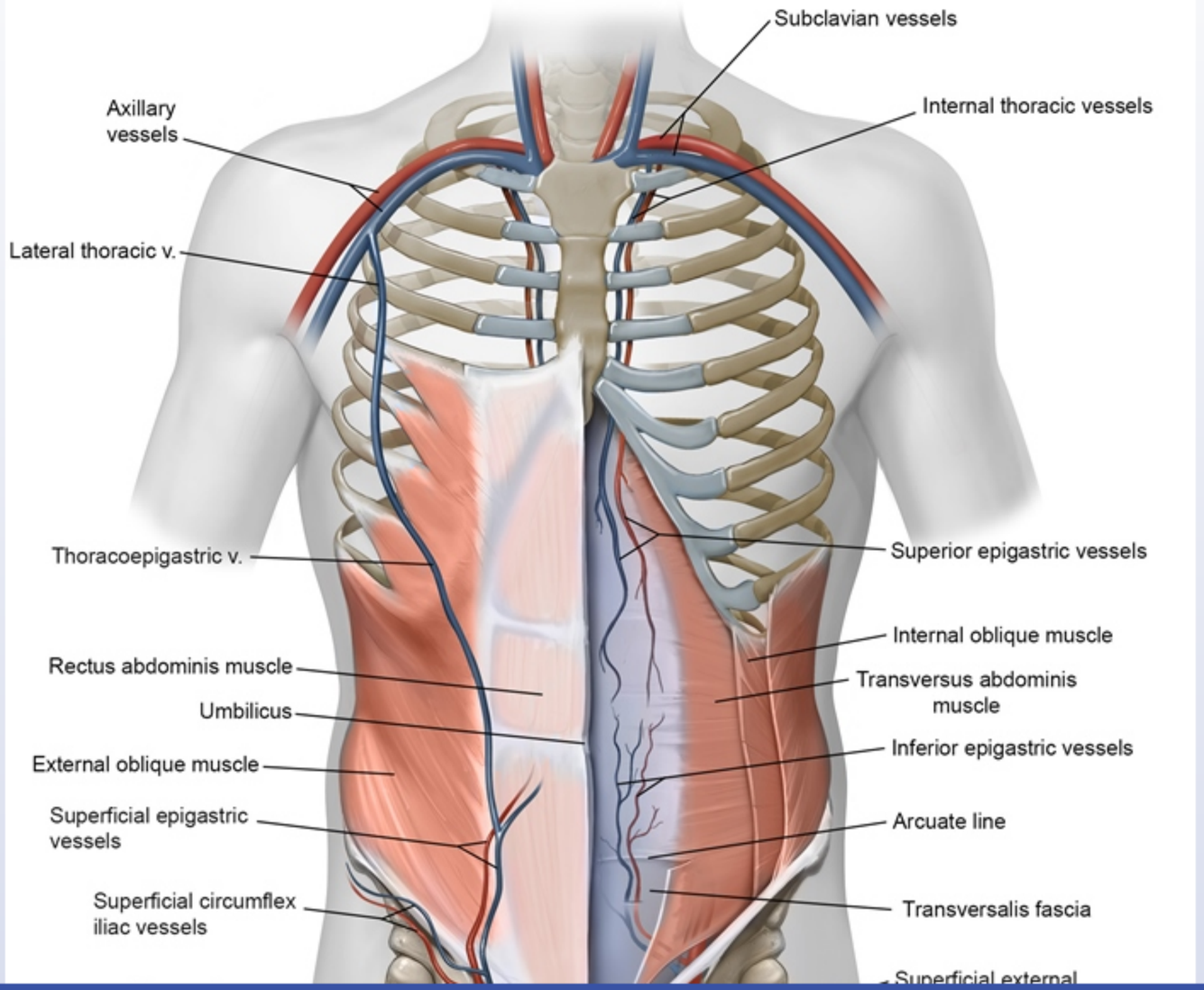

4
5
6
7
8
9
10
11
12
13
14
15
16
17
18
19
20
21
22
23
24
25
26
27
28
29
30
31
32
33
34

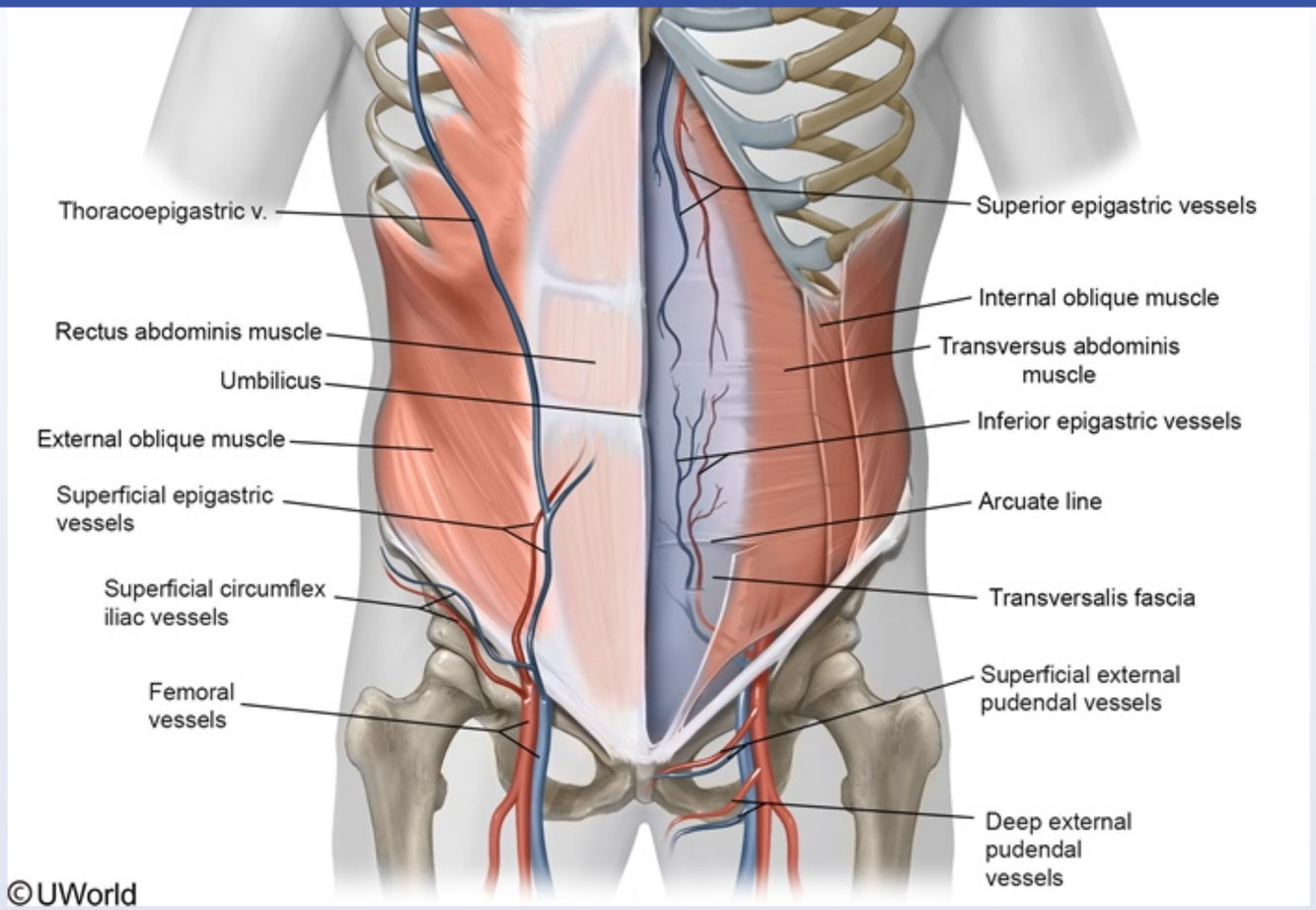

The rectus abdominis is a pair of vertically aligned muscles that connect the xiphoid process to the pubic symphysis. The **arcuate line** is a horizontal line located below the umbilicus that demarcates the lower limit of the posterior rectus sheath. Above the arcuate line, the rectus abdominis is surrounded by anterior and posterior sheaths; below, the muscle is covered only by the anterior sheath.

The superior **(Choice F)** and inferior epigastric arteries supply the superior and inferior portions of the rectus abdominis muscle, respectively. The epigastric artery ascends the posterior surface of the rectus abdominis muscle and enters the lateral aspect of this muscle at the arcuate line. Because there is **no supporting posterior sheath**, trauma to the **inferior epigastric artery** below the arcuate line can result in significant

4
5
6
7
8
9
10
11
12
13
14
15
16
17
18
19
20
21
22
23
24
25
26
27
28
29
30
31
32
33
34

The rectus abdominis is a pair of vertically aligned muscles that connect the xiphoid process to the pubic symphysis. The **arcuate line** is a horizontal line located below the umbilicus that demarcates the lower limit of the posterior rectus sheath. Above the arcuate line, the rectus abdominis is surrounded by anterior and posterior sheaths; below, the muscle is covered only by the anterior sheath.

The superior **(Choice F)** and inferior epigastric arteries supply the superior and inferior portions of the rectus abdominis muscle, respectively. The epigastric artery ascends the posterior surface of the rectus abdominis muscle and enters the lateral aspect of this muscle at the arcuate line. Because there is **no supporting posterior sheath**, trauma to the **inferior epigastric artery** below the arcuate line can result in significant hemorrhage.

Regardless of the direction of skin incision, a **cesarean delivery** typically involves midline vertical separation of the rectus abdominis muscle. **Horizontal transection** of the **rectus abdominis** muscle may be considered when additional space is necessary (eg, due to fetal weight or position). If the **rectus abdominis** is **transected horizontally**, the **inferior epigastric arteries** must be identified and ligated bilaterally to prevent bleeding complications (eg, hematoma).

(Choice A) The deep circumflex iliac artery supplies blood to the anterior iliac crest and arises from the lateral aspect of the external iliac artery. It is located significantly laterally and inferiorly to the rectus abdominis muscle.

(Choice B) The inguinal canal contains structures (eg, ilioinguinal nerve, round ligament [women], spermatic cord [men]) between the abdomen and external genitalia. Men are more susceptible to inguinal hernias compared to women due to their relatively larger deep inguinal ring.

(Choice C) The femoral sheath is located in the inguinofemoral region and contains the femoral artery, femoral vein, and femoral canal.

(Choice E) The lateral femoral cutaneous nerve travels under the inguinal ligament. It provides sensory innervation to the anterolateral thigh. Entrapment (meralgia paresthetica) most commonly occurs in obese or pregnant persons or in those who wear garments that are tight around the hip.

Educational objective:
Horizontal transection of the rectus abdominis muscle must be performed with great caution as the inferior epigastric arteries enter this muscle at the level of the arcuate line. The inferior epigastric arteries below the arcuate line are susceptible to injury (eg, hematoma) due to lack of a supporting posterior rectus sheath.

References

Regardless of the direction of skin incision, a **cesarean delivery** typically involves midline vertical separation of the rectus abdominis muscle. **Horizontal transection** of the **rectus abdominis** muscle may be considered when additional space is necessary (eg, due to fetal weight or position). If the **rectus abdominis** is **transected horizontally**, the **inferior epigastric arteries** must be identified and ligated bilaterally to prevent bleeding complications (eg, hematoma).

(Choice A) The deep circumflex iliac artery supplies blood to the anterior iliac crest and arises from the lateral aspect of the external iliac artery. It is located significantly laterally and inferiorly to the rectus abdominis muscle.

(Choice B) The inguinal canal contains structures (eg, ilioinguinal nerve, round ligament [women], spermatic cord [men]) between the abdomen and external genitalia. Men are more susceptible to inguinal hernias compared to women due to their relatively larger deep inguinal ring.

(Choice C) The femoral sheath is located in the inguinofemoral region and contains the femoral artery, femoral vein, and femoral canal.

(Choice E) The lateral femoral cutaneous nerve travels under the inguinal ligament. It provides sensory innervation to the anterolateral thigh. Entrapment (meralgia paresthetica) most commonly occurs in obese or pregnant persons or in those who wear garments that are tight around the hip.

Educational objective:
Horizontal transection of the rectus abdominis muscle must be performed with great caution as the inferior epigastric arteries enter this muscle at the level of the arcuate line. The inferior epigastric arteries below the arcuate line are susceptible to injury (eg, hematoma) due to lack of a supporting posterior rectus sheath.

References

- Reviewing the vascular supply of the anterior abdominal wall: redefining anatomy for increasingly refined surgery.
- Rectus sheath hematoma: a review of the literature.

Anatomy	Gastrointestinal & Nutrition	Anterior abdominal wall
Subject	System	Topic

Copyright © UWorld. All rights reserved.

4
5
6
7
8
9
10
11
12
13
14
15
16
17
18
19
20
21
22
23
24
25
26
27
28
29
30
31
32
33
34

Regardless of the direction of skin incision, a **cesarean delivery** typically involves midline vertical separation of the rectus abdominis muscle.

Exhibit Display

Indirect inguinal hernia

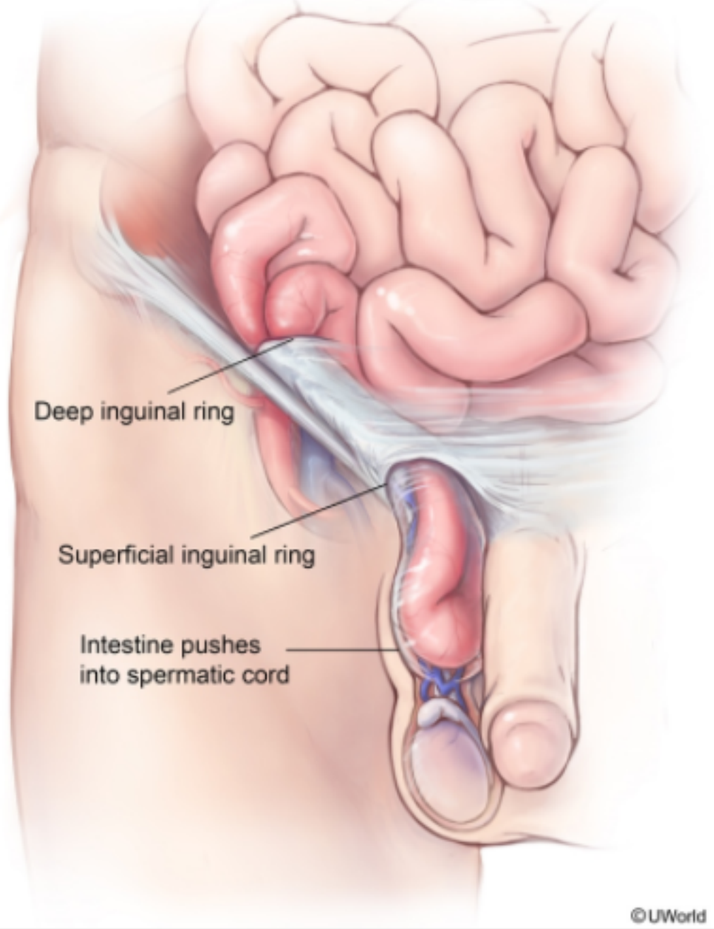

Zoom In | Zoom Out | Reset | Add To New Card | Existing Card

Regardless of the direction of skin incision, a **cesarean delivery** typically involves midline vertical separation of the rectus abdominis muscle.

Exhibit Display

Femoral triangle

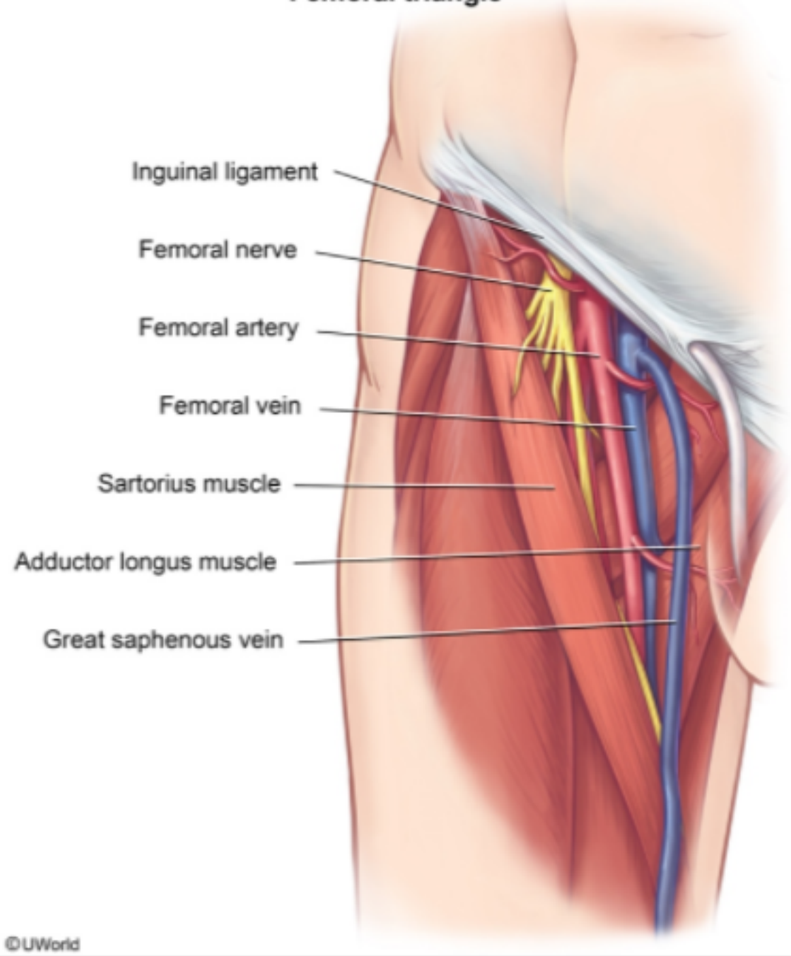

Zoom In | Zoom Out | Reset | Add To New Card | Existing Card

4
5
6
7
8
9
10
11
12
13
14
15
16
17
18
19
20
21
22
23
24
25
26
27
28
29
30
31
32
33
34

Regardless of the direction of skin incision, a **cesarean delivery** typically involves midline vertical separation of the rectus abdominis muscle.

Exhibit Display

Lateral femoral cutaneous nerve & meralgia paresthetica

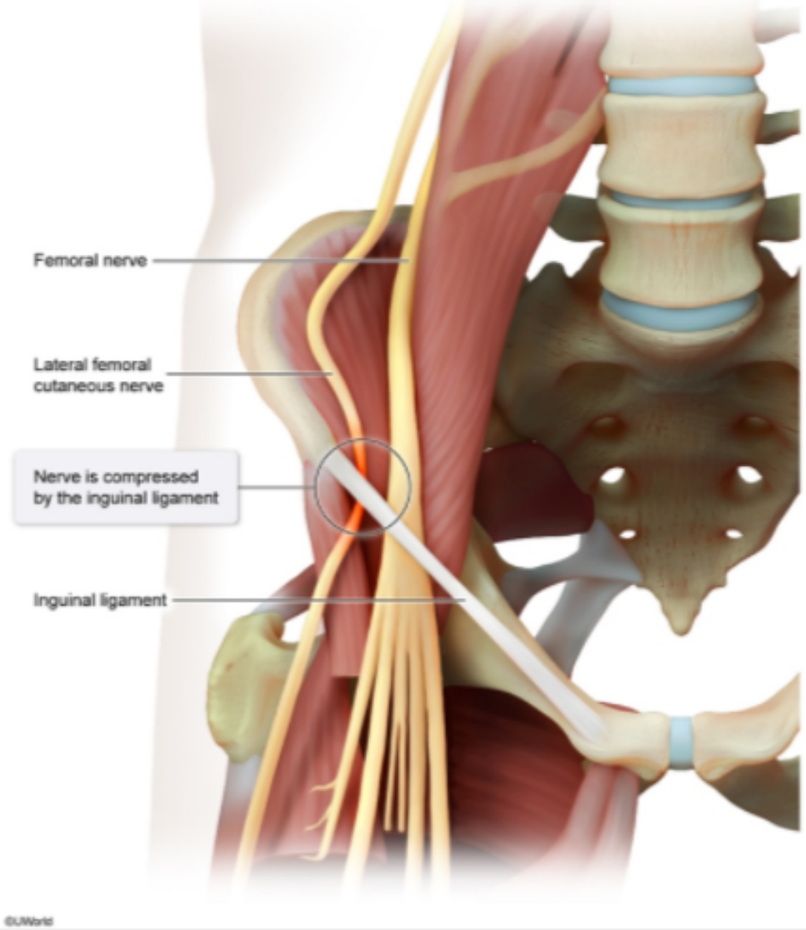

Zoom In | Zoom Out | Reset | Add To New Card | Existing Card

4
5
6
7
8
9
10
11
12
13
14
15
16
17
18
19
20
21
22
23
24
25
26
27
28
29
30
31
32
33
34

A 55-year-old man comes to the office due to swelling in his groin that he first noticed 2 weeks ago. Physical examination shows a bulge above the inguinal ligament that increases in size when the patient is asked to cough. He is referred to a surgeon and scheduled to undergo elective laparoscopic hernia repair. Which of the following landmarks will best aid the surgeon in distinguishing an indirect from a direct inguinal hernia?

A. Femoral vein
B. Inferior epigastric vessels
C. Pectineal ligament
D. Rectus muscle sheath
E. Spermatic cord
F. Transversalis fascia

Submit

4
5
6
7
8
9
10
11
12
13
14
15
16
17
18
19
20
21
22
23
24
25
26
27
28
29
30
31
32
33
34

A 55-year-old man comes to the office due to swelling in his groin that he first noticed 2 weeks ago. Physical examination shows a bulge above the inguinal ligament that increases in size when the patient is asked to cough. He is referred to a surgeon and scheduled to undergo elective laparoscopic hernia repair. Which of the following landmarks will best aid the surgeon in distinguishing an indirect from a direct inguinal hernia?

- A. Femoral vein (2%)
- ✓ B. Inferior epigastric vessels (84%)
- C. Pectineal ligament (1%)
- D. Rectus muscle sheath (1%)
- E. Spermatic cord (5%)
- F. Transversalis fascia (4%)

Omitted
Correct answer
B

84%
Answered correctly

02 secs
Time Spent

05/04/2020
Last Updated

Explanation

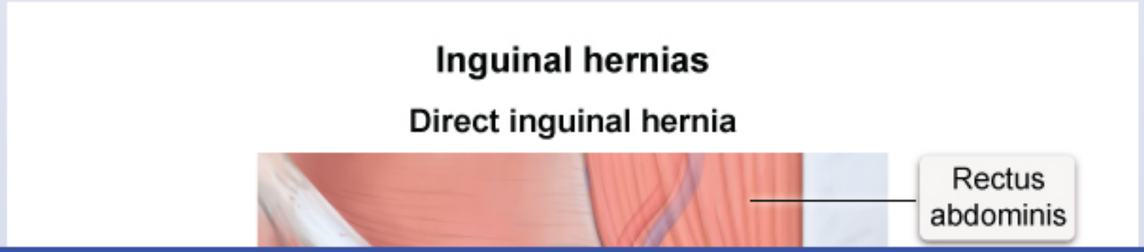

4
5
6
7
8
9
10
11
12
13
14
15
16
17
18
19
20
21
22
23
24
25
26
27
28
29
30
31
32
33
34

Inguinal hernias

Direct inguinal hernia

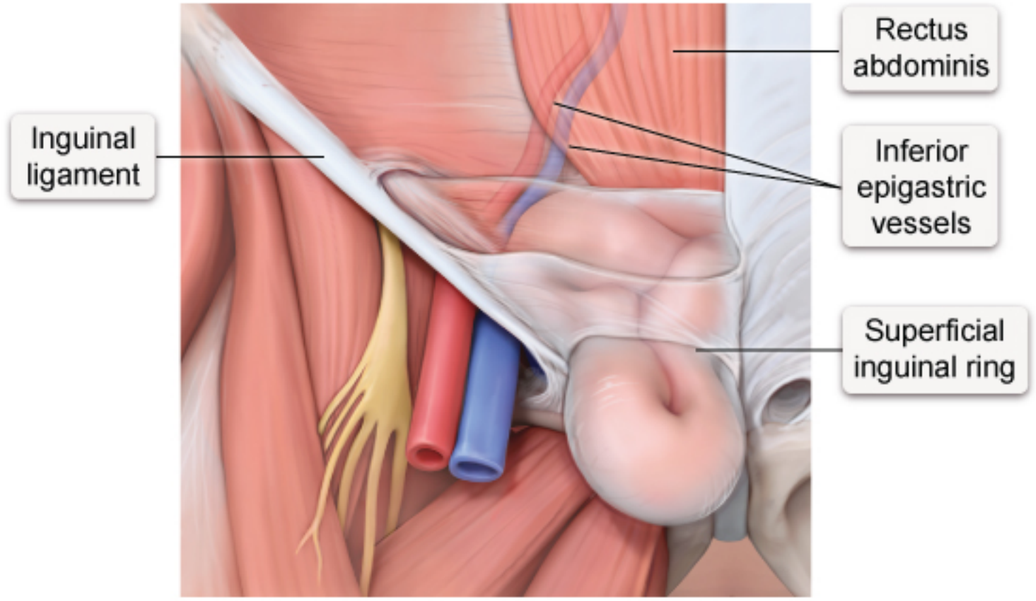

Indirect inguinal hernia

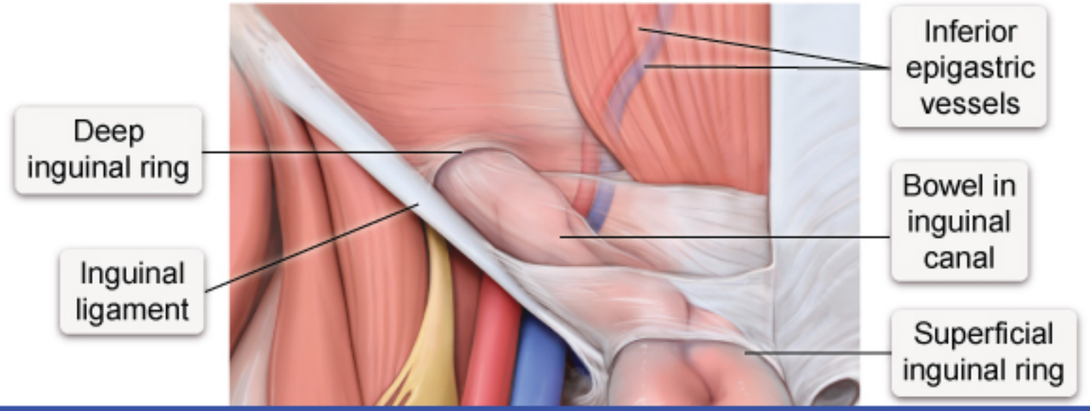

4
5
6
7
8
9
10
11
12
13
14
15
16
17
18
19
20
21
22
23
24
25
26
27
28
29
30
31
32
33
34

Indirect inguinal hernia

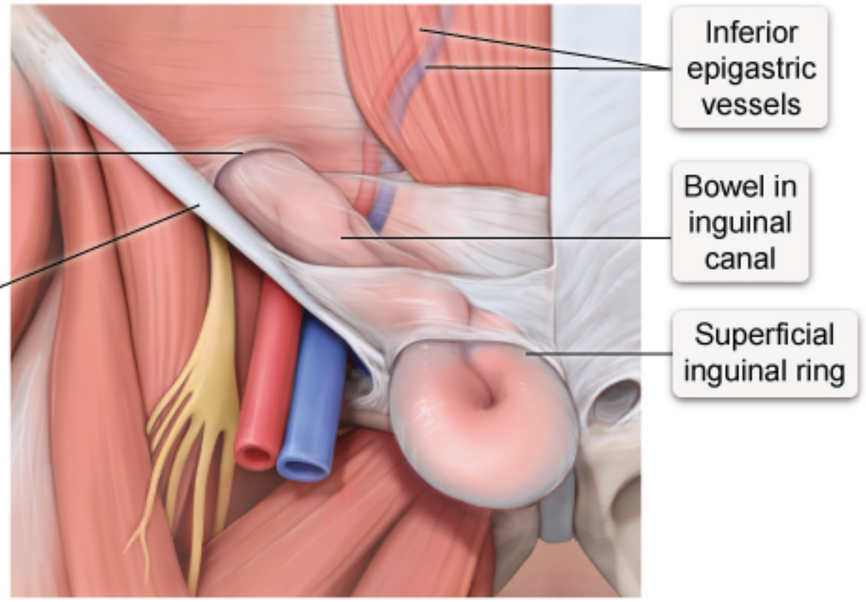

©UWorld

Inguinal hernias are located above the inguinal ligament and are much more common in men. The **inferior epigastric vessels** are clearly visible on the anterior abdominal wall during laparoscopic hernia repair and can be used as a landmark to **distinguish** between direct and indirect inguinal hernias.

Indirect inguinal hernias occur due to failure of the processus vaginalis to obliterate, allowing abdominal contents to protrude **lateral** to the inferior epigastric vessels through the deep (internal) inguinal ring. The abdominal contents follow the path of the inguinal canal and may exit through the superficial (external) inguinal ring into the scrotum.

Direct inguinal hernias occur due to weakness in the transversalis fascia that allows abdominal contents to protrude **medial** to the inferior epigastric vessels into the Hesselbach triangle. Compared to indirect inguinal hernias, direct hernias are less prone to incarceration due to their wide neck. It is also uncommon for them to descend into the scrotum as there is no direct path through the abdominal fascia.

(Choice A) The femoral vein runs directly lateral to femoral hernias, which protrude below the inguinal ligament into the femoral canal.

4
5
6
7
8
9
10
11
12
13
14
15
16
17
18
19
20
21
22
23
24
25
26
27
28
29
30
31
32
33
34

epigastric vessels through the deep (internal) inguinal ring. The abdominal contents follow the path of the inguinal canal and may exit through the superficial (external) inguinal ring into the scrotum.

Direct inguinal hernias occur due to weakness in the transversalis fascia that allows abdominal contents to protrude **medial** to the inferior epigastric vessels into the Hesselbach triangle. Compared to indirect inguinal hernias, direct hernias are less prone to incarceration due to their wide neck. It is also uncommon for them to descend into the scrotum as there is no direct path through the abdominal fascia.

(Choice A) The femoral vein runs directly lateral to femoral hernias, which protrude below the inguinal ligament into the femoral canal.

(Choice C) The pectineal ligament (inguinal ligament of Cooper) forms the posterior border of the femoral ring and would be located behind a femoral hernia that protrudes through the ring.

(Choice D) The rectus abdominis muscle sheath forms the most medial aspect of the Hesselbach triangle, which is the site of protrusion for direct inguinal hernias. Because both direct and indirect inguinal hernias lie lateral to the rectus abdominis muscle sheath, it would not be useful for distinguishing these two types of hernia.

(Choice E) Indirect inguinal hernias follow the path of the spermatic cord (or uterine round ligament) as it courses through the deep (internal) inguinal ring.

(Choice F) The transversalis fascia is the site of weakness in a direct inguinal hernia and lies posterior to indirect inguinal hernias as they extend through the inguinal canal.

Educational objective:
The inferior epigastric vessels are useful as a landmark during laparoscopic hernia repair to classify the type of inguinal hernia. Indirect inguinal hernias protrude through the deep inguinal ring into the inguinal canal lateral to the inferior epigastric vessels. In contrast, direct inguinal hernias protrude through Hesselbach's triangle medial to the inferior epigastric vessels.

Anatomy	Gastrointestinal & Nutrition	Groin hernias
Subject	System	Topic

Copyright © UWorld. All rights reserved.

epigastric vessels through the deep (internal) inguinal ring. The abdominal contents follow the path of the inguinal canal and may exit through the

Exhibit Display

Groin hernias

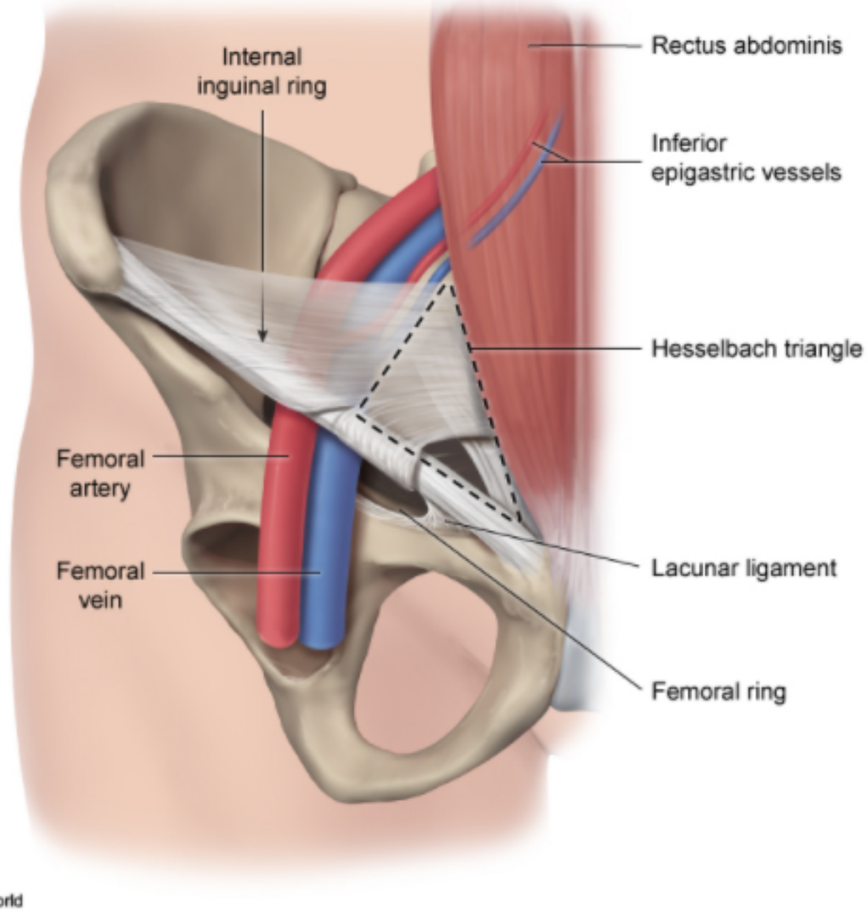

Zoom In | Zoom Out | Reset | Add To New Card | Existing Card

epigastric vessels through the deep (internal) inguinal ring. The abdominal contents follow the path of the inguinal canal and may exit through the

Exhibit Display

Femoral hernia

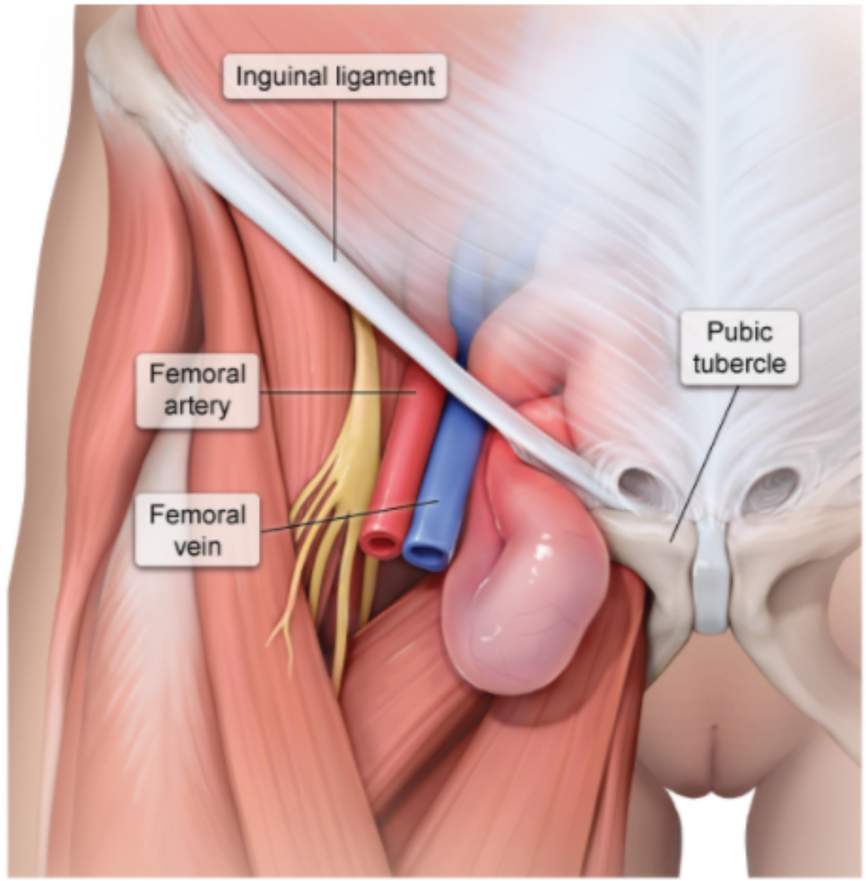

©UWorld

Zoom In | Zoom Out | Reset | Add To New Card | Existing Card

4
5
6
7
8
9
10
11
12
13
14
15
16
17
18
19
20
21
22
23
24
25
26
27
28
29
30
31
32
33
34

A 39-year-old woman is brought to the emergency department after an end-to-end motor vehicle collision. She was a restrained passenger and denies hitting her head or losing consciousness but has had abdominal pain and nausea since the accident. The patient's blood pressure is 115/55 mm Hg and pulse is 96/min and regular. On examination, she has ecchymosis over the area of the seat belt and abdominal tenderness. CT scan of the abdomen reveals a retroperitoneal hematoma. This patient most likely experienced which of the following injuries?

A. Contusion of the body of the pancreas
B. Laceration of the inferior border of the spleen
C. Laceration of the right hepatic lobe
D. Rupture of the suprarenal aorta
E. Tear at the lesser curvature of the stomach
F. Tear at the proximal transverse colon

Submit

A 39-year-old woman is brought to the emergency department after an end-to-end motor vehicle collision. She was a restrained passenger and denies hitting her head or losing consciousness but has had abdominal pain and nausea since the accident. The patient's blood pressure is 115/55 mm Hg and pulse is 96/min and regular. On examination, she has ecchymosis over the area of the seat belt and abdominal tenderness. CT scan of the abdomen reveals a retroperitoneal hematoma. This patient most likely experienced which of the following injuries?

- ✓ A. Contusion of the body of the pancreas (43%)
- B. Laceration of the inferior border of the spleen (38%)
- C. Laceration of the right hepatic lobe (2%)
- D. Rupture of the suprarenal aorta (12%)
- E. Tear at the lesser curvature of the stomach (0%)
- F. Tear at the proximal transverse colon (2%)

Omitted
Correct answer
A

43%
Answered correctly

02 secs
Time Spent

03/30/2020
Last Updated

Explanation

Retroperitoneal abdominal organs
• Suprarenal (adrenal) glands • Aorta & inferior vena cava • Duodenum* (except 1st part)

Retroperitoneal abdominal organs
• **S**uprarenal (adrenal) glands • **A**orta & inferior vena cava • **D**uodenum* (except 1st part) • **P**ancreas* (head & body) • **U**reters • **C**olon* (ascending & descending) • **K**idneys • **E**sophagus • **R**ectum (mid-distal) Mnemonic: **SAD PUCKER**

*Secondarily retroperitoneal (developed intraperitoneal & migrated retroperitoneal).

Retroperitoneal hematomas are commonly associated with abdominal and pelvic trauma. Pancreatic injury is a frequent cause of retroperitoneal hematomas. It can occur following severe blunt or penetrating abdominal trauma, such as from malpositioned seat belts or steering wheels during motor vehicle collisions. Pancreatic injury with retroperitoneal hematoma may initially cause only mild symptoms or be asymptomatic, but it can lead to life-threatening blood loss. Therefore, an abdominal CT scan is frequently performed in patients with blunt abdominal trauma to rule out retroperitoneal hematoma.

(Choices B, C, E, and F) The spleen, liver, stomach, and transverse colon are intraperitoneal organs. Lacerations or rupture of these organs can occur in blunt abdominal trauma, but these injuries would lead to hemoperitoneum (free blood in the peritoneal space), not retroperitoneal hematoma.

(Choice D) Although the abdominal aorta is a retroperitoneal structure, rupture would most likely result in massive and rapid blood loss leading to hemorrhagic shock.

Educational objective:
Retroperitoneal hematoma is a common complication of abdominal and pelvic trauma. The pancreas is a retroperitoneal organ, and pancreatic

- Kidneys
- Esophagus
- Rectum (mid-distal)

Mnemonic: **SAD PUCKER**

*Secondarily retroperitoneal (developed intraperitoneal & migrated retroperitoneal).

Retroperitoneal hematomas are commonly associated with abdominal and pelvic trauma. Pancreatic injury is a frequent cause of retroperitoneal hematomas. It can occur following severe blunt or penetrating abdominal trauma, such as from malpositioned seat belts or steering wheels during motor vehicle collisions. Pancreatic injury with retroperitoneal hematoma may initially cause only mild symptoms or be asymptomatic, but it can lead to life-threatening blood loss. Therefore, an abdominal CT scan is frequently performed in patients with blunt abdominal trauma to rule out retroperitoneal hematoma.

(Choices B, C, E, and F) The spleen, liver, stomach, and transverse colon are intraperitoneal organs. Lacerations or rupture of these organs can occur in blunt abdominal trauma, but these injuries would lead to hemoperitoneum (free blood in the peritoneal space), not retroperitoneal hematoma.

(Choice D) Although the abdominal aorta is a retroperitoneal structure, rupture would most likely result in massive and rapid blood loss leading to hemorrhagic shock.

Educational objective:
Retroperitoneal hematoma is a common complication of abdominal and pelvic trauma. The pancreas is a retroperitoneal organ, and pancreatic injury is frequently a source of retroperitoneal bleeding.

References

- The diagnosis and treatment of traumatic retroperitoneal hematoma.

Anatomy	Gastrointestinal & Nutrition	Retroperitoneal hematoma
Subject	System	Topic

Copyright © UWorld. All rights reserved.

4
5
6
7
8
9
10
11
12
13
14
15
16
17
18
19
20
21
22
23
24
25
26
27
28
29
30
31
32
33
34

A 74-year-old man comes to the office due to chronic constipation. Bowel movements occur once every 3 days and are hard and pellet-like. The patient frequently strains when he tries to defecate and never feels completely evacuated. The constipation is occasionally so severe that he uses his fingers to remove stool from the anorectal vault. Medical history is significant for Parkinson disease, for which he takes carbidopa-levodopa. Vital signs are unremarkable. A resting tremor is present on physical examination. The abdomen is distended but nontender to palpation. This patient's condition is most likely due to inadequate relaxation of which of the following muscles during defecation?

A. Bulbospongiosus
B. Obturator
C. Piriformis
D. Puborectalis
E. Rectus abdominis

Submit

A 74-year-old man comes to the office due to chronic constipation. Bowel movements occur once every 3 days and are hard and pellet-like. The patient frequently strains when he tries to defecate and never feels completely evacuated. The constipation is occasionally so severe that he uses his fingers to remove stool from the anorectal vault. Medical history is significant for Parkinson disease, for which he takes carbidopa-levodopa. Vital signs are unremarkable. A resting tremor is present on physical examination. The abdomen is distended but nontender to palpation. This patient's condition is most likely due to inadequate relaxation of which of the following muscles during defecation?

- A. Bulbospongiosus (6%)
- B. Obturator (2%)
- C. Piriformis (5%)
- ✓ D. Puborectalis (80%)
- E. Rectus abdominis (5%)

Omitted
Correct answer
D

80%
Answered correctly

02 secs
Time Spent

03/18/2020
Last Updated

Explanation

Stool continence is largely maintained by tonic contraction of the internal and external anal sphincter and the puborectalis muscle, which forms a muscular sling around the rectum and squeezes it into a narrow angle to prevent stool leakage. **Defecation** requires the coordinated relaxation of these muscles, which occurs as follows:

1. Distension of the rectal vault activates mechanoreceptors that cause involuntary relaxation of the internal anal sphincter (rectosphincteric reflex) and an urge to defecate.

Stool continence is largely maintained by tonic contraction of the internal and external anal sphincter and the puborectalis muscle, which forms a muscular sling around the rectum and squeezes it into a narrow angle to prevent stool leakage. **Defecation** requires the coordinated relaxation of these muscles, which occurs as follows:

1. Distension of the rectal vault activates mechanoreceptors that cause involuntary relaxation of the internal anal sphincter (rectosphincteric reflex) and an urge to defecate.
2. The puborectalis muscle and external anal sphincter are under voluntary control; when defecation is desired, the muscles relax and the rectum contracts, expelling feces.
3. The abdominal muscles contract to increase the pressure gradient of the rectum and aid in the rapid expulsion of feces.

If the internal or external anal sphincter or, more commonly, the **puborectalis muscle fails to relax**, stool remains in the rectal vault despite attempts to initiate bowel movements **(dyssynergia)**, resulting in chronic **constipation**. Patients often strain for a long time only to pass small amounts of stool, and manual disimpaction may be required. Dyssynergic defecation is usually considered a functional disorder and occurs more commonly in the elderly; however, it can occur with certain neurologic disorders (eg, Parkinson disease, multiple sclerosis) or trauma.

(Choice A) The bulbospongiosus is a superficial perineal muscle that enables penile erection and ejaculation in men and facilitates both vaginal canal closure and orgasm in women. Its dysfunction would lead to sexual impairment but not defecatory dysfunction.

(Choices B and C) The obturator internus and externus and the piriformis contribute to lateral hip rotation. Dysfunction in these muscles would result in motor impairment and gait abnormalities, not defecatory dysfunction.

(Choice E) The rectus abdominis consists of 2 large, paired muscles that run vertically along the anterior abdominal wall. Contraction of abdominal muscles increases the pressure gradient of the rectum and aids in the rapid expulsion of feces; failure of this muscle to relax would not result in constipation.

Educational objective:
Dyssynergic defecation occurs when the puborectalis muscle or the internal or external anal sphincter fails to relax during defecation, leading to chronic constipation. Dyssynergic defecation is usually considered a functional disorder and occurs more commonly in the elderly but may also occur with certain neurologic disorders (eg, Parkinson disease, multiple sclerosis) or trauma.

References

3. The abdominal muscles contract to increase the pressure gradient of the rectum and aid in the rapid expulsion of feces.

If the internal or external anal sphincter or, more commonly, the **puborectalis muscle fails to relax**, stool remains in the rectal vault despite attempts to initiate bowel movements **(dyssynergia)**, resulting in chronic **constipation**. Patients often strain for a long time only to pass small amounts of stool, and manual disimpaction may be required. Dyssynergic defecation is usually considered a functional disorder and occurs more commonly in the elderly; however, it can occur with certain neurologic disorders (eg, Parkinson disease, multiple sclerosis) or trauma.

(Choice A) The bulbospongiosus is a superficial perineal muscle that enables penile erection and ejaculation in men and facilitates both vaginal canal closure and orgasm in women. Its dysfunction would lead to sexual impairment but not defecatory dysfunction.

(Choices B and C) The obturator internus and externus and the piriformis contribute to lateral hip rotation. Dysfunction in these muscles would result in motor impairment and gait abnormalities, not defecatory dysfunction.

(Choice E) The rectus abdominis consists of 2 large, paired muscles that run vertically along the anterior abdominal wall. Contraction of abdominal muscles increases the pressure gradient of the rectum and aids in the rapid expulsion of feces; failure of this muscle to relax would not result in constipation.

Educational objective:
Dyssynergic defecation occurs when the puborectalis muscle or the internal or external anal sphincter fails to relax during defecation, leading to chronic constipation. Dyssynergic defecation is usually considered a functional disorder and occurs more commonly in the elderly but may also occur with certain neurologic disorders (eg, Parkinson disease, multiple sclerosis) or trauma.

References

- Constipation in neurological diseases.
- Management of constipation in patients with Parkinson's disease.

Anatomy	Gastrointestinal & Nutrition	Constipation
Subject	System	Topic

Copyright © UWorld. All rights reserved.

4
5
6
7
8
9
10
11
12
13
14
15
16
17
18
19
20
21
22
23
24
25
26
27
28
29
30
31
32
33
34

A 65-year-old woman comes to the emergency department due to nausea, vomiting, and abdominal pain that began about 6 hours ago. She has also had vague pelvic pain over the last few months but says her pain has never been this severe. Temperature is 38.4 C (101 F), blood pressure is 141/90 mm Hg, pulse is 92/min, and respirations are 18/min. Physical examination shows a moderately distended abdomen. There is a tender bulge below the inguinal ligament, lateral to the pubic tubercle. The overlying skin is erythematous. Which of the following structures is most likely immediately lateral to the bulge?

A. Femoral vein
B. Inferior epigastric vessels
C. Pectineal ligament
D. Rectus muscle sheath
E. Round ligament
F. Transversalis fascia

Submit

4
5
6
7
8
9
10
11
12
13
14
15
16
17
18
19
20
21
22
23
24
25
26
27
28
29
30
31
32
33
34

A 65-year-old woman comes to the emergency department due to nausea, vomiting, and abdominal pain that began about 6 hours ago. She has also had vague pelvic pain over the last few months but says her pain has never been this severe. Temperature is 38.4 C (101 F), blood pressure is 141/90 mm Hg, pulse is 92/min, and respirations are 18/min. Physical examination shows a moderately distended abdomen. There is a tender bulge below the inguinal ligament, lateral to the pubic tubercle. The overlying skin is erythematous. Which of the following structures is most likely immediately lateral to the bulge?

- ✓ A. Femoral vein (71%)
- B. Inferior epigastric vessels (17%)
- C. Pectineal ligament (2%)
- D. Rectus muscle sheath (2%)
- E. Round ligament (3%)
- F. Transversalis fascia (2%)

Omitted
Correct answer
A

71%
Answered correctly

01 sec
Time Spent

05/02/2020
Last Updated

Explanation

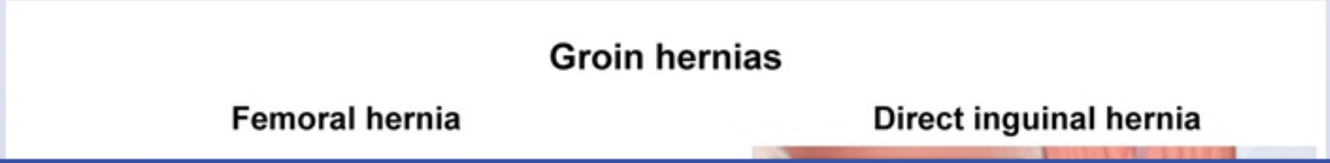

4
5
6
7
8
9
10
11
12
13
14
15
16
17
18
19
20
21
22
23
24
25
26
27
28
29
30
31
32
33
34

Groin hernias

Femoral hernia

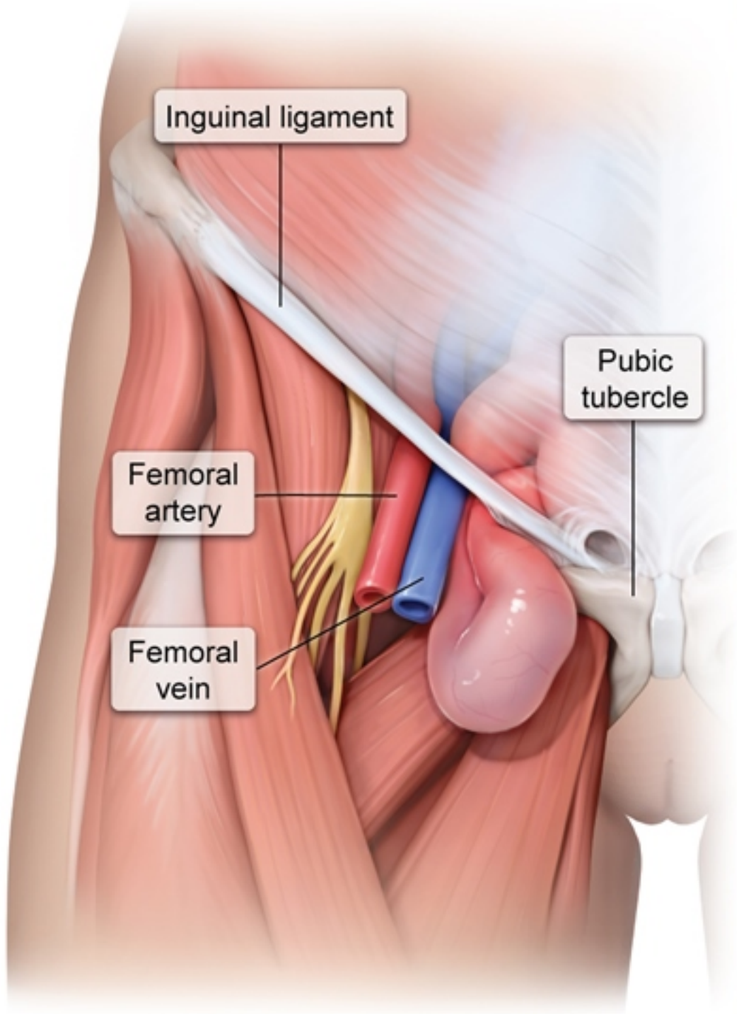

Direct inguinal hernia

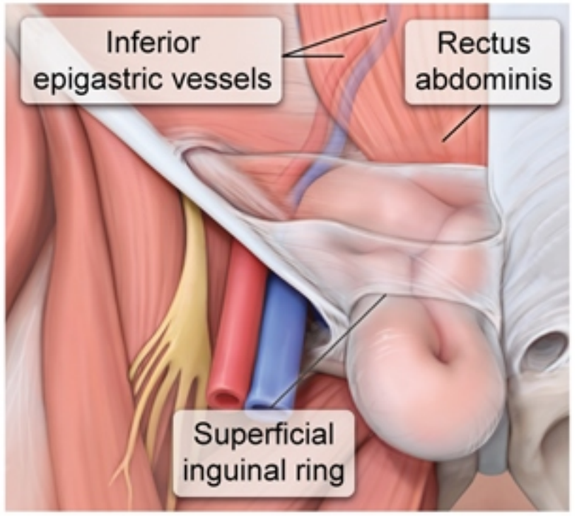

Indirect inguinal hernia

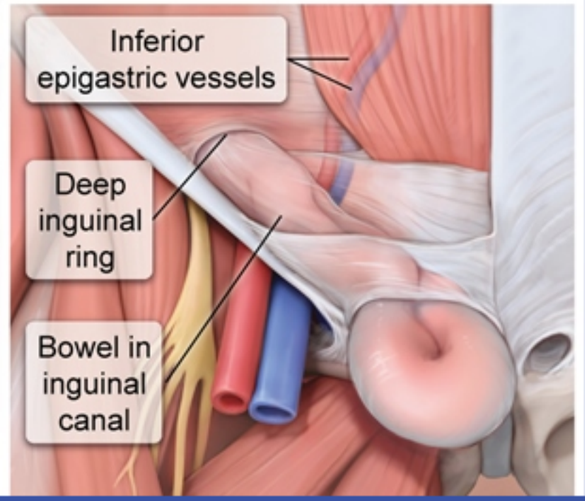

4
5
6
7
8
9
10
11
12
13
14
15
16
17
18
19
20
21
22
23
24
25
26
27
28
29
30
31
32
33
34

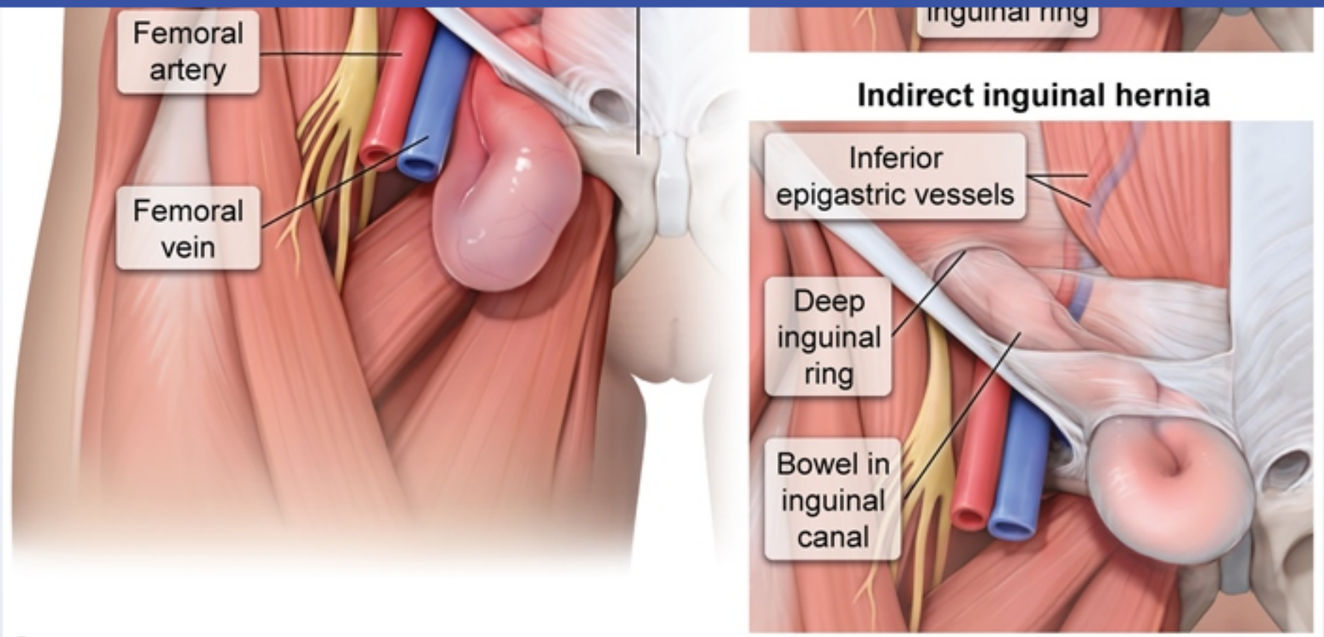

©UWorld

This patient has a **femoral hernia**, which characteristically presents with upper thigh, groin, or pelvic discomfort and a tender bulge **below the inguinal ligament**, lateral to the pubic tubercle and lacunar ligament. Femoral hernias are more common in women and tend to occur on the right side. Advanced age is the most important risk factor. Over time, the femoral ring becomes lax and can widen, allowing bowel to protrude into the femoral canal, the medial most compartment within the femoral sheath. The femoral vessels travel within other compartments of the femoral sheath, with the **femoral vein** running **immediately lateral** to the hernia.

Because the femoral canal is small, femoral hernias are prone to **incarceration**. Incarcerated hernias cannot be reduced; if a segment of bowel is present in the hernia sac, incarceration can cause bowel obstruction (eg, nausea, vomiting, abdominal pain and distension). Incarceration can also cause impaired blood flow to contents trapped in the hernia sac, resulting in **strangulation** (ischemia and necrosis) with potential systemic complications such as sepsis.

(Choice B) Direct inguinal hernias protrude through weakened transversalis facia, medial to the inferior epigastric vessels, and emerge into the Hesselbach triangle. Indirect inguinal hernias protrude lateral to the inferior epigastric vessels before running through the deep (internal) inguinal ring and into the inguinal canal.

4
5
6
7
8
9
10
11
12
13
14
15
16
17
18
19
20
21
22
23
24
25
26
27
28
29
30
31
32
33
34

©UWorld

This patient has a **femoral hernia**, which characteristically presents with upper thigh, groin, or pelvic discomfort and a tender bulge **below the inguinal ligament**, lateral to the pubic tubercle and lacunar ligament. Femoral hernias are more common in women and tend to occur on the right side. Advanced age is the most important risk factor. Over time, the femoral ring becomes lax and can widen, allowing bowel to protrude into the femoral canal, the medial most compartment within the femoral sheath. The femoral vessels travel within other compartments of the femoral sheath, with the **femoral vein** running **immediately lateral** to the hernia.

Because the femoral canal is small, femoral hernias are prone to **incarceration**. Incarcerated hernias cannot be reduced; if a segment of bowel is present in the hernia sac, incarceration can cause bowel obstruction (eg, nausea, vomiting, abdominal pain and distension). Incarceration can also cause impaired blood flow to contents trapped in the hernia sac, resulting in **strangulation** (ischemia and necrosis) with potential systemic complications such as sepsis.

(Choice B) Direct inguinal hernias protrude through weakened transversalis facia, medial to the inferior epigastric vessels, and emerge into the Hesselbach triangle. Indirect inguinal hernias protrude lateral to the inferior epigastric vessels before running through the deep (internal) inguinal ring and into the inguinal canal.

(Choice C) The pectineal ligament (inguinal ligament of Cooper) is a thickened part of the pectineal fascia. It overlies the pectineal ridge of the pubic bone and is located posterior to the femoral canal.

(Choice D) The rectus muscle sheath forms the medial border of the Hesselbach triangle. Direct inguinal hernias are located just lateral to the rectus abdominis muscle sheath.

(Choice E) The round ligament in women is homologous to the spermatic cord in men. It leaves the pelvis through the deep inguinal ring and passes through the inguinal canal.

(Choice F) The transversalis fascia is found between the transversalis muscle and the extraperitoneal fat. It forms the posterior wall of the inguinal canal. The deep (internal) inguinal ring is an opening in the transversalis fascia and is the site of protrusion of indirect inguinal hernias.

Educational objective:
Femoral hernias can present with groin discomfort and a tender bulge on the upper thigh inferior to the inguinal ligament, lateral to the pubic tubercle and lacunar ligament. The structure that lies immediately lateral to the hernia within the femoral sheath is the femoral vein. Incarceration

side. Advanced age is the most important risk factor. Over time, the femoral ring becomes lax and can widen, allowing bowel to protrude into the

Exhibit Display

Groin hernias

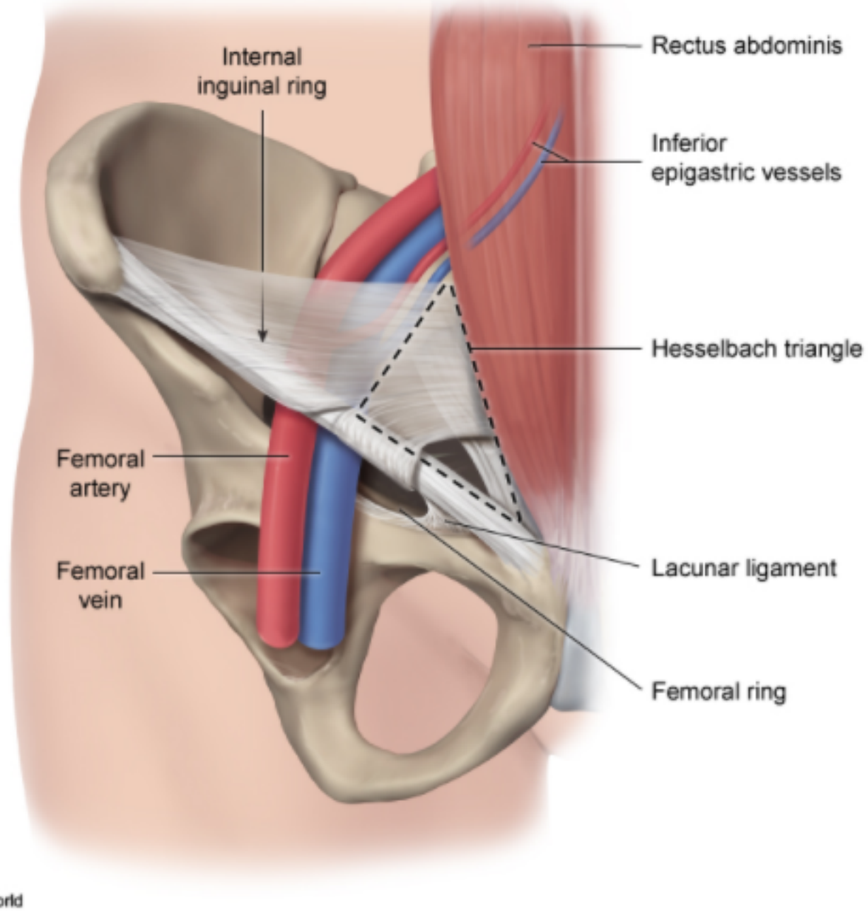

Zoom In | Zoom Out | Reset | Add To New Card | Existing Card

4
5
6
7
8
9
10
11
12
13
14
15
16
17
18
19
20
21
22
23
24
25
26
27
28
29
30
31
32
33
34

A 68-year-old woman comes to the emergency department due to a 2-day history of crampy abdominal pain and vomiting. The patient has had no hematemesis, melena, or hematochezia. She has a history of hypertension, type 2 diabetes mellitus, and coronary artery disease. Several months ago, the patient had an episode of acute calculous cholecystitis that was managed non-operatively. Physical examination shows a distended, tympanic abdomen with high-pitched bowel sounds. Abdominal x-ray reveals air in the gallbladder and biliary tree. This patient's gallstone has most likely lodged in which of the following sites?

A. Common bile duct
B. Cystic duct
C. Duodenum
D. Ileum
E. Jejunum

Submit

4
5
6
7
8
9
10
11
12
13
14
15
16
17
18
19
20
21
22
23
24
25
26
27
28
29
30
31
32
33
34

A 68-year-old woman comes to the emergency department due to a 2-day history of crampy abdominal pain and vomiting. The patient has had no hematemesis, melena, or hematochezia. She has a history of hypertension, type 2 diabetes mellitus, and coronary artery disease. Several months ago, the patient had an episode of acute calculous cholecystitis that was managed non-operatively. Physical examination shows a distended, tympanic abdomen with high-pitched bowel sounds. Abdominal x-ray reveals air in the gallbladder and biliary tree. This patient's gallstone has most likely lodged in which of the following sites?

A. Common bile duct

B. Cystic duct

C. Duodenum

D. Ileum

E. Jejunum

Submit

4
5
6
7
8
9
10
11
12
13
14
15
16
17
18
19
20
21
22
23
24
25
26
27
28
29
30
31
32
33
34

A 68-year-old woman comes to the emergency department due to a 2-day history of crampy abdominal pain and vomiting. The patient has had no hematemesis, melena, or hematochezia. She has a history of hypertension, type 2 diabetes mellitus, and coronary artery disease. Several months ago, the patient had an episode of acute calculous cholecystitis that was managed non-operatively. Physical examination shows a distended, tympanic abdomen with high-pitched bowel sounds. Abdominal x-ray reveals air in the gallbladder and biliary tree. This patient's gallstone has most likely lodged in which of the following sites?

- A. Common bile duct (24%)
- B. Cystic duct (11%)
- C. Duodenum (17%)
- ✓ D. Ileum (44%)
- E. Jejunum (1%)

Omitted
Correct answer
D

44%
Answered correctly

13 secs
Time Spent

05/03/2020
Last Updated

Explanation

4
5
6
7
8
9
10
11
12
13
14
15
16
17
18
19
20
21
22
23
24
25
26
27
28
29
30
31
32
33
34

Gallstone ileus

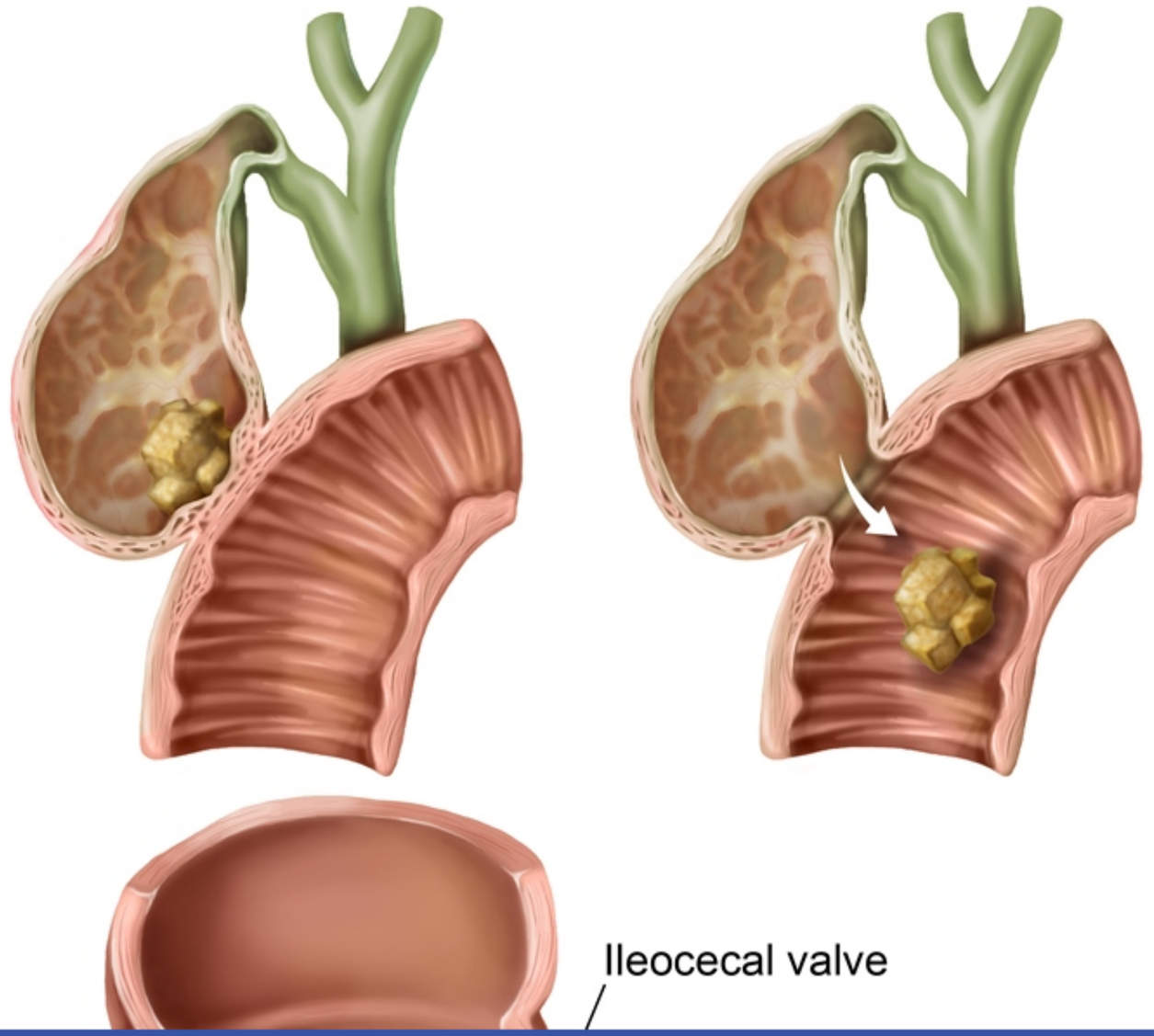

4
5
6
7
8
9
10
11
12
13
14
15
16
17
18
19
20
21
22
23
24
25
26
27
28
29
30
31
32
33
34

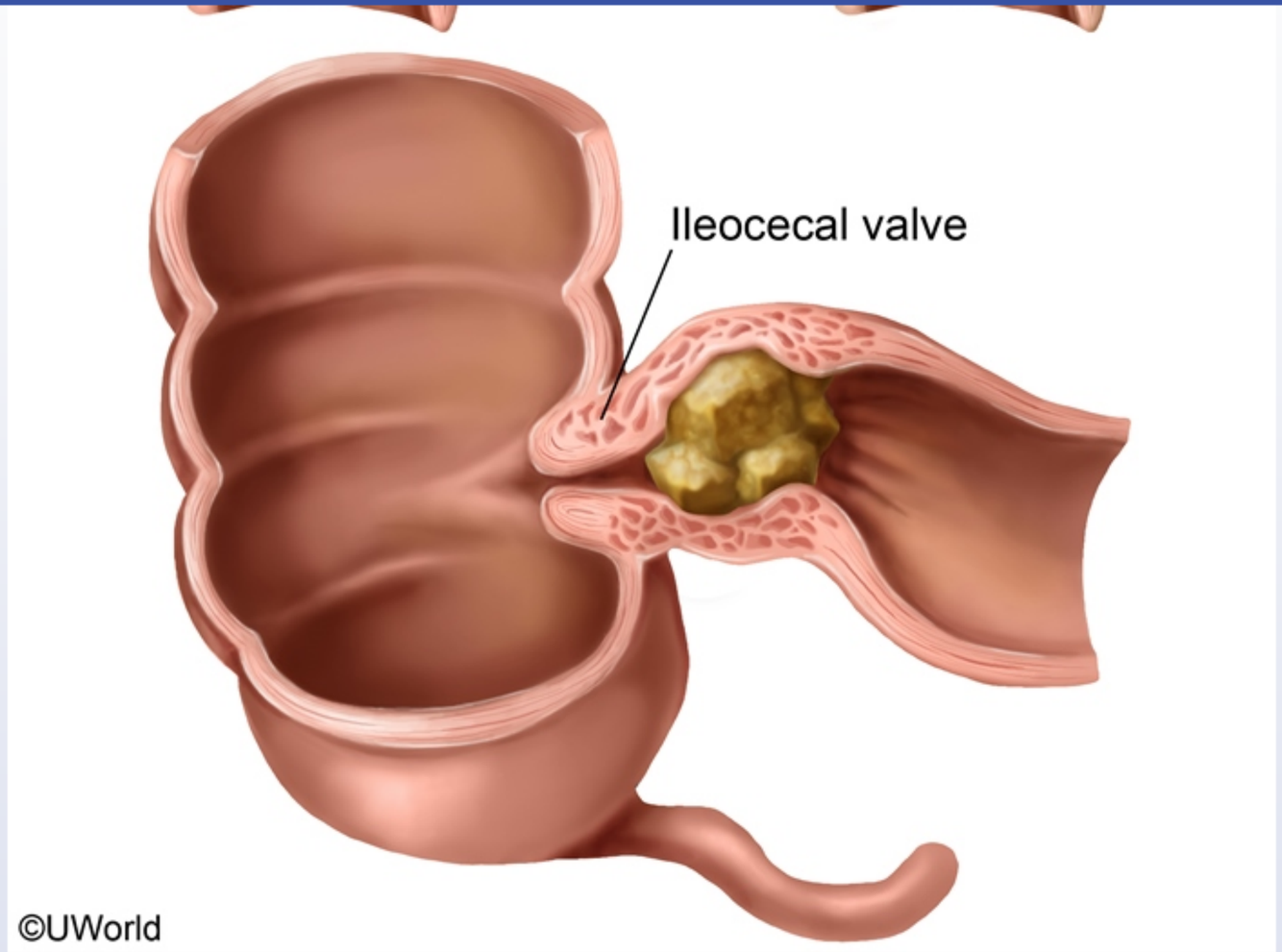

This patient likely has **gallstone ileus**, an uncommon complication of longstanding cholelithiasis that usually occurs in elderly women. A large (typically ≥2.5 cm) gallstone causes formation of a **cholecystoenteric fistula** between the gallbladder and adjoining gut (most often the duodenum) due to pressure necrosis and erosion of these tissues.

Fistula formation allows passage of the gallstone into the small bowel, where it travels freely until it becomes trapped in the **ileum**, the narrowest

This patient likely has **gallstone ileus**, an uncommon complication of longstanding cholelithiasis that usually occurs in elderly women. A large (typically ≥2.5 cm) gallstone causes formation of a **cholecystoenteric fistula** between the gallbladder and adjoining gut (most often the duodenum) due to pressure necrosis and erosion of these tissues.

Fistula formation allows passage of the gallstone into the small bowel, where it travels freely until it becomes trapped in the **ileum**, the narrowest portion of the intestine. Patients consequently develop symptoms/signs of **small bowel obstruction**, including abdominal pain/distension, nausea/vomiting, high-pitched (tinkling) bowel sounds, and tenderness to palpation. Abdominal x-ray may reveal dilated loops of bowel with air-fluid levels due to intestinal obstruction. Communication between the intestine and gallbladder may also allow gas to enter the biliary tree (**pneumobilia**).

(Choice A) Obstruction of the common bile duct by a gallstone (choledocholithiasis) can lead to pancreatitis and/or cholangitis. Cholangitis typically presents with fever, right upper quadrant abdominal pain, and jaundice (Charcot triad). Pneumobilia and features of small bowel obstruction are not characteristic.

(Choice B) Obstruction of the cystic duct by a gallstone may result in biliary colic or acute cholecystitis. Acute cholecystitis usually presents with fever, abdominal pain, leukocytosis, and an inspiratory pause during right upper quadrant palpation (Murphy sign). Pneumobilia and features of small bowel obstruction are not characteristic.

(Choices C and E) The caliber of the duodenum and jejunum is typically sufficient to allow passage of larger gallstones that cause gallstone ileus.

Educational objective:
Gallstone ileus results from passage of a large gallstone through a cholecystenteric fistula into the small bowel, where it ultimately causes obstruction at the ileum. Patients typically present with symptoms/signs of small bowel obstruction, and an abdominal x-ray may reveal gas within the gallbladder and biliary tree.

References

- Gallstone ileus: case report and literature review.

Anatomy	Gastrointestinal & Nutrition	Cholecystitis
Subject	System	Topic

4
5
6
7
8
9
10
11
12
13
14
15
16
17
18
19
20
21
22
23
24
25
26
27
28
29
30
31
32
33
34

A 62-year-old man comes to the emergency department due to acute-onset constipation. His last bowel movement was 4 days ago; before that time, his stools were always regular. Review of systems is positive for dry cough, increasing low back pain, a 9-kg (20-lb) weight loss in the past month, and increasing difficulty with urination. He has smoked 2 packs of cigarettes daily for 30 years. Vital signs are within normal limits. Point tenderness is elicited with palpation over the lower spine. Bilateral lower extremity weakness is present, and sensation is impaired in the perineal region. Chest x-ray reveals a right lung mass. Dysfunction of which of the following nerves best explains this patient's constipation?

A. Greater splanchnic nerve

B. Ilioinguinal nerve

C. Lesser splanchnic nerve

D. Pelvic splanchnic nerves

E. Vagus nerve

Submit

A 62-year-old man comes to the emergency department due to acute-onset constipation. His last bowel movement was 4 days ago; before that time, his stools were always regular. Review of systems is positive for dry cough, increasing low back pain, a 9-kg (20-lb) weight loss in the past month, and increasing difficulty with urination. He has smoked 2 packs of cigarettes daily for 30 years. Vital signs are within normal limits. Point tenderness is elicited with palpation over the lower spine. Bilateral lower extremity weakness is present, and sensation is impaired in the perineal region. Chest x-ray reveals a right lung mass. Dysfunction of which of the following nerves best explains this patient's constipation?

- A. Greater splanchnic nerve (4%)
- B. Ilioinguinal nerve (9%)
- C. Lesser splanchnic nerve (6%)
- ✓ D. Pelvic splanchnic nerves (63%)
- E. Vagus nerve (15%)

Omitted
Correct answer
D

63%
Answered correctly

02 secs
Time Spent

03/23/2020
Last Updated

Explanation

This patient with a lung mass has progressive low back pain, bilateral lower extremity weakness, bowel/bladder dysfunction, and impaired perineal sensation; this presentation is highly concerning for **cauda equina syndrome**. The cauda equina is formed from lumbosacral nerve roots which can be compressed by **epidural metastasis** (most commonly from lung cancer), trauma, or disc herniation. The symptoms of cauda equina syndrome result from disruption of nerve roots to the sciatic nerve (eg, lower extremity weakness, radicular low back pain), pudendal nerve (eg, saddle anesthesia), and/or pelvic splanchnic nerves.

4 5 6 7 8 9 10 11 12 13 14 15 16 17 18 19 20 21 22 23 24 25 26 27 28 29 30 31 32 33 34

This patient with a lung mass has progressive low back pain, bilateral lower extremity weakness, bowel/bladder dysfunction, and impaired perineal sensation; this presentation is highly concerning for **cauda equina syndrome**. The cauda equina is formed from lumbosacral nerve roots which can be compressed by **epidural metastasis** (most commonly from lung cancer), trauma, or disc herniation. The symptoms of cauda equina syndrome result from disruption of nerve roots to the sciatic nerve (eg, lower extremity weakness, radicular low back pain), pudendal nerve (eg, saddle anesthesia), and/or pelvic splanchnic nerves.

The **pelvic splanchnic nerves** (S2-S4) provide **parasympathetic** innervation to the hindgut, bladder, and urinary sphincters that promotes peristalsis, bladder emptying, and pelvic floor relaxation during defecation. **Constipation** and **difficulty urinating** are prominent symptoms in cauda equina syndrome due to loss of parasympathetic input to the bowel and bladder.

(Choices A and C) The greater splanchnic nerve (T5-T10) and lesser splanchnic nerve (T9-T12) provide sympathetic innervation to the foregut and midgut, respectively. In contrast to the parasympathetic nervous system, the sympathetic nervous system inhibits the gastrointestinal tract by slowing peristalsis. Disruption of these nerves can lead to increased gut motility, not constipation.

(Choice B) The ilioinguinal nerve (L1) provides sensation to the superior medial thigh and part of the genitals, as well as motor innervation to the transverse abdominus and oblique abdominal musculature. Although it can be affected in cauda equina syndrome, it does not provide sympathetic or parasympathetic innervation to the gastrointestinal system.

(Choice E) The vagus nerve (CN X) originates in the medulla and provides parasympathetic innervation to the proximal gastrointestinal tract, ending at the level of the splenic flexure. Impairment of the vagus nerve is more likely to cause delayed gastric emptying and would not be caused by a lumbosacral spinal cord lesion.

Educational objective:
The pelvic splanchnic nerves (S2-S4) provide parasympathetic innervation to the bowel and bladder, and their impairment in cauda equina syndrome can cause constipation and difficulty urinating. Other signs of cauda equina syndrome include radicular low back pain and leg weakness (sciatic nerve) as well as saddle anesthesia (pudendal, ilioinguinal nerves).

References

- Constipation in neurological diseases.

Anatomy Gastrointestinal & Nutrition Constipation

This patient with a lung mass has progressive low back pain, bilateral lower extremity weakness, bowel/bladder dysfunction, and impaired perineal

Exhibit Display

Relation of spinal nerve roots to vertebrae

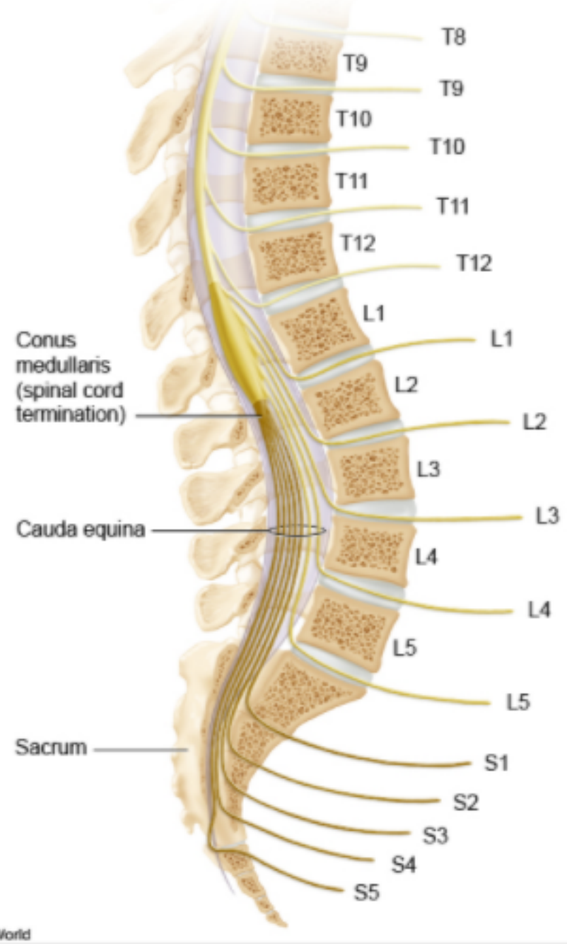

Zoom In | Zoom Out | Reset | Add To New Card | Existing Card

Anatomy | Gastrointestinal & Nutrition | Constipation

4
5
6
7
8
9
10
11
12
13
14
15
16
17
18
19
20
21
22
23
24
25
26
27
28
29
30
31
32
33
34

A 52-year-old man comes to the office for a painless mass in his right groin. He noticed the mass several weeks ago, and it has slowly enlarged. The patient has a history of HIV, for which he takes antiretroviral therapy. He has not had any new sexual partners recently. Temperature is 37.1 C (98.8 F). On examination, several enlarged, hard lymph nodes are palpated in the right inguinal area inferior to the inguinal ligament. An excisional biopsy is performed, and histopathology shows malignant cells. The malignant cells found in this patient most likely originated from which of the following sites?

A. Dome of the bladder

B. Lateral lobe of the prostate

C. Orifice of the anal canal

D. Upper pole of the testes

E. Upper third of the rectum

Submit

4
5
6
7
8
9
10
11
12
13
14
15
16
17
18
19
20
21
22
23
24
25
26
27
28
29
30
31
32
33
34

A 52-year-old man comes to the office for a painless mass in his right groin. He noticed the mass several weeks ago, and it has slowly enlarged. The patient has a history of HIV, for which he takes antiretroviral therapy. He has not had any new sexual partners recently. Temperature is 37.1 C (98.8 F). On examination, several enlarged, hard lymph nodes are palpated in the right inguinal area inferior to the inguinal ligament. An excisional biopsy is performed, and histopathology shows malignant cells. The malignant cells found in this patient most likely originated from which of the following sites?

- A. Dome of the bladder (5%)
- B. Lateral lobe of the prostate (12%)
- ✓ C. Orifice of the anal canal (54%)
- D. Upper pole of the testes (17%)
- E. Upper third of the rectum (10%)

Omitted
Correct answer
C

54%
Answered correctly

03 secs
Time Spent

06/23/2020
Last Updated

Explanation

4
5
6
7
8
9
10
11
12
13
14
15
16
17
18
19
20
21
22
23
24
25
26
27
28
29
30
31
32
33
34

Lymph nodes & vessels of large intestine

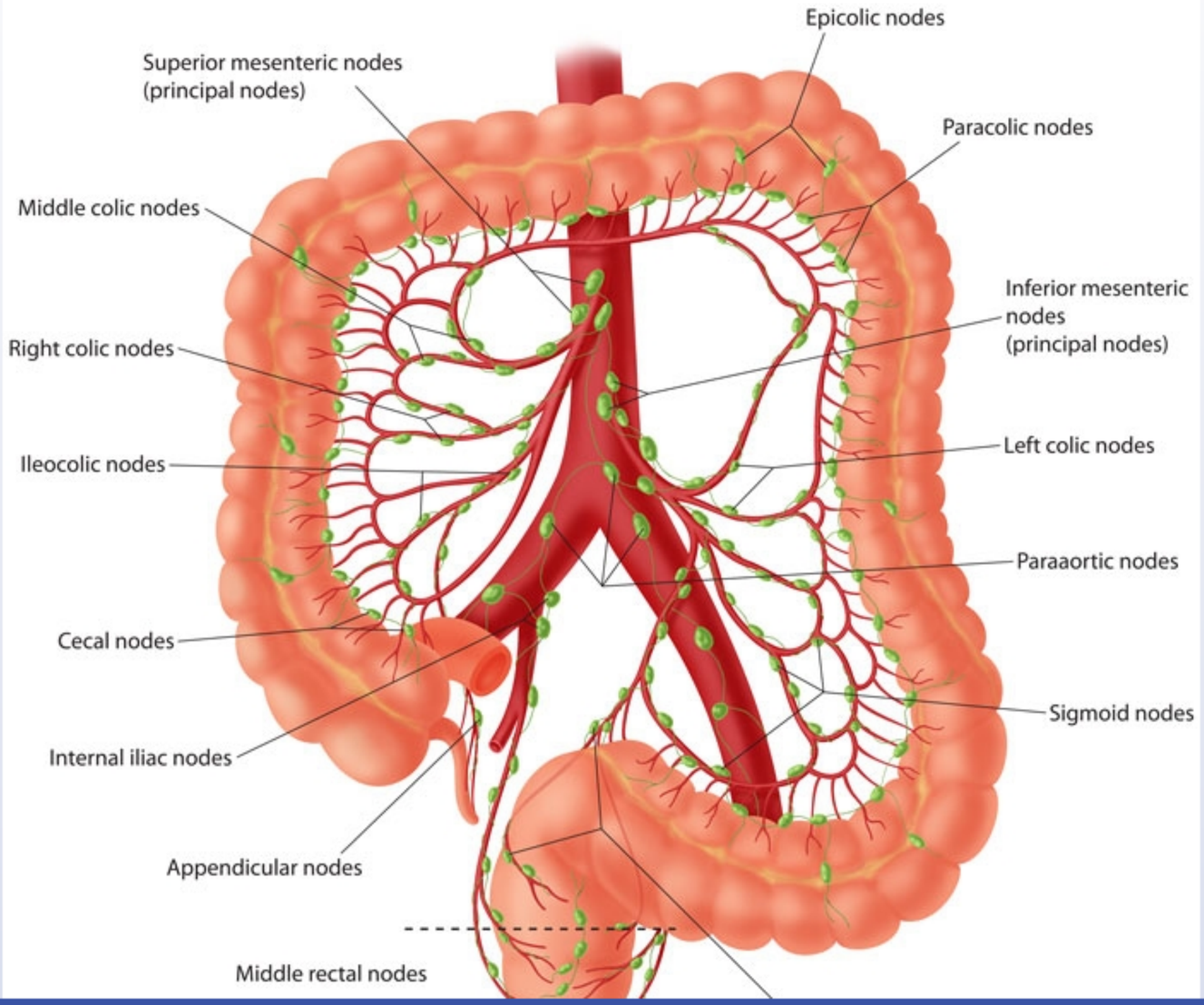

4
5
6
7
8
9
10
11
12
13
14
15
16
17
18
19
20
21
22
23
24
25
26
27
28
29
30
31
32
33
34

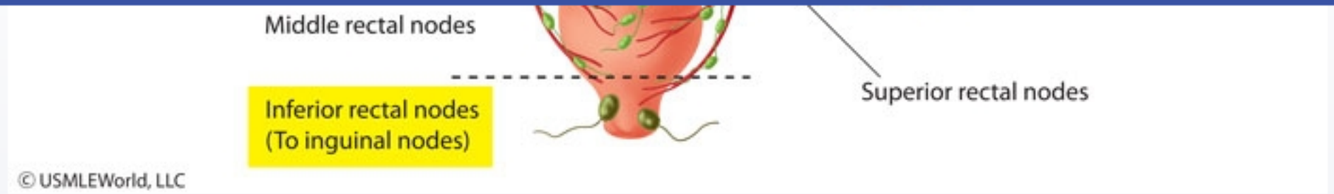

This patient has palpable, firm **superficial inguinal lymph nodes**. These nodes overlie the femoral nerve, artery, and vein in the femoral triangle, a region bound by the inguinal ligament, sartorius muscle, and adductor longus muscle. The superficial inguinal nodes drain **most cutaneous lymph** from the **umbilicus down**, including the external genitalia and anus (below the dentate line). In this patient, metastasis from a malignancy around the orifice of the **anal canal** most likely explains his inguinal lymphadenopathy.

Exceptions to this drainage pattern include the **glans penis** and skin of the **posterior calf** (popliteal lymph nodes), which bypass the superficial inguinal nodes to drain into the deep inguinal lymph nodes.

(Choice A) Lymph from the superior portion of the bladder drains to the external iliac nodes whereas lymph from the inferior portion of the bladder drains to the internal iliac nodes.

(Choice B) Lymph from the prostate drains primarily to the internal iliac nodes.

(Choice D) Lymph from the testes parallels the blood supply from the testicular arteries, which arise directly from the abdominal aorta. As such, testicular lymph drains to the abdominal para-aortic (retroperitoneal) lymph nodes.

(Choice E) Lymph from the upper third of the rectum drains to the inferior mesenteric lymph nodes.

Educational objective:
Most of the cutaneous lymph from the umbilicus down, including the anus below the dentate line, drains to the superficial inguinal lymph nodes. Exceptions are the glans penis and posterior calf, which drain to the deep inguinal nodes.

Anatomy	Gastrointestinal & Nutrition	Lymphatic drainage
Subject	System	Topic

Copyright © UWorld. All rights reserved.

Middle rectal nodes

Exhibit Display

Lymph vessels & nodes of male genitalia

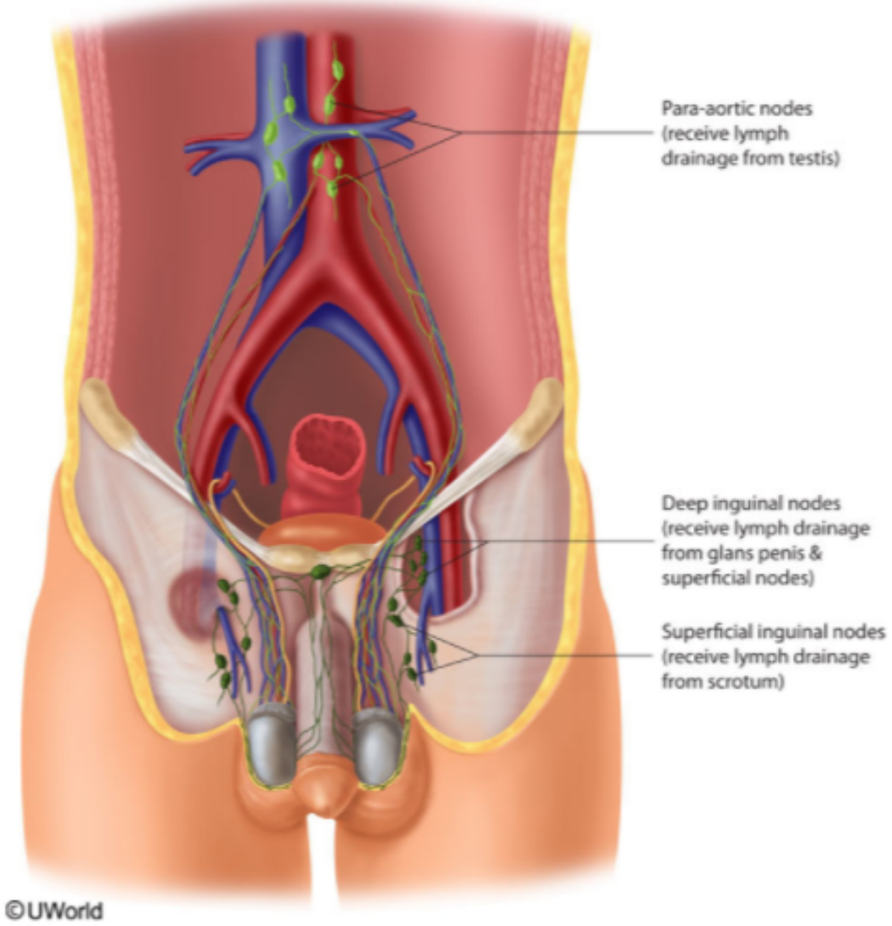

Zoom In | Zoom Out | Reset | Add To New Card | Existing Card

4
5
6
7
8
9
10
11
12
13
14
15
16
17
18
19
20
21
22
23
24
25
26
27
28
29
30
31
32
33
34

A 23-year-old-man is brought to the emergency department after he was stabbed in the right upper quadrant of the abdomen. His blood pressure is 70/42 mm Hg, pulse is 135/min, and respirations are 26/min; pulse oximetry shows oxygen saturation of 95% on room air. Physical examination shows a stab wound 2 cm inferior to the right costal margin. The patient's abdomen is firm and distended. Focused assessment with sonography for trauma (FAST) is positive for blood in the right upper quadrant. He is taken for immediate laparotomy, and approximately 1 liter of blood is evacuated from the peritoneal cavity. Brisk, nonpulsatile bleeding is seen emanating from behind the liver. The surgeon occludes the hepatoduodenal ligament, but the patient continues to hemorrhage. Which of the following structures is the most likely source of this patient's bleeding?

A. Common bile duct
B. Cystic artery
C. Hepatic artery
D. Inferior vena cava
E. Portal vein

Submit

4
5
6
7
8
9
10
11
12
13
14
15
16
17
18
19
20
21
22
23
24
25
26
27
28
29
30
31
32
33
34

A 23-year-old-man is brought to the emergency department after he was stabbed in the right upper quadrant of the abdomen. His blood pressure is 70/42 mm Hg, pulse is 135/min, and respirations are 26/min; pulse oximetry shows oxygen saturation of 95% on room air. Physical examination shows a stab wound 2 cm inferior to the right costal margin. The patient's abdomen is firm and distended. Focused assessment with sonography for trauma (FAST) is positive for blood in the right upper quadrant. He is taken for immediate laparotomy, and approximately 1 liter of blood is evacuated from the peritoneal cavity. Brisk, nonpulsatile bleeding is seen emanating from behind the liver. The surgeon occludes the hepatoduodenal ligament, but the patient continues to hemorrhage. Which of the following structures is the most likely source of this patient's bleeding?

A. Common bile duct (0%)
B. Cystic artery (9%)
C. Hepatic artery (6%)
✓ D. Inferior vena cava (65%)
E. Portal vein (17%)

Omitted
Correct answer
D

65%
Answered correctly

02 secs
Time Spent

04/13/2020
Last Updated

Explanation

4
5
6
7
8
9
10
11
12
13
14
15
16
17
18
19
20
21
22
23
24
25
26
27
28
29
30
31
32
33
34

Pringle maneuver

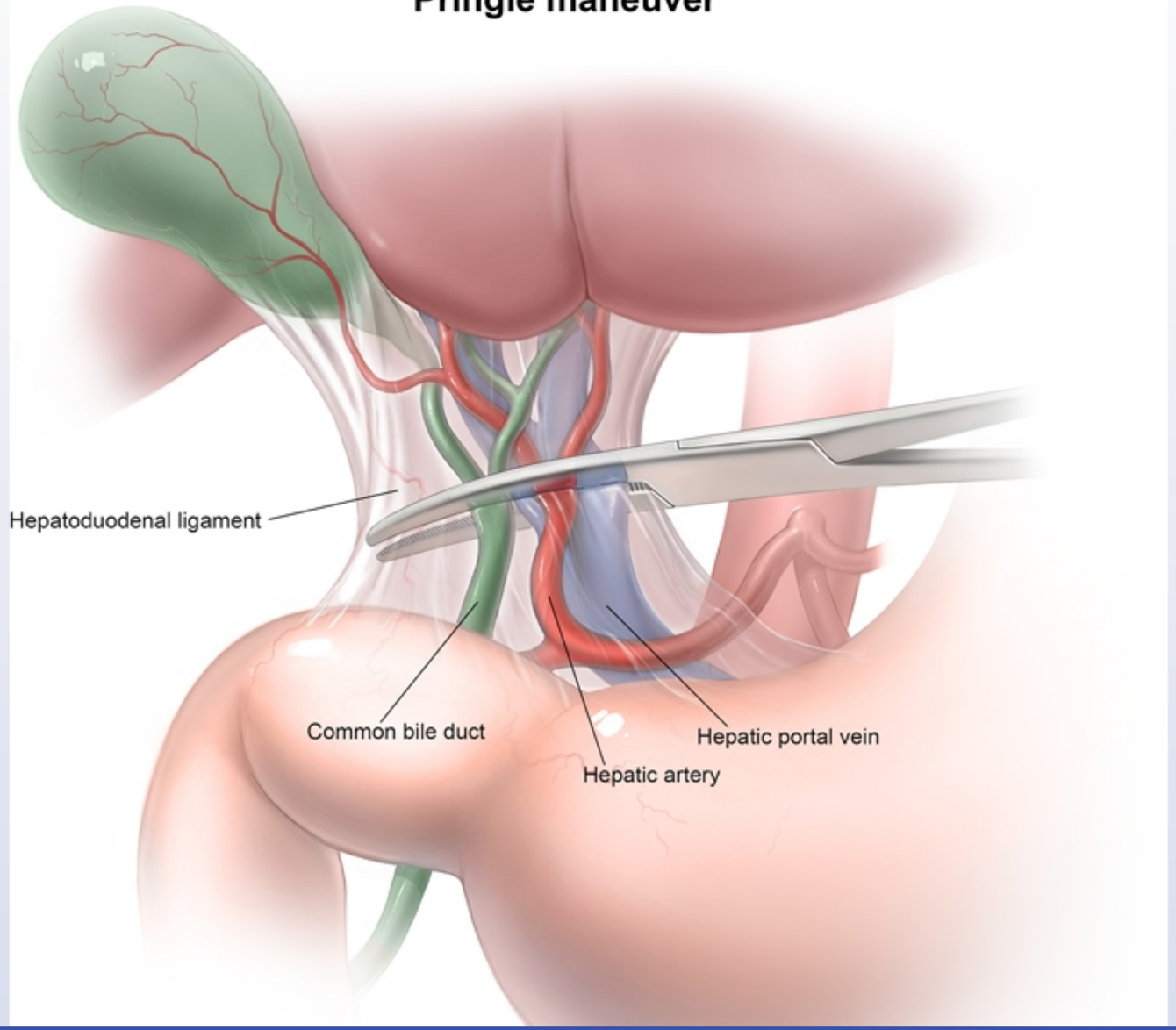

4
5
6
7
8
9
10
11
12
13
14
15
16
17
18
19
20
21
22
23
24
25
26
27
28
29
30
31
32
33
34

©UWorld

The **portal triad** runs through the **hepatoduodenal ligament** and is composed of the hepatic artery, portal vein, and common bile duct. In the setting of traumatic liver injury with persistent bleeding, **occlusion** of the hepatoduodenal ligament can be performed to identify the vascular source (ie, the Pringle maneuver). If liver **bleeding does not cease** when the portal triad is occluded, it is likely that there has been injury to the **inferior vena cava** or hepatic veins. Although the inferior vena cava is a retroperitoneal structure, penetrating trauma can disrupt tissue barriers, facilitating bleeding into the peritoneal compartment.

(Choice A) The common bile duct makes up one-third of the portal triad. Damage to the biliary ducts can cause biliary leakage and bile peritonitis.

(Choice B) The cystic artery most commonly arises from the right hepatic artery and would be devascularized following portal triad occlusion. In addition, arterial bleeding is usually pulsatile whereas venous bleeding is nonpulsatile.

(Choices C and E) The hepatic artery and portal vein are part of the portal triad; occlusion of the hepatoduodenal ligament would cause the bleeding to stop if either of these vessels is the source.

Educational objective:
Occlusion of the portal triad can be used to distinguish the source of right upper quadrant bleeding. If the bleeding subsides following occlusion, the source is likely to be the hepatic artery or portal vein. If hepatic bleeding persists after occlusion, the inferior vena cava or hepatic veins are likely to be injured.

References

- Vascular control during hepatectomy: review of methods and results.
- Emergency strategies and trends in the management of liver trauma.

Anatomy	Gastrointestinal & Nutrition	Penetrating abdominal trauma
Subject	System	Topic

Copyright © UWorld. All rights reserved.

4
5
6
7
8
9
10
11
12
13
14
15
16
17
18
19
20
21
22
23
24
25
26
27
28
29
30
31
32
33
34

A 75-year-old man is brought to the emergency department due to acute-onset profuse vomiting of large amounts of bright red blood. He has had intermittent, dull epigastric pain for the last 3 months. Medical history is significant for chronic obstructive pulmonary disease with multiple exacerbations and lumbar spinal stenosis. The patient has smoked 1 pack of cigarettes daily for 40 years. Blood pressure is 70/40 mm Hg and pulse is 120/min. Examination shows epigastric tenderness. The patient dies an hour after admission despite resuscitation efforts. Autopsy shows a deep peptic ulcer localized proximally on the lesser curvature of the stomach. The ulcer most likely penetrated which of the following arteries?

- A. Common hepatic
- B. Gastroduodenal
- C. Inferior pancreaticoduodenal
- D. Left gastric
- E. Right gastroepiploic
- F. Splenic
- G. Superior mesenteric

Submit

A 75-year-old man is brought to the emergency department due to acute-onset profuse vomiting of large amounts of bright red blood. He has had intermittent, dull epigastric pain for the last 3 months. Medical history is significant for chronic obstructive pulmonary disease with multiple exacerbations and lumbar spinal stenosis. The patient has smoked 1 pack of cigarettes daily for 40 years. Blood pressure is 70/40 mm Hg and pulse is 120/min. Examination shows epigastric tenderness. The patient dies an hour after admission despite resuscitation efforts. Autopsy shows a deep peptic ulcer localized proximally on the lesser curvature of the stomach. The ulcer most likely penetrated which of the following arteries?

- A. Common hepatic (1%)
- B. Gastroduodenal (9%)
- C. Inferior pancreaticoduodenal (0%)
- ✓ D. Left gastric (75%)
- E. Right gastroepiploic (6%)
- F. Splenic (5%)
- G. Superior mesenteric (0%)

Omitted
Correct answer
D

75%
Answered correctly

02 secs
Time Spent

02/27/2020
Last Updated

Explanation

Upper abdominal vasculature

4
5
6
7
8
9
10
11
12
13
14
15
16
17
18
19
20
21
22
23
24
25
26
27
28
29
30
31
32
33
34

Upper abdominal vasculature

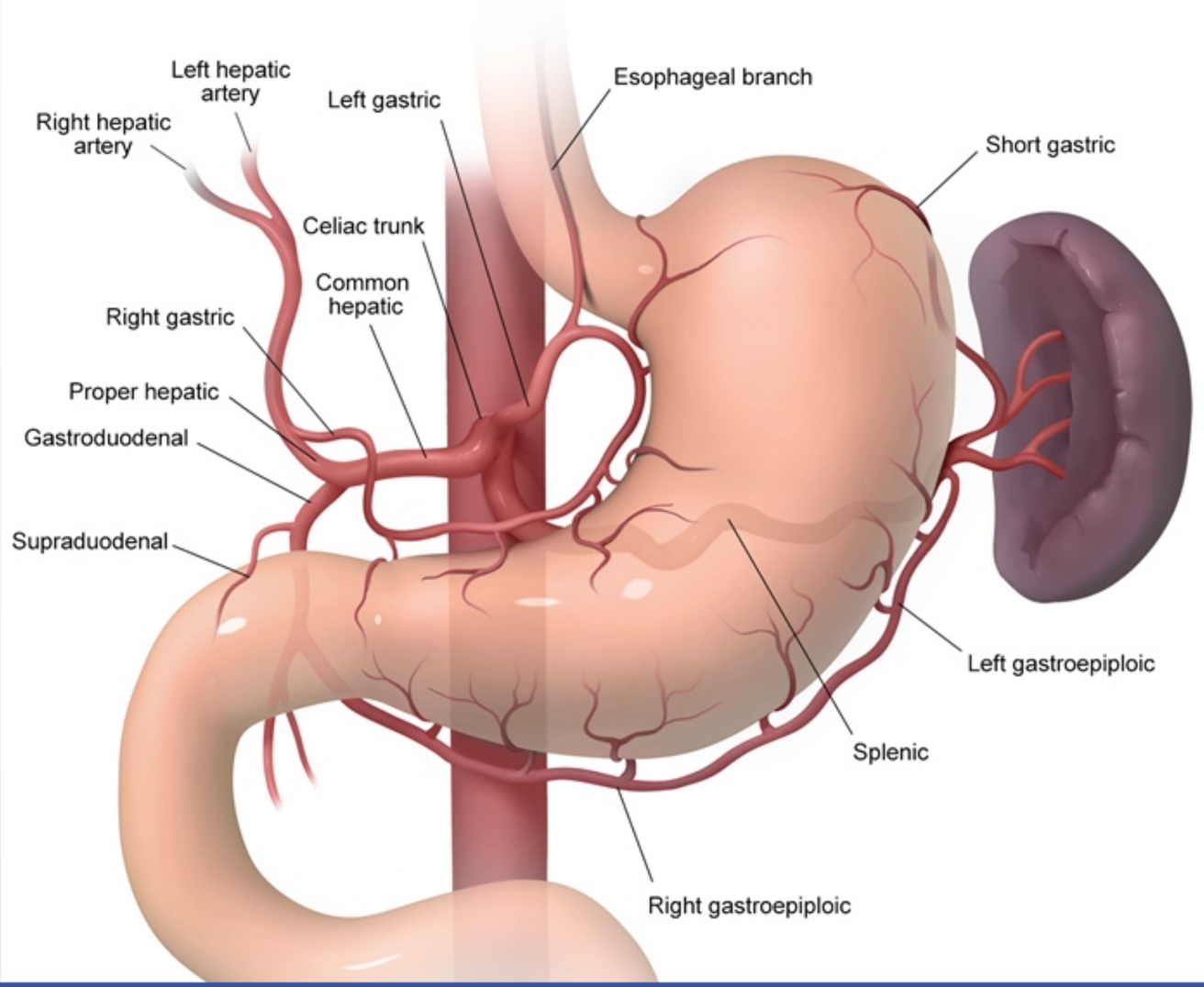

©UWorld

Massive hemorrhage with hypovolemic shock is a potential life-threatening complication of peptic ulcer disease (PUD). Most cases of PUD are due to *Helicobacter pylori* infection or nonsteroidal anti-inflammatory drug use. Other risk factors include smoking, glucocorticoid use, and older age.

Most **gastric ulcers** arise along the **lesser curvature** of the stomach, usually at the transitional zone between the gastric corpus (body) and antrum. Glands in the corpus contain parietal cells that produce hydrochloric acid and intrinsic factor; mucosal glands in the antrum contain G cells that secrete gastrin. This **transitional zone** provides the optimal microenvironment (eg, pH, host immune factors) for *H pylori* proliferation. The resultant inflammation leads to mucosal atrophy and ulcer formation.

The left and right **gastric arteries** run along and perfuse the lesser curvature of the stomach, and are a common source of hemorrhage from penetrating gastric ulcers. Other potential complications of PUD include penetration into other adjacent structures (eg, biliary tract, colon), gastric outlet obstruction, and free wall perforation with peritonitis.

(Choices A and B) The common hepatic artery perfuses the liver, gallbladder, pylorus, duodenum, and pancreas. It arises from the celiac trunk and ends when it bifurcates into the proper hepatic and gastroduodenal arteries. The gastroduodenal artery supplies blood to the pylorus and proximal duodenum. Ulcers in the posterior duodenal bulb can erode into the gastroduodenal artery, but a gastric ulcer at the lesser curvature would not involve these arteries.

(Choices C and G) The superior mesenteric and inferior pancreaticoduodenal arteries do not perfuse the stomach.

(Choice E) The right gastroepiploic artery arises from the gastroduodenal artery and perfuses the distal greater curvature of the stomach. Gastric ulcers do not commonly occur in the greater curvature.

(Choice F) The splenic artery arises from the celiac trunk and supplies blood to the spleen. It is separated from the posterior wall of the stomach by the pancreas and is only rarely penetrated by gastric ulcers.

Educational objective:
Most gastric ulcers arise along the lesser curvature of the stomach, usually at the transitional zone between the gastric corpus (body) and antrum. The left and right gastric arteries run along the lesser curvature and are likely to be penetrated by ulcers, causing gastric bleeding.

Anatomy Gastrointestinal & Nutrition Peptic ulcer disease

4
5
6
7
8
9
10
11
12
13
14
15
16
17
18
19
20
21
22
23
24
25
26
27
28
29
30
31
32
33
34

Most **gastric ulcers** arise along the **lesser curvature** of the stomach, usually at the transitional zone between the gastric corpus (body) and antrum. Glands in the corpus contain parietal cells that produce hydrochloric acid and intrinsic factor; mucosal glands in the antrum contain G cells that secrete gastrin. This **transitional zone** provides the optimal microenvironment (eg, pH, host immune factors) for *H pylori* proliferation. The resultant inflammation leads to mucosal atrophy and ulcer formation.

The left and right **gastric arteries** run along and perfuse the lesser curvature of the stomach, and are a common source of hemorrhage from penetrating gastric ulcers. Other potential complications of PUD include penetration into other adjacent structures (eg, biliary tract, colon), gastric outlet obstruction, and free wall perforation with peritonitis.

(Choices A and B) The common hepatic artery perfuses the liver, gallbladder, pylorus, duodenum, and pancreas. It arises from the celiac trunk and ends when it bifurcates into the proper hepatic and gastroduodenal arteries. The gastroduodenal artery supplies blood to the pylorus and proximal duodenum. Ulcers in the posterior duodenal bulb can erode into the gastroduodenal artery, but a gastric ulcer at the lesser curvature would not involve these arteries.

(Choices C and G) The superior mesenteric and inferior pancreaticoduodenal arteries do not perfuse the stomach.

(Choice E) The right gastroepiploic artery arises from the gastroduodenal artery and perfuses the distal greater curvature of the stomach. Gastric ulcers do not commonly occur in the greater curvature.

(Choice F) The splenic artery arises from the celiac trunk and supplies blood to the spleen. It is separated from the posterior wall of the stomach by the pancreas and is only rarely penetrated by gastric ulcers.

Educational objective:
Most gastric ulcers arise along the lesser curvature of the stomach, usually at the transitional zone between the gastric corpus (body) and antrum. The left and right gastric arteries run along the lesser curvature and are likely to be penetrated by ulcers, causing gastric bleeding.

Anatomy	Gastrointestinal & Nutrition	Peptic ulcer disease
Subject	System	Topic

Copyright © UWorld. All rights reserved.

4
5
6
7
8
9
10
11
12
13
14
15
16
17
18
19
20
21
22
23
24
25
26
27
28
29
30
31
32
33
34

A 52-year-old man is brought to the emergency department due to repeated vomiting that began 2 hours ago. His vomit is dark brown and has a granular consistency. The patient has a history of dyspepsia, for which he takes over-the-counter antacids as needed and degenerative knee arthritis, for which he takes naproxen regularly. He drinks 2-3 beers daily. Temperature is 36.7 C (98 F), blood pressure is 114/62 mm Hg, pulse is 102/min, and respirations are 14/min. Physical examination reveals mild epigastric tenderness with no rebound or guarding. Hemoglobin is 9 g/dL. Endoscopy shows a deep, bleeding ulcer on the posterior wall of the duodenal bulb. This patient's ulcer has most likely penetrated which of the following arteries?

A. Common hepatic
B. Gastroduodenal
C. Inferior pancreaticoduodenal
D. Left gastroepiploic
E. Right gastric
F. Splenic
G. Superior mesenteric

Submit

4
5
6
7
8
9
10
11
12
13
14
15
16
17
18
19
20
21
22
23
24
25
26
27
28
29
30
31
32
33
34

A 52-year-old man is brought to the emergency department due to repeated vomiting that began 2 hours ago. His vomit is dark brown and has a granular consistency. The patient has a history of dyspepsia, for which he takes over-the-counter antacids as needed and degenerative knee arthritis, for which he takes naproxen regularly. He drinks 2-3 beers daily. Temperature is 36.7 C (98 F), blood pressure is 114/62 mm Hg, pulse is 102/min, and respirations are 14/min. Physical examination reveals mild epigastric tenderness with no rebound or guarding. Hemoglobin is 9 g/dL. Endoscopy shows a deep, bleeding ulcer on the posterior wall of the duodenal bulb. This patient's ulcer has most likely penetrated which of the following arteries?

- A. Common hepatic (1%)
- ✓ B. Gastroduodenal (78%)
- C. Inferior pancreaticoduodenal (10%)
- D. Left gastroepiploic (2%)
- E. Right gastric (3%)
- F. Splenic (1%)
- G. Superior mesenteric (1%)

Omitted
Correct answer
B

78%
Answered correctly

02 secs
Time Spent

03/04/2020
Last Updated

Explanation

Duodenal ulcers and surrounding anatomy

4
5
6
7
8
9
10
11
12
13
14
15
16
17
18
19
20
21
22
23
24
25
26
27
28
29
30
31
32
33
34

Duodenal ulcers and surrounding anatomy

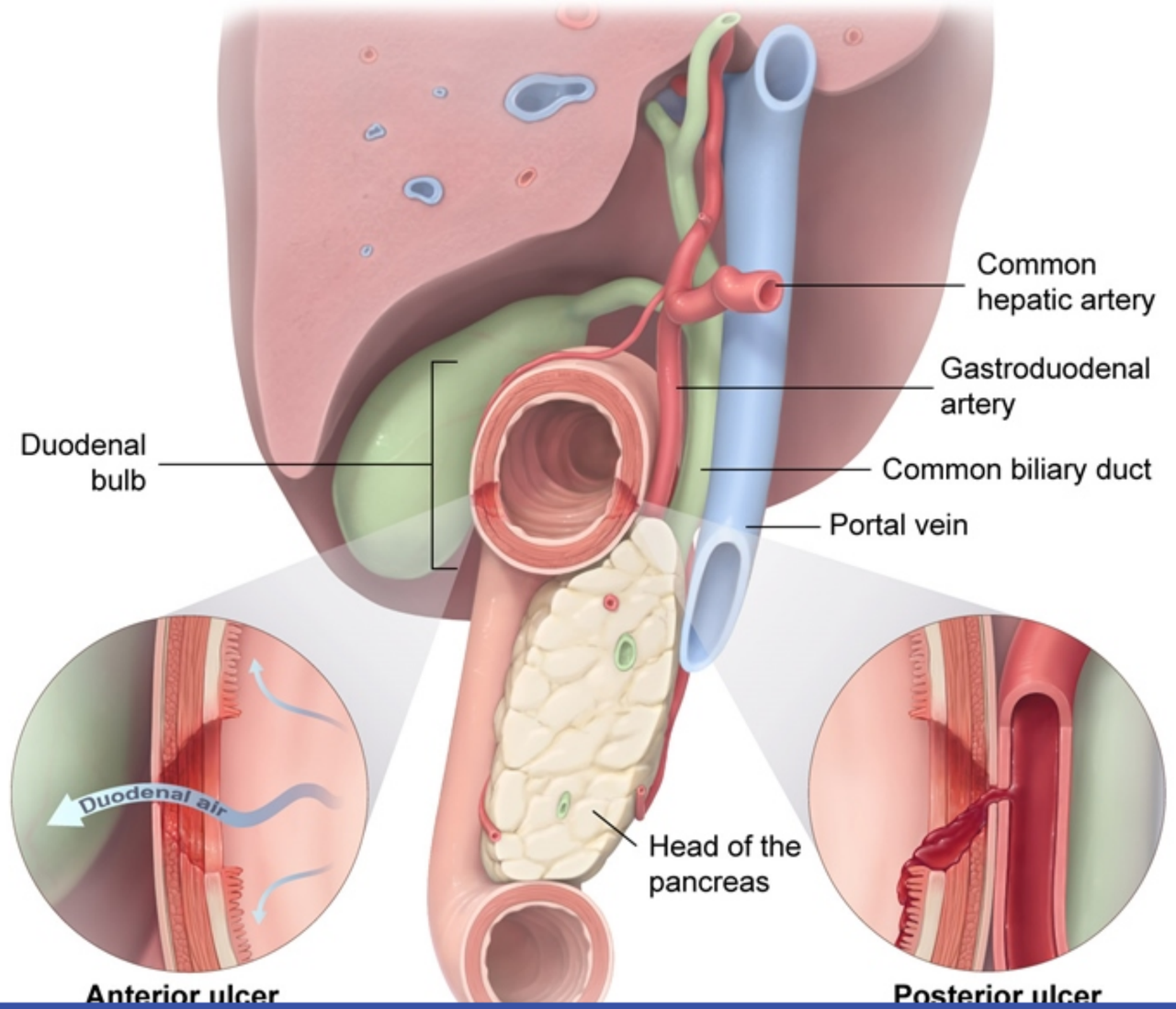

©UWorld

Bleeding peptic ulcer disease should be considered in patients who develop acute epigastric pain, unstable vital signs, or hematemesis, particularly in the setting of prior dyspepsia. Most peptic ulcers are caused by *Helicobacter pylori* infection or nonsteroidal anti-inflammatory drug use; other risk factors include smoking, older age, and glucocorticoid use.

Duodenal ulcers are more common than gastric ulcers and tend to occur anteriorly. Ulcers located on the anterior wall of the duodenal bulb are more prone to perforation; those on the posterior wall are more likely to cause hemorrhage. These complications are explained by the relationship of the duodenal bulb to adjacent organs. The duodenal bulb is approximately 5 cm long, beginning at the pylorus and ending at the neck of the gallbladder. The gallbladder and liver lie anterior to the duodenal bulb within the intraperitoneal space; the gastroduodenal artery, common biliary duct, and portal vein are posterior to the bulb; and the head of the pancreas is located inferiorly.

When an ulcer penetrates the **posterior duodenal wall**, it is likely to erode into the gastroduodenal artery, which perfuses both the pylorus and the proximal part of the duodenum. Damage to the gastroduodenal artery can cause significant **upper gastrointestinal bleeding**.

(Choice A) The common hepatic artery arises from the celiac trunk and bifurcates into the proper hepatic and gastroduodenal arteries. It passes superior to the duodenal bulb.

(Choice C) The inferior pancreaticoduodenal artery is a branch of the superior mesenteric artery. It supplies blood to the lower duodenum and to the head of the pancreas. This artery has no close relation to the duodenal bulb.

(Choices D, E, and F) The left gastroepiploic and right gastric arteries supply blood to the greater and lesser curves of the stomach, respectively. The short gastric arteries arise off the splenic artery and supply the upper portions of the greater curvature. These vessels do not lie in close proximity to the duodenal bulb.

(Choice G) The superior mesenteric artery lies anterior to the transverse part of the duodenum. It arises from the anterior surface of the abdominal aorta and supplies the intestine from the duodenum to the proximal two-thirds of the transverse colon.

Educational objective:
The gastroduodenal artery lies along the posterior wall of the duodenal bulb and is likely to be eroded by posterior duodenal ulcers. Ulceration into the gastroduodenal artery can be a source of life-threatening hemorrhage.

4
5
6
7
8
9
10
11
12
13
14
15
16
17
18
19
20
21
22
23
24
25
26
27
28
29
30
31
32
33
34

Duodenal ulcers are more common than gastric ulcers and tend to occur anteriorly. Ulcers located on the anterior wall of the duodenal bulb are more prone to perforation; those on the posterior wall are more likely to cause hemorrhage. These complications are explained by the relationship of the duodenal bulb to adjacent organs. The duodenal bulb is approximately 5 cm long, beginning at the pylorus and ending at the neck of the gallbladder. The gallbladder and liver lie anterior to the duodenal bulb within the intraperitoneal space; the gastroduodenal artery, common biliary duct, and portal vein are posterior to the bulb; and the head of the pancreas is located inferiorly.

When an ulcer penetrates the **posterior duodenal wall**, it is likely to erode into the gastroduodenal artery, which perfuses both the pylorus and the proximal part of the duodenum. Damage to the gastroduodenal artery can cause significant **upper gastrointestinal bleeding**.

(Choice A) The common hepatic artery arises from the celiac trunk and bifurcates into the proper hepatic and gastroduodenal arteries. It passes superior to the duodenal bulb.

(Choice C) The inferior pancreaticoduodenal artery is a branch of the superior mesenteric artery. It supplies blood to the lower duodenum and to the head of the pancreas. This artery has no close relation to the duodenal bulb.

(Choices D, E, and F) The left gastroepiploic and right gastric arteries supply blood to the greater and lesser curves of the stomach, respectively. The short gastric arteries arise off the splenic artery and supply the upper portions of the greater curvature. These vessels do not lie in close proximity to the duodenal bulb.

(Choice G) The superior mesenteric artery lies anterior to the transverse part of the duodenum. It arises from the anterior surface of the abdominal aorta and supplies the intestine from the duodenum to the proximal two-thirds of the transverse colon.

Educational objective:
The gastroduodenal artery lies along the posterior wall of the duodenal bulb and is likely to be eroded by posterior duodenal ulcers. Ulceration into the gastroduodenal artery can be a source of life-threatening hemorrhage.

Anatomy	Gastrointestinal & Nutrition	Peptic ulcer disease
Subject	System	Topic

Copyright © UWorld. All rights reserved.

4
5
6
7
8
9
10
11
12
13
14
15
16
17
18
19
20
21
22
23
24
25
26
27
28
29
30
31
32
33
34

Exhibit Display

Upper abdominal vasculature

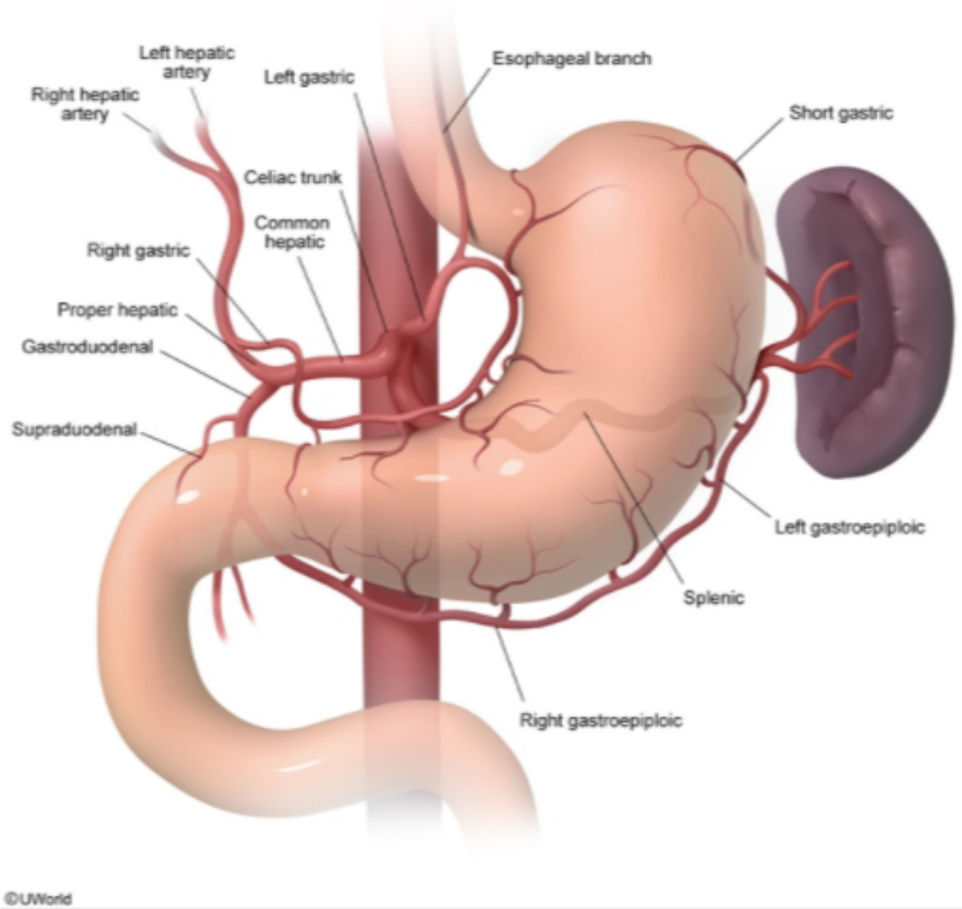

Zoom In | Zoom Out | Reset | Add To New Card | Existing Card

4
5
6
7
8
9
10
11
12
13
14
15
16
17
18
19
20
21
22
23
24
25
26
27
28
29
30
31
32
33
34

A 54-year-old man is evaluated for episodic abdominal discomfort, bloating sensation, flatulence, and occasional diarrhea. He has no blood in the stool or weight loss. The patient has tried avoiding dairy products, but the symptoms did not improve. On examination, there is mild epigastric tenderness on deep palpation. Stool occult blood testing is positive. Histopathological evaluation of hyperemic mucosa seen during gastrointestinal endoscopy reveals hyperplasia of branched, tubular submucosal glands containing alkaline secretions. Which of the following areas is the most likely site of biopsy in this patient?

A. Antrum of the stomach
B. First part of the duodenum
C. Fundus of the stomach
D. Mid-part of the jejunum
E. Terminal ileum
F. Transverse colon

Submit

A 54-year-old man is evaluated for episodic abdominal discomfort, bloating sensation, flatulence, and occasional diarrhea. He has no blood in the stool or weight loss. The patient has tried avoiding dairy products, but the symptoms did not improve. On examination, there is mild epigastric tenderness on deep palpation. Stool occult blood testing is positive. Histopathological evaluation of hyperemic mucosa seen during gastrointestinal endoscopy reveals hyperplasia of branched, tubular submucosal glands containing alkaline secretions. Which of the following areas is the most likely site of biopsy in this patient?

- A. Antrum of the stomach (6%)
- ✓ B. First part of the duodenum (77%)
- C. Fundus of the stomach (3%)
- D. Mid-part of the jejunum (5%)
- E. Terminal ileum (4%)
- F. Transverse colon (3%)

Omitted
Correct answer
B

77%
Answered correctly

02 secs
Time Spent

04/05/2020
Last Updated

Explanation

The integrity of the small intestinal mucosa depends on the complete and rapid neutralization of hydrochloric acid in gastric contents. This is accomplished by alkaline secretions from 2 primary sources:

- **Submucosal (Brunner) glands** secrete copious amounts of alkaline mucus into the duodenum. These glands are most numerous at the pylorus but may be found intermittently up to the ampulla of Vater. The ducts of these glands pass through the muscularis mucosa and

4
5
6
7
8
9
10
11
12
13
14
15
16
17
18
19
20
21
22
23
24
25
26
27
28
29
30
31
32
33
34

The integrity of the small intestinal mucosa depends on the complete and rapid neutralization of hydrochloric acid in gastric contents. This is accomplished by alkaline secretions from 2 primary sources:

- **Submucosal (Brunner) glands** secrete copious amounts of alkaline mucus into the duodenum. These glands are most numerous at the pylorus but may be found intermittently up to the ampulla of Vater. The ducts of these glands pass through the muscularis mucosa and terminate in the mucosal crypts (crypts of Lieberkühn).
- The epithelial cells of the pancreatic ductules and ducts produce watery secretions containing high concentrations of bicarbonate ions. The strongly alkaline pancreatic secretions are then emptied into the duodenum at the ampulla.

Tactile stimulation of the duodenal mucosa and increased parasympathetic activity following meals induce bicarbonate secretion from the submucosal glands. In addition, the presence of acid in the duodenum and jejunum causes release of **secretin** from the mucosa, stimulating secretion of bicarbonate from the submucosal glands and pancreas. Excess gastric acid secretion, such as seen in *Helicobacter pylori* infection, can cause increased production of secretin that, over time, can lead to hyperplasia of the submucosal glands.

(Choices A and C) The antrum of the stomach contains numerous pyloric glands that secrete copious mucus for protection of the mucosa. Gastric acid is primarily secreted by parietal cells of the oxyntic glands at the body and fundus of the stomach.

(Choice D) The mucosal crypts in the jejunum contain goblet cells (secrete mucus) and enterocytes (secrete water and electrolytes). These secretions have only minimal bicarbonate content.

(Choices E and F) Bicarbonate is secreted by epithelial cells in the ileum and colon to neutralize acid produced by colonic bacteria. However, this bicarbonate is secreted at the villi in the ileum and crypts in the colon, and submucosal glands are not present in these locations.

Educational objective:
Gastric acid is neutralized by bicarbonate from the submucosal glands of the duodenum (Brunner glands) and from pancreatic duct secretions. Chronic overproduction of gastric acid can lead to hyperplasia of the submucosal glands.

Anatomy	Gastrointestinal & Nutrition	H pylori
Subject	System	Topic

4
5
6
7
8
9
10
11
12
13
14
15
16
17
18
19
20
21
22
23
24
25
26
27
28
29
30
31
32
33
34

A 47-year-old morbidly obese woman comes to the physician seeking advice regarding weight loss. She has tried diet and exercise a number of times without success. Her other medical problems include type 2 diabetes mellitus and obstructive sleep apnea. Her body mass index is 43 kg/m^2. After a discussion about available surgical options, she expresses interest in the adjustable gastric band, an inflatable silicone device that is placed around the cardiac part of the stomach. In order to encircle the stomach, the band must pass through which of the following structures?

A. Falciform ligament

B. Gastrocolic ligament

C. Greater omentum

D. Lesser omentum

E. Splenorenal ligament

Submit

4
5
6
7
8
9
10
11
12
13
14
15
16
17
18
19
20
21
22
23
24
25
26
27
28
29
30
31
32
33
34

A 47-year-old morbidly obese woman comes to the physician seeking advice regarding weight loss. She has tried diet and exercise a number of times without success. Her other medical problems include type 2 diabetes mellitus and obstructive sleep apnea. Her body mass index is 43 kg/m^2. After a discussion about available surgical options, she expresses interest in the adjustable gastric band, an inflatable silicone device that is placed around the cardiac part of the stomach. In order to encircle the stomach, the band must pass through which of the following structures?

- A. Falciform ligament (4%)
- B. Gastrocolic ligament (14%)
- C. Greater omentum (18%)
- ✓ D. Lesser omentum (60%)
- E. Splenorenal ligament (2%)

Omitted
Correct answer
D

60%
Answered correctly

02 secs
Time Spent

06/24/2020
Last Updated

Explanation



4
5
6
7
8
9
10
11
12
13
14
15
16
17
18
19
20
21
22
23
24
25
26
27
28
29
30
31
32
33
34

Greater & lesser omentum

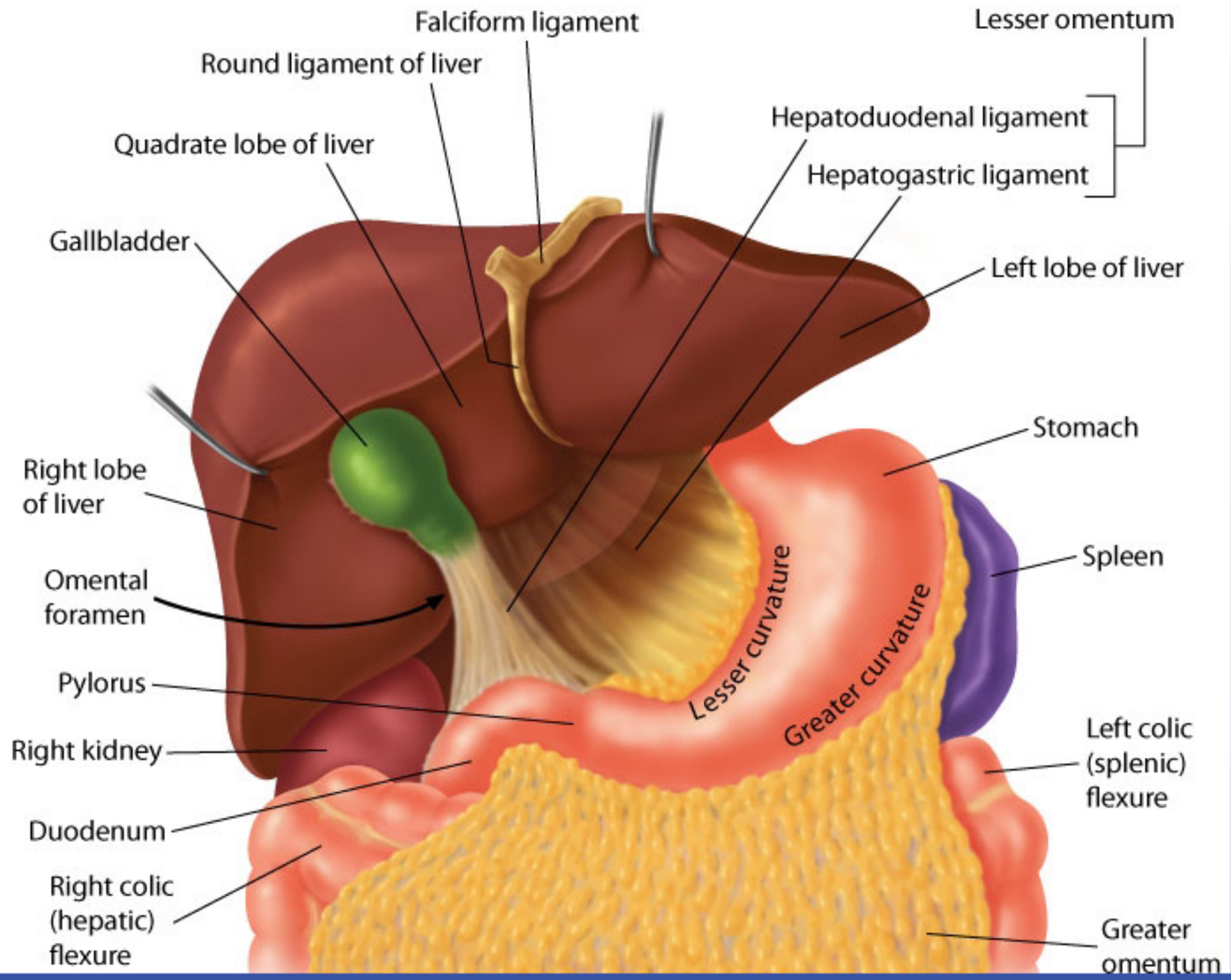

Adjustable gastric banding is a type of restrictive bariatric surgery designed for obese patients. The adjustable gastric band is an inflatable silicone device placed around the gastric cardia. It is intended to slow the passage of food, increasing satiety and limiting the amount of food consumed. To encircle the upper stomach, the gastric band must pass through the lesser omentum.

The lesser omentum is a double layer of peritoneum that extends from the liver to the lesser curvature of the stomach and the beginning of the duodenum. Anatomically, the lesser omentum is divided into 2 ligaments:

1. Hepatogastric ligament: the portion connecting to the lesser curvature of the stomach
2. Hepatoduodenal ligament: the portion connecting to the duodenum

Between the 2 layers of the lesser omentum, close to the right-sided free margin, lie the hepatic artery, common bile duct, portal vein, lymphatics, and hepatic plexus. The right and left gastric arteries and gastric veins also lie between the 2 layers, near where the lesser omentum attaches to the stomach.

(Choice A) The falciform ligament attaches the liver to the anterior body wall. It is a derivative of the embryonic ventral mesentery and contains the round ligament, the remnant of the fetal umbilical vein.

(Choices B and C) The greater omentum is a large fold of visceral peritoneum that extends from the greater curvature of the stomach, travels inferiorly over the small intestine, and then reflects on itself and ascends to encompass the transverse colon before reaching the posterior abdominal wall. The gastrocolic ligament is the section that stretches from the greater curvature of the stomach to the transverse colon. It forms part of the anterior wall of the lesser sac and is often divided during surgery to provide access to the anterior pancreas and posterior wall of the stomach.

(Choice E) The splenorenal ligament is derived from the peritoneum and lies between the left kidney and the spleen. It contains the splenic vessels and the tail of the pancreas.

Educational objective:
The lesser omentum is a double layer of peritoneum that extends from the liver to the lesser curvature of the stomach and the beginning of the duodenum. It is divided into the hepatogastric and hepatoduodenal ligaments.

Anatomy Gastrointestinal & Nutrition Obesity

Exhibit Display

Adjustable gastric band

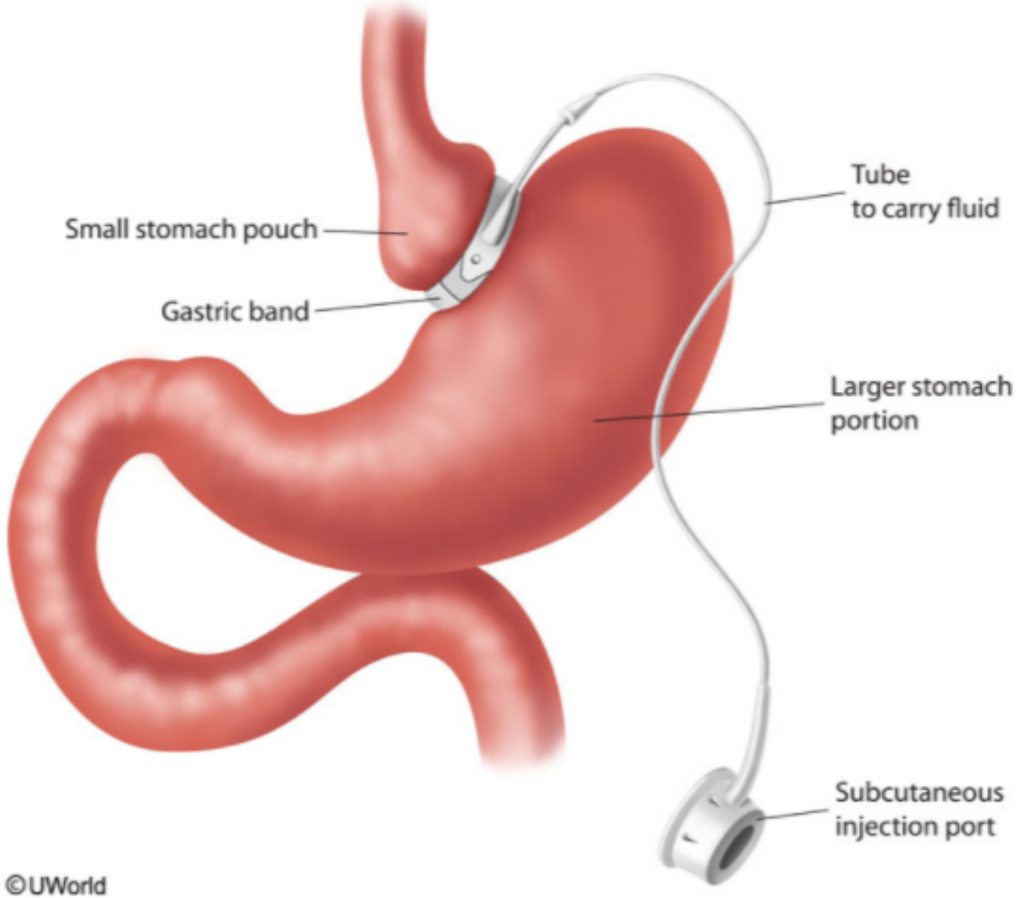

©UWorld

Zoom In | Zoom Out | Reset | Add To New Card | Existing Card

Anatomy | Gastrointestinal & Nutrition | Obesity

4
5
6
7
8
9
10
11
12
13
14
15
16
17
18
19
20
21
22
23
24
25
26
27
28
29
30
31
32
33
34

A 62-year-old man comes to the physician due to intermittent groin pain. The pain is most severe when the patient lifts heavy loads and after a long day at his job as a construction worker. Physical examination shows a right-sided groin bulge directly above the inguinal ligament. The bulge increases in size when he bears down. An ultrasound reveals that the mass originates medial to the inferior epigastric vessels. This patient's condition is most likely caused by which of the following?

A. Failure of the internal inguinal ring to close

B. Patent processus vaginalis

C. Separation of the abdominal muscles

D. Weakness of the transversalis fascia

E. Widening of the femoral ring

Submit

A 62-year-old man comes to the physician due to intermittent groin pain. The pain is most severe when the patient lifts heavy loads and after a long day at his job as a construction worker. Physical examination shows a right-sided groin bulge directly above the inguinal ligament. The bulge increases in size when he bears down. An ultrasound reveals that the mass originates medial to the inferior epigastric vessels. This patient's condition is most likely caused by which of the following?

- A. Failure of the internal inguinal ring to close (3%)
- B. Patent processus vaginalis (5%)
- C. Separation of the abdominal muscles (5%)
- ✓ D. Weakness of the transversalis fascia (83%)
- E. Widening of the femoral ring (1%)

Omitted
Correct answer
D

83%
Answered correctly

02 secs
Time Spent

05/12/2020
Last Updated

Explanation

Groin hernias			
Type	**Classic presentation**	**Pathophysiology**	**Anatomy**
Indirect	Male infants	Patent processus vaginalis	• Originates lateral to inferior epigastric vessels • Protrudes through the deep inguinal ring into inguinal canal

4
5
6
7
8
9
10
11
12
13
14
15
16
17
18
19
20
21
22
23
24
25
26
27
28
29
30
31
32
33
34

Groin hernias			
Type	**Classic presentation**	**Pathophysiology**	**Anatomy**
Indirect inguinal	Male infants	Patent processus vaginalis	• Originates lateral to inferior epigastric vessels • Protrudes through the deep inguinal ring into inguinal canal • May extend into the scrotum (following spermatic cord)
Direct inguinal	Older men	Weakness of transversalis fascia	• Protrudes medial to the inferior epigastric vessels into Hesselbach's triangle • May pass through superficial inguinal ring • No direct route into the scrotum
Femoral	Women	Widening of the femoral ring	• Emerges inferior to inguinal ligament • Protrudes through the femoral ring into the femoral canal

Direct and indirect inguinal hernias are both located **above the inguinal ligament**. They can be differentiated by their side of origination in relation to the inferior epigastric vessels. Direct inguinal hernias originate medial to the inferior epigastric vessels, while indirect inguinal hernias originate lateral to the inferior epigastric vessels.

This patient's groin mass originating **medial** to the inferior epigastric vessels is characteristic of a **direct inguinal hernia** in the Hesselbach triangle. The transversalis fascia makes up the floor of the triangle, and **defects or weakness** involving the **transversalis fascia** can lead to protrusion of abdominal contents. Failure of this fascial layer is most often due to acquired connective tissue abnormalities or chronic abdominal wall injury (most commonly in older men).

Unlike indirect inguinal hernias, direct inguinal hernias do not pass through the internal (deep) inguinal ring but only through the external (superficial) inguinal ring. As a result, they do not have a direct route to the scrotum.

(Choices A and B) Indirect inguinal hernias are the most common type of groin hernia in both sexes. The underlying etiology is usually congenital: due to failure of the processus vaginalis to obliterate (in males) or of the deep inguinal ring to close (in females). Indirect inguinal

4
5
6
7
8
9
10
11
12
13
14
15
16
17
18
19
20
21
22
23
24
25
26
27
28
29
30
31
32
33
34

Direct and indirect inguinal hernias are both located **above the inguinal ligament**. They can be differentiated by their side of origination in relation to the inferior epigastric vessels. Direct inguinal hernias originate medial to the inferior epigastric vessels, while indirect inguinal hernias originate lateral to the inferior epigastric vessels.

This patient's groin mass originating **medial** to the inferior epigastric vessels is characteristic of a **direct inguinal hernia** in the Hesselbach triangle. The transversalis fascia makes up the floor of the triangle, and **defects or weakness** involving the **transversalis fascia** can lead to protrusion of abdominal contents. Failure of this fascial layer is most often due to acquired connective tissue abnormalities or chronic abdominal wall injury (most commonly in older men).

Unlike indirect inguinal hernias, direct inguinal hernias do not pass through the internal (deep) inguinal ring but only through the external (superficial) inguinal ring. As a result, they do not have a direct route to the scrotum.

(Choices A and B) Indirect inguinal hernias are the most common type of groin hernia in both sexes. The underlying etiology is usually congenital; due to failure of the processus vaginalis to obliterate (in males) or of the deep inguinal ring to close (in females). Indirect inguinal hernias protrude through the internal inguinal ring, lateral to the inferior epigastric vessels, allowing them to follow the same path as the spermatic cord though the inguinal canal and into the scrotum.

(Choice C) Diastasis rectus abdominus is characterized by an abnormally large separation between the rectus abdominus muscles due to stretching and laxity of the linea alba. This usually occurs in states with increased intraabdominal pressure (eg, pregnancy, obesity) and characteristically presents with a bulge in the midline around the umbilicus (rather than in the groin directly above the inguinal ligament).

(Choice E) Femoral hernias occur mainly in older women due to laxity and widening of the femoral ring, which allows abdominal contents to protrude below the inguinal ligament into the femoral canal.

Educational objective:
Direct inguinal hernias occur most commonly in older men due to weakness of the transversalis fascia. They protrude medial to the inferior epigastric vessels into the Hesselbach triangle and pass only through the superficial inguinal ring with no direct route to the scrotum.

Anatomy	Gastrointestinal & Nutrition	Groin hernias
Subject	System	Topic

Direct and indirect inguinal hernias are both located **above the inguinal ligament**. They can be differentiated by their side of origination in

Exhibit Display

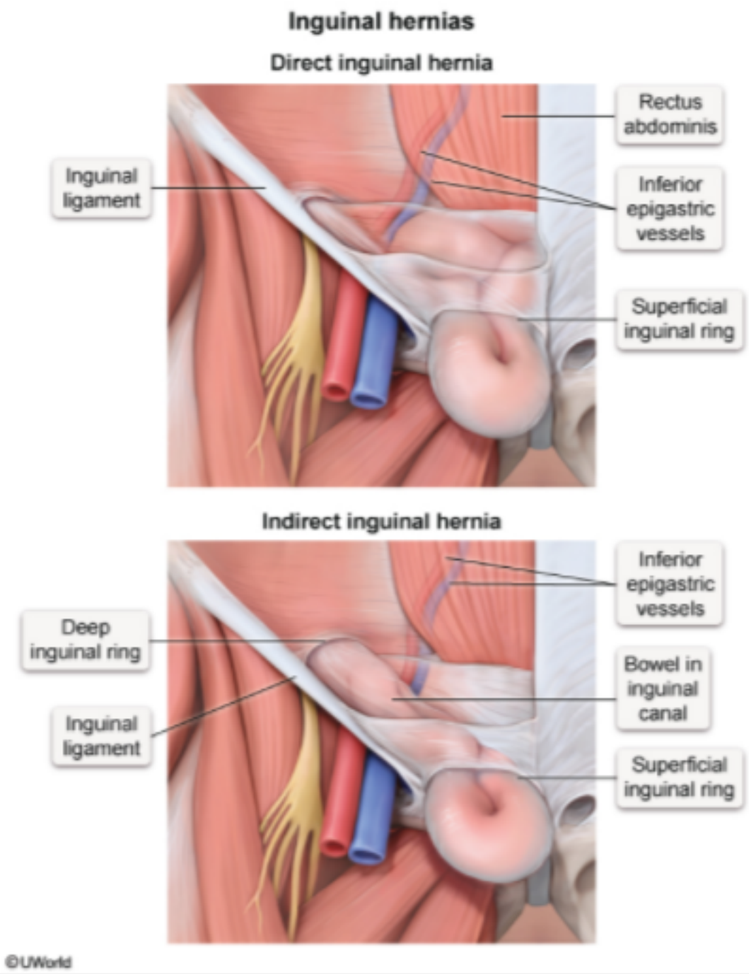

Zoom In | Zoom Out | Reset | Add To New Card | Existing Card

Direct and indirect inguinal hernias are both located **above the inguinal ligament**. They can be differentiated by their side of origination in

Exhibit Display

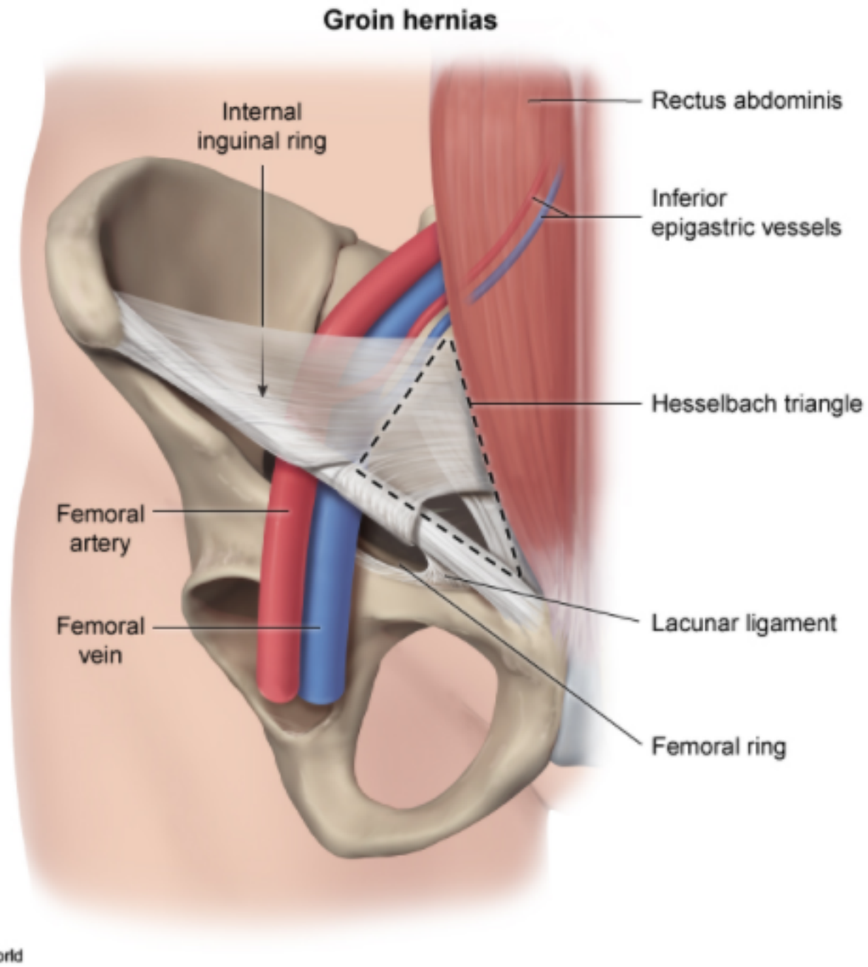

Zoom In | Zoom Out | Reset | Add To New Card | Existing Card

Direct and indirect inguinal hernias are both located **above the inguinal ligament**. They can be differentiated by their side of origination in

Exhibit Display

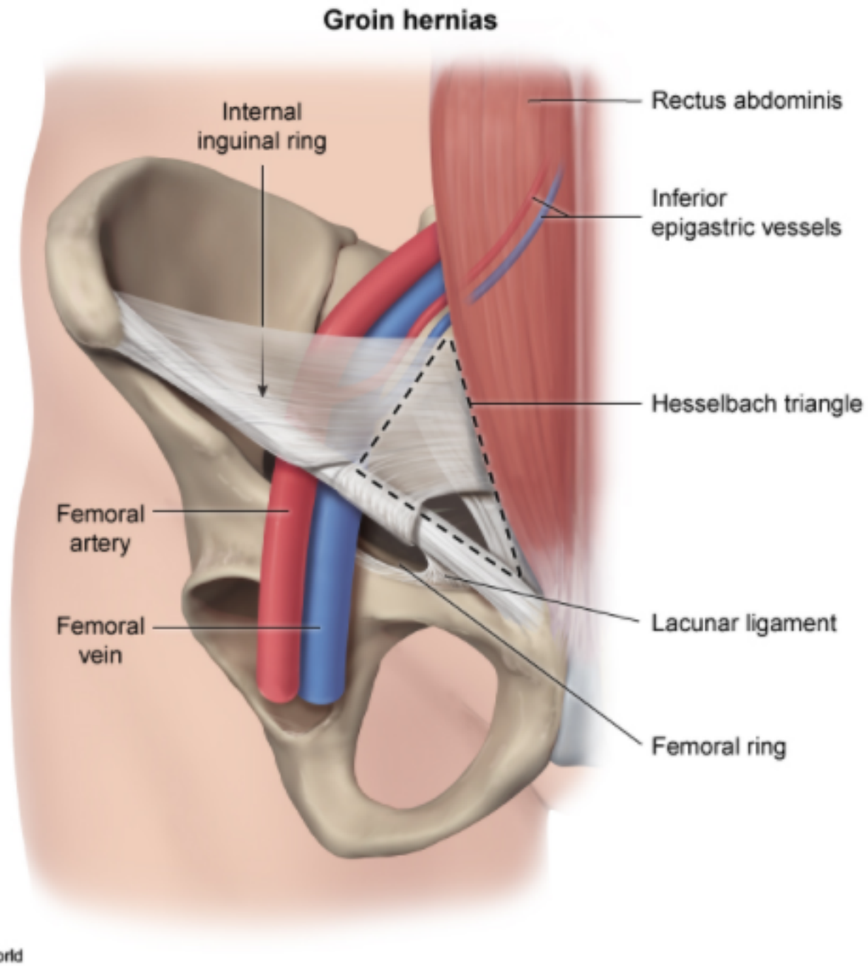

Zoom In | Zoom Out | Reset | Add To New Card | Existing Card

Direct and indirect inguinal hernias are both located **above the inguinal ligament**. They can be differentiated by their side of origination in

Exhibit Display

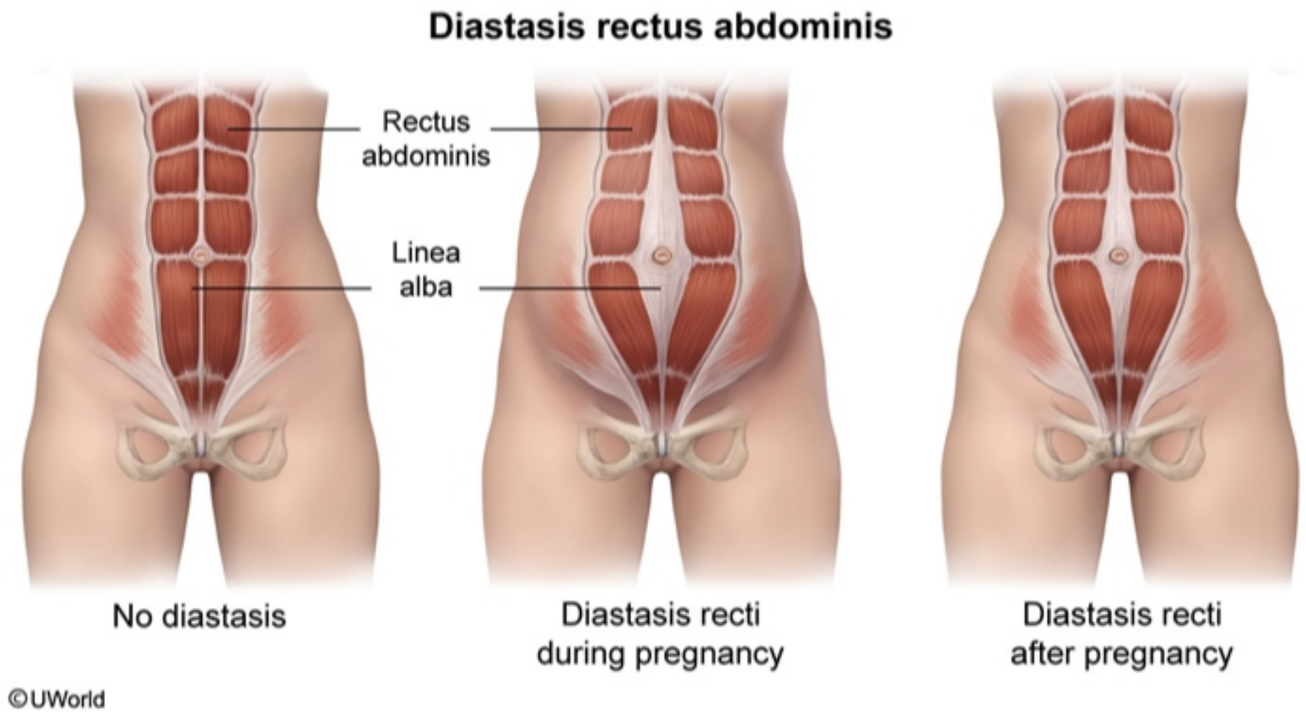

Zoom In | Zoom Out | Reset | Add To New Card | Existing Card

Direct and indirect inguinal hernias are both located **above the inguinal ligament**. They can be differentiated by their side of origination in

Exhibit Display

Femoral hernia

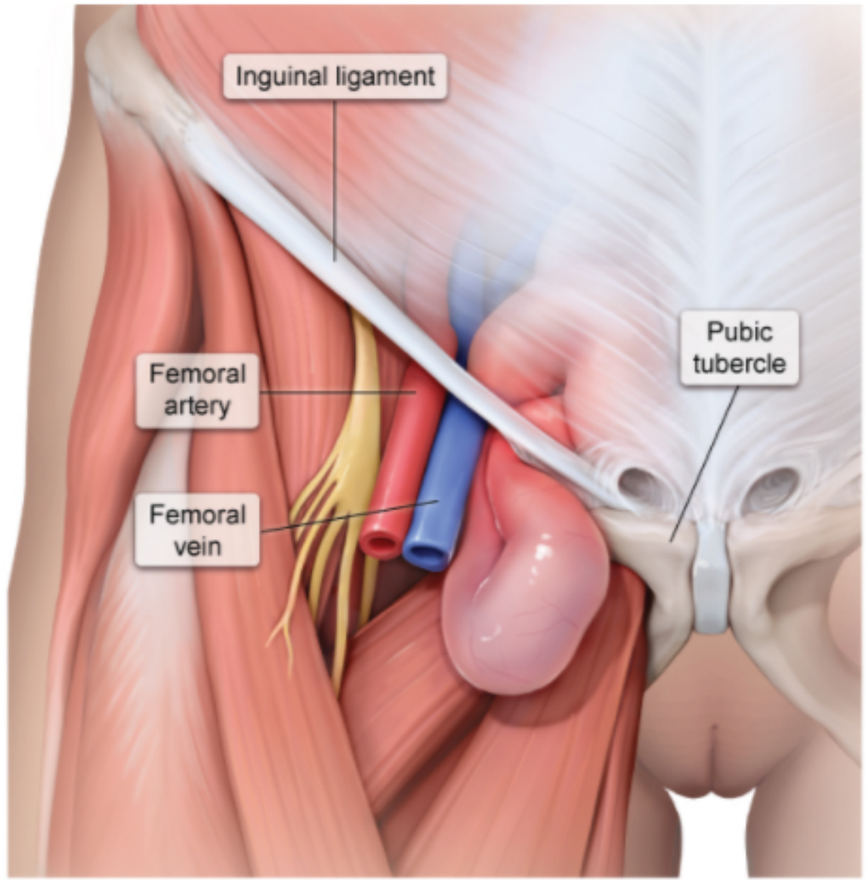

©UWorld

Zoom In | Zoom Out | Reset | Add To New Card | Existing Card

4
5
6
7
8
9
10
11
12
13
14
15
16
17
18
19
20
21
22
23
24
25
26
27
28
29
30
31
32
33
34

A 17-year-old girl is brought to the hospital due to abdominal pain, nausea, and vomiting. She began having periumbilical pain and nausea several hours ago and initially attributed her symptoms to some "bad food" she ate at a potluck lunch earlier in the day. However, her pain progressively worsened and became localized to the right lower quadrant. Temperature is 101 F (38.3 C), blood pressure is 124/78 mm Hg, pulse is 92/min, and respirations are 14/min. On examination, the patient has right lower quadrant tenderness with guarding. Laboratory evaluation shows leukocytosis. Surgical intervention is planned. During surgery, which of the following landmarks is most helpful in identifying the diseased organ?

A. Greater omentum
B. Haustra of the colon
C. Lesser omentum
D. Psoas major muscle
E. Teniae coli

Submit

4
5
6
7
8
9
10
11
12
13
14
15
16
17
18
19
20
21
22
23
24
25
26
27
28
29
30
31
32
33
34

A 17-year-old girl is brought to the hospital due to abdominal pain, nausea, and vomiting. She began having periumbilical pain and nausea several hours ago and initially attributed her symptoms to some "bad food" she ate at a potluck lunch earlier in the day. However, her pain progressively worsened and became localized to the right lower quadrant. Temperature is 101 F (38.3 C), blood pressure is 124/78 mm Hg, pulse is 92/min, and respirations are 14/min. On examination, the patient has right lower quadrant tenderness with guarding. Laboratory evaluation shows leukocytosis. Surgical intervention is planned. During surgery, which of the following landmarks is most helpful in identifying the diseased organ?

A. Greater omentum (2%)
B. Haustra of the colon (16%)
C. Lesser omentum (2%)
D. Psoas major muscle (30%)
✓ E. Teniae coli (48%)

Omitted
Correct answer
E

48%
Answered correctly

03 secs
Time Spent

05/17/2020
Last Updated

Explanation

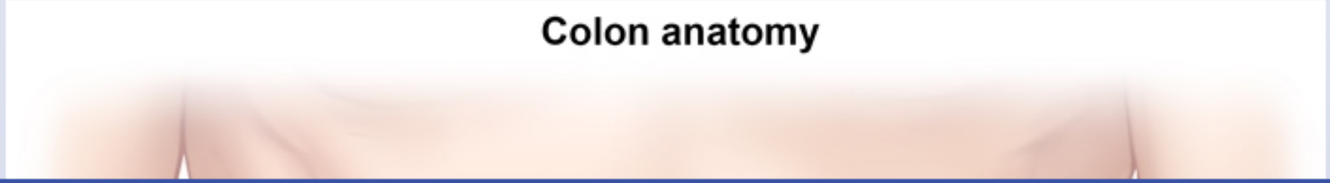

4
5
6
7
8
9
10
11
12
13
14
15
16
17
18
19
20
21
22
23
24
25
26
27
28
29
30
31
32
33
34

Colon anatomy

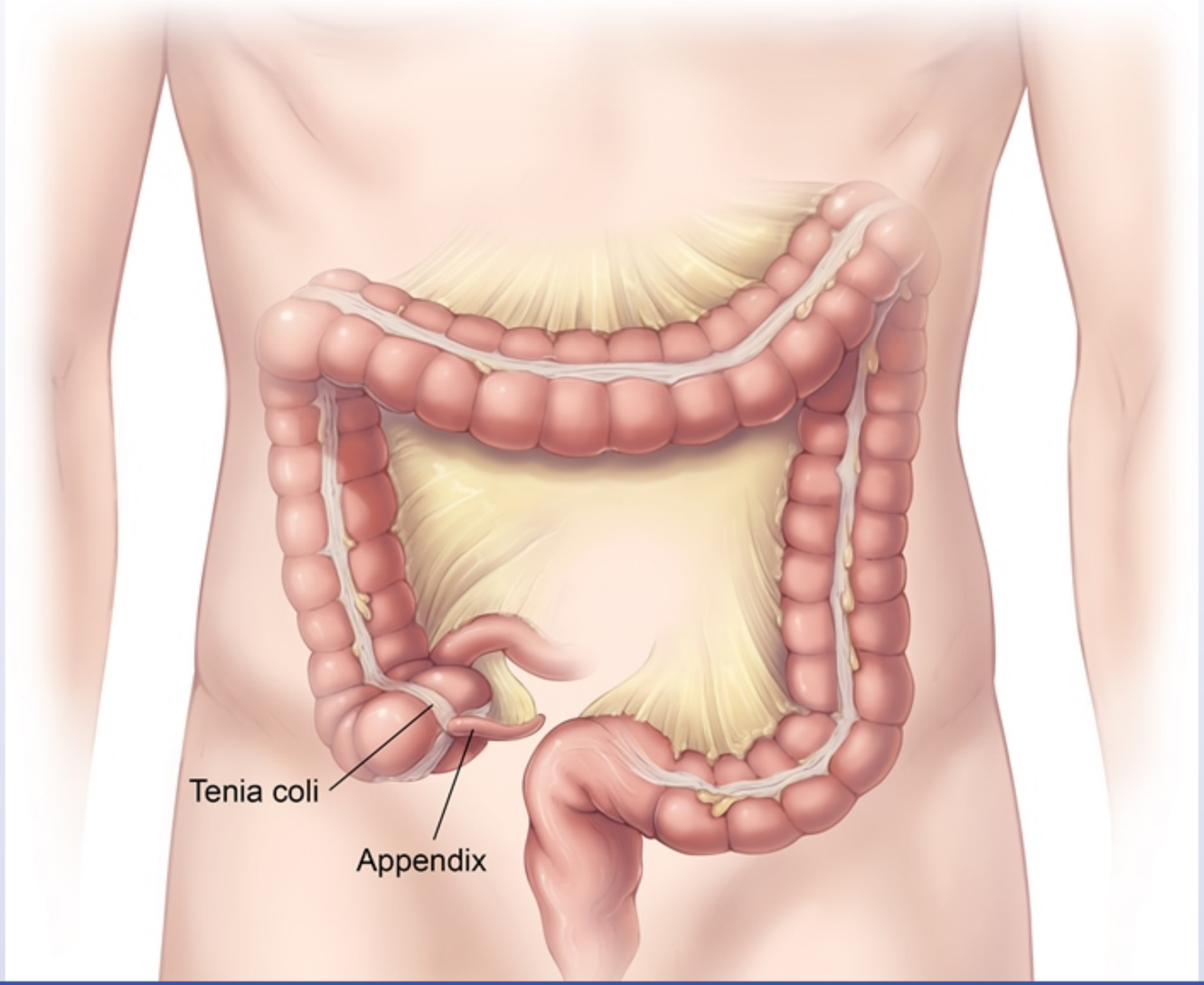

©UWorld

This patient most likely has **appendicitis**, which is usually treated by removing the appendix. During the procedure, the **teniae coli** can be used as a surgical landmark.

The teniae coli begin as a continuous layer of longitudinal muscle that surrounds the rectum just below the serosa. At the rectosigmoid junction, this layer condenses to form **3 distinct longitudinal bands** that travel on the outside of the entire colon before **converging** at the root of the vermiform **appendix**. The teniae coli have a similar function as the outer layer of the muscularis externa in other portions of the digestive tract. If the appendix cannot be identified by palpation during an appendectomy, it can be located by following the teniae coli to its origin at the cecal base.

(Choices A and C) The greater omentum extends from the greater curvature of the stomach in front of the small intestine. It then reflects on itself and ascends to encompass the transverse colon before reaching the posterior abdominal wall. The lesser omentum extends from the fissure of ligamentum venosum and porta hepatis to the lesser curvature of the stomach (hepatogastric ligament) and the start of the duodenum (hepatoduodenal ligament).

(Choice B) The teniae coli run the length of the colon and contract lengthwise to form haustra, colonic sacculations causing the colon's segmented appearance. Compared to the circumferential small intestinal folds, the distance between haustra is wider and they do not span the entire colonic circumference. These differences help distinguish the colon from the small intestine on abdominal x-ray.

(Choice D) Acute appendicitis due to a retrocecal appendix can irritate the iliopsoas group of hip flexors. Psoas sign is abdominal pain elicited by passive thigh extension, which causes friction against nearby inflamed tissues. However, psoas sign can be due to any retroperitoneal irritation and is not specific for appendicitis.

Educational objective:
The teniae coli are 3 separate smooth muscle ribbons that travel longitudinally on the outside of the colon and converge at the root of the vermiform appendix. If the appendix cannot be identified by palpation during an appendectomy, it can be located by following the teniae coli to their origin at the cecal base.

Anatomy	Gastrointestinal & Nutrition	Appendicitis
Subject	System	Topic

Copyright © UWorld. All rights reserved.

4
5
6
7
8
9
10
11
12
13
14
15
16
17
18
19
20
21
22
23
24
25
26
27
28
29
30
31
32
33
34

A 48-year-old man is evaluated for abdominal pain and diarrhea. The patient characterizes his stool as voluminous and foul smelling. He has no significant past medical history. The patient drinks 6 cans of beer daily. On examination, he has normal bowel sounds and mild epigastric tenderness. A 72-hour stool collection shows excessive excretion of fecal fat. A CT scan of the abdomen is shown in the image below. Involvement of which of the following structures is most likely causing this patient's symptoms?

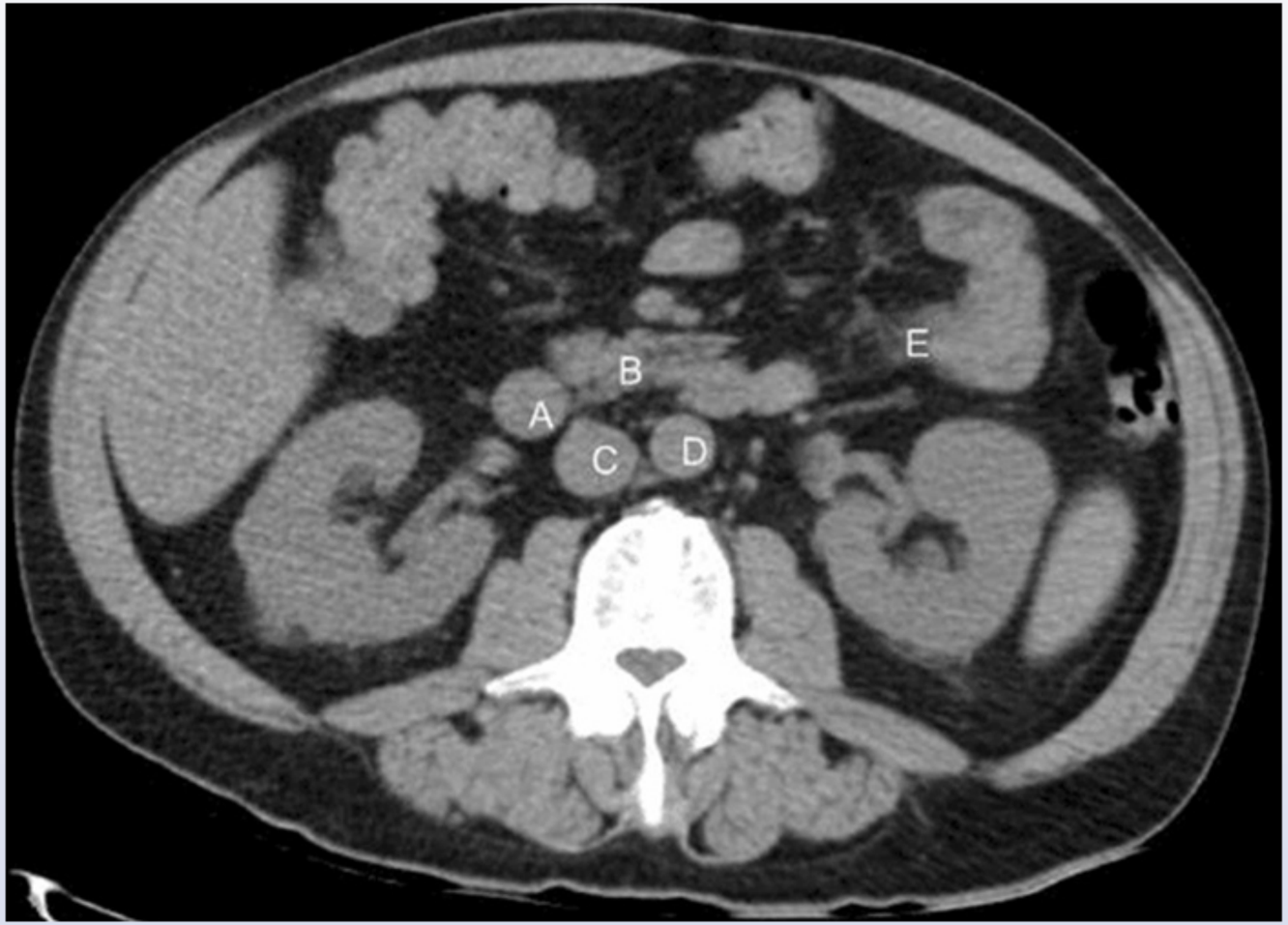

4
5
6
7
8
9
10
11
12
13
14
15
16
17
18
19
20
21
22
23
24
25
26
27
28
29
30
31
32
33
34

A. A

B. B

C. C

D. D

E. E

Submit

4
5
6
7
8
9
10
11
12
13
14
15
16
17
18
19
20
21
22
23
24
25
26
27
28
29
30
31
32
33
34

A. A (1%)

✓ B. B (91%)

C. C (0%)

D. D (0%)

E. E (5%)

Omitted
Correct answer

91%
Answered correctly

05 secs
Time Spent

06/30/2020
Last Updated

4
5
6
7
8
9
10
11
12
13
14
15
16
17
18
19
20
21
22
23
24
25
26
27
28
29
30
31
32
33
34

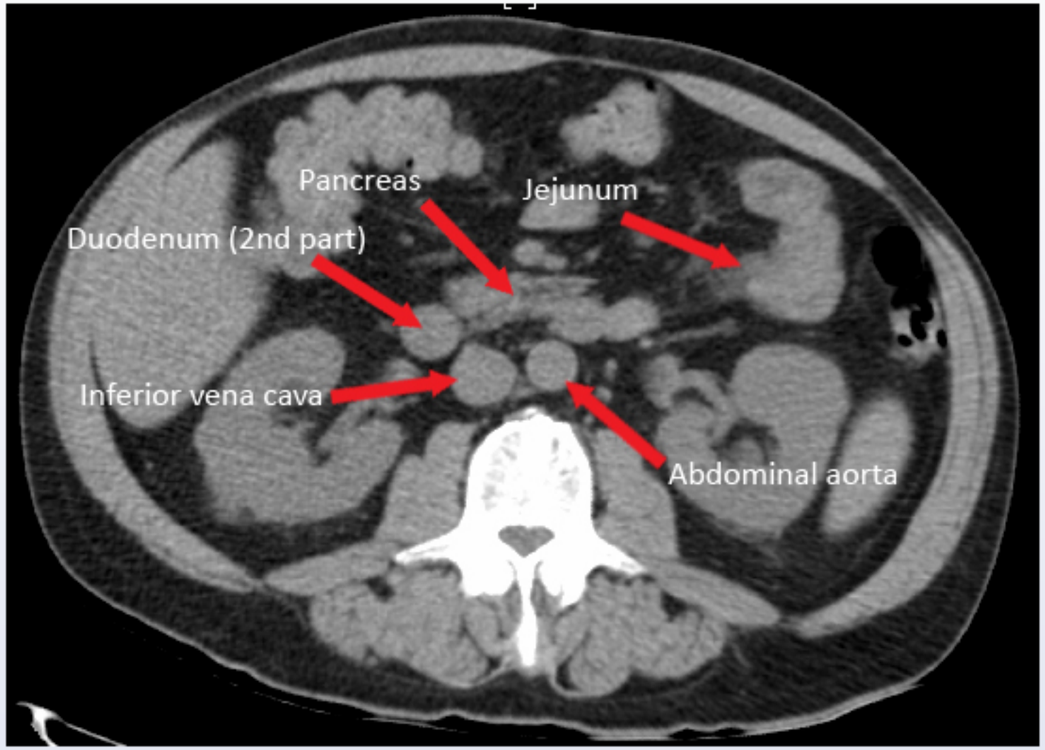

This patient with excessive alcohol use, **epigastric pain**, and **steatorrhea** likely has **chronic pancreatitis** with exocrine insufficiency. Atrophy and fibrosis of pancreatic acinar cells result in failed secretion of adequate amounts of digestive enzymes (eg, lipase). Consequently, patients may develop **fat malabsorption** with greasy, malodorous stools that are difficult to flush. A 72-hour stool collection can confirm excessive excretion of fecal fat.

The head, neck, and body of the pancreas are retroperitoneal, whereas the tail is peritoneal. The head of the pancreas lies in the curve of the duodenum and overlies the L2 vertebra, with a portion extending behind the superior mesenteric vessels (uncinate process). The neck connects the head to the body and lies anterior to the portal vein and superior mesenteric vessels. The pancreas body overlies the L1 and L2 vertebrae and makes contact posteriorly with the aorta, left adrenal gland, left kidney, and renal vessels. The tail of the pancreas courses within the splenorenal ligament alongside the splenic vessels.

4
5
6
7
8
9
10
11
12
13
14
15
16
17
18
19
20
21
22
23
24
25
26
27
28
29
30
31
32
33
34

This patient with excessive alcohol use, **epigastric pain**, and **steatorrhea** likely has **chronic pancreatitis** with exocrine insufficiency. Atrophy and fibrosis of pancreatic acinar cells result in failed secretion of adequate amounts of digestive enzymes (eg, lipase). Consequently, patients may develop **fat malabsorption** with greasy, malodorous stools that are difficult to flush. A 72-hour stool collection can confirm excessive excretion of fecal fat.

The head, neck, and body of the pancreas are retroperitoneal, whereas the tail is peritoneal. The head of the pancreas lies in the curve of the duodenum and overlies the L2 vertebra, with a portion extending behind the superior mesenteric vessels (uncinate process). The neck connects the head to the body and lies anterior to the portal vein and superior mesenteric vessels. The pancreas body overlies the L1 and L2 vertebrae and makes contact posteriorly with the aorta, left adrenal gland, left kidney, and renal vessels. The tail of the pancreas courses within the splenorenal ligament alongside the splenic vessels.

(Choice A) This structure is the second (descending) part of the duodenum.

(Choice C) This structure is the inferior vena cava, which lies on the right side of the vertebrae in a retroperitoneal position.

(Choice D) This structure is the abdominal aorta, which lies on the left side of the vertebrae in a retroperitoneal position.

(Choice E) At this level in the abdominal cavity, these loops of small bowel represent jejunum. If this CT slice were lower in the abdomen, these loops would more likely represent ileum.

Educational objective:
Chronic pancreatitis often presents with epigastric pain and pancreatic exocrine insufficiency resulting in fat malabsorption/steatorrhea. On abdominal CT scan, the pancreas can be identified by its head in close association with the second part of the duodenum; its body overlying the aorta, left kidney, and renal vessels; and its tail lying within the splenorenal ligament.

References

- Chronic pancreatitis.

Anatomy	Gastrointestinal & Nutrition	Chronic pancreatitis
Subject	System	Topic

Exhibit Display

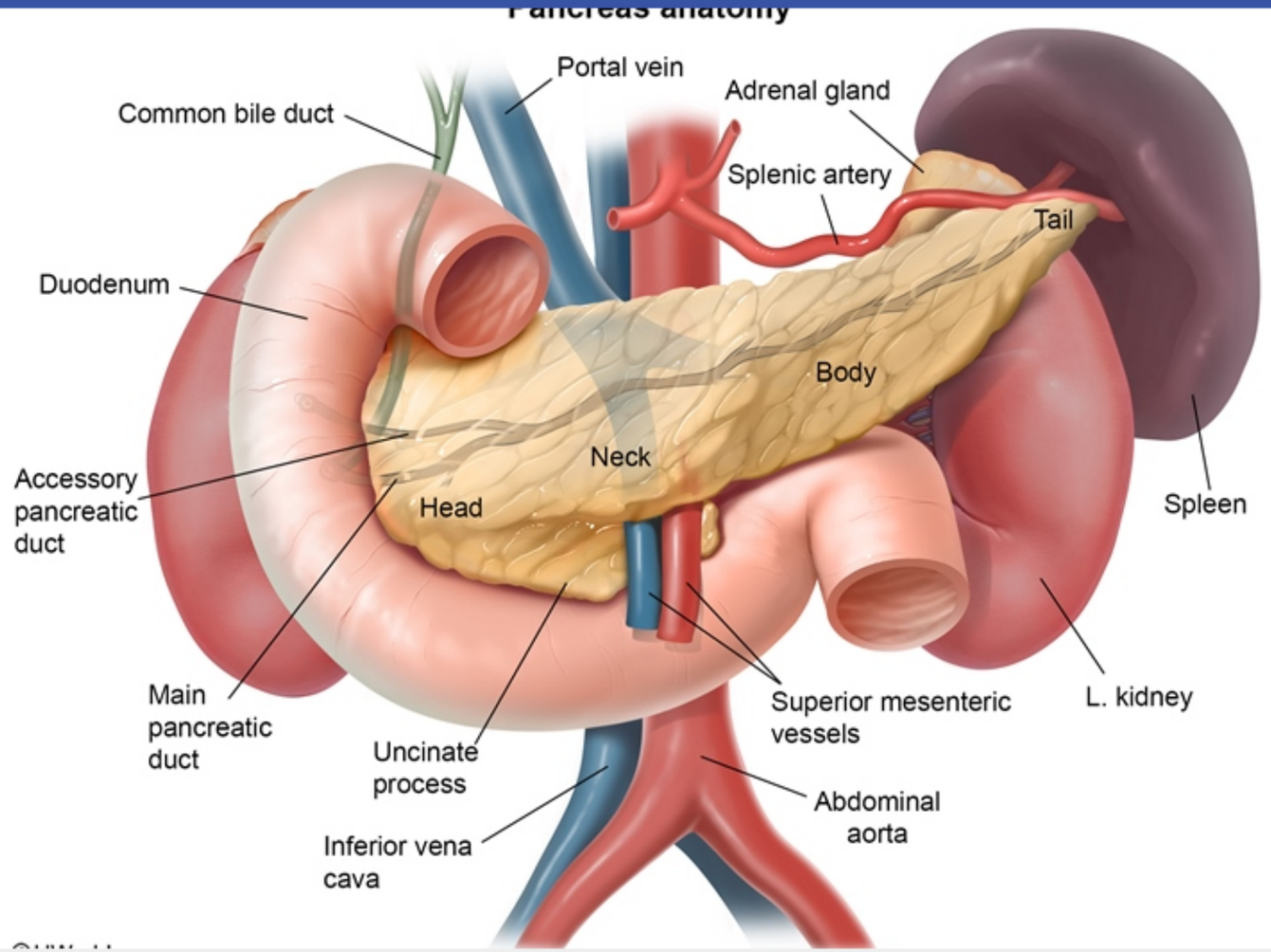

Zoom In | Zoom Out | Reset | Add To New Card | Existing Card

4
5
6
7
8
9
10
11
12
13
14
15
16
17
18
19
20
21
22
23
24
25
26
27
28
29
30
31
32
33
34

A 67-year-old man comes to the emergency department due to progressive fever and lethargy. The patient has also had severe right shoulder and abdominal pain, nausea, and vomiting for the past 2 days. He had an appendectomy during childhood and a pacemaker placed 10 years ago for symptomatic sinus bradycardia. He has no other medical problems and takes no medications. The patient does not use tobacco but drinks an occasional beer. Temperature is 38.4 C (101.1 F), blood pressure is 80/50 mm Hg, and pulse is 120/min and regular. Abdominal examination shows generalized tenderness with rebound tenderness. Right shoulder examination is normal. Upright chest x-ray is shown below.

Which of the following is the most likely cause of this patient's condition?

A. Acute cholecystitis
B. Acute pancreatitis
C. Nephrolithiasis
D. Perforated viscus
E. Small bowel obstruction

Submit

4
5
6
7
8
9
10
11
12
13
14
15
16
17
18
19
20
21
22
23
24
25
26
27
28
29
30
31
32
33
34

A 67-year-old man comes to the emergency department due to progressive fever and lethargy. The patient has also had severe right shoulder and abdominal pain, nausea, and vomiting for the past 2 days. He had an appendectomy during childhood and a pacemaker placed 10 years ago for symptomatic sinus bradycardia. He has no other medical problems and takes no medications. The patient does not use tobacco but drinks an occasional beer. Temperature is 38.4 C (101.1 F), blood pressure is 80/50 mm Hg, and pulse is 120/min and regular. Abdominal examination shows generalized tenderness with rebound tenderness. Right shoulder examination is normal. Upright chest x-ray is shown below.

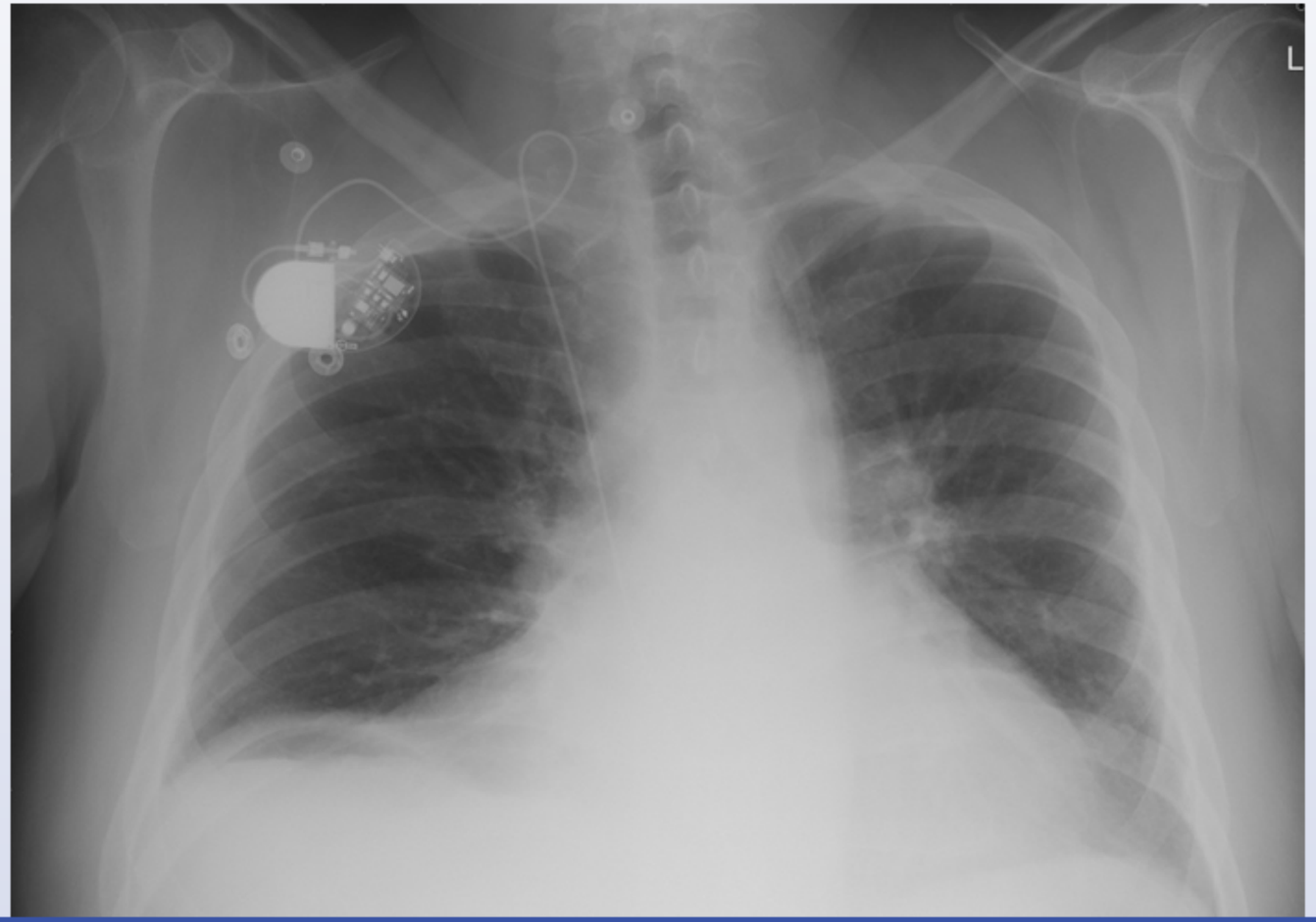

shows generalized tenderness with rebound tenderness. Right shoulder examination is normal. Upright chest x-ray is shown below.

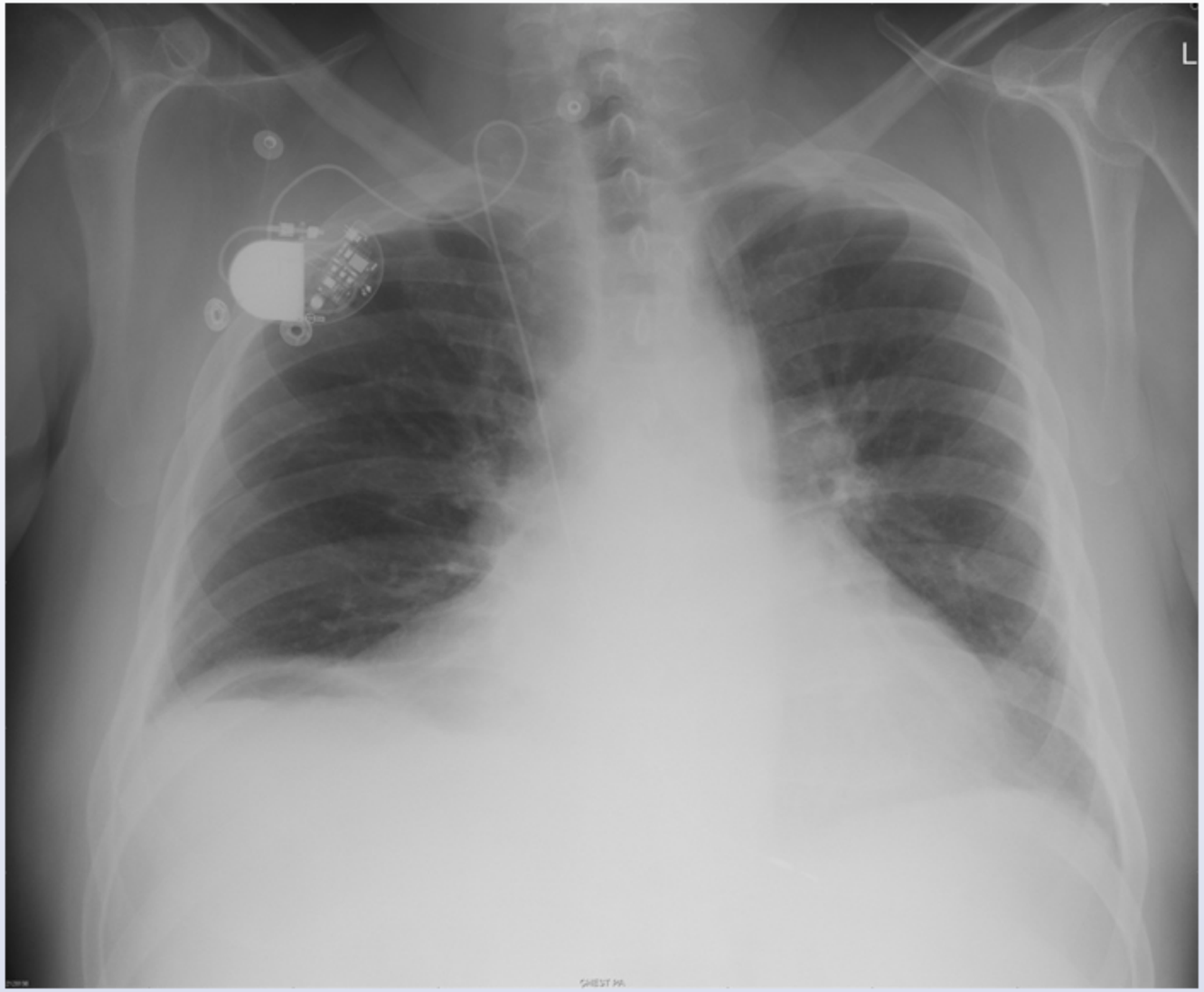

Which of the following is the most likely cause of this patient's condition?

4
5
6
7
8
9
10
11
12
13
14
15
16
17
18
19
20
21
22
23
24
25
26
27
28
29
30
31
32
33
34

4
5
6
7
8
9
10
11
12
13
14
15
16
17
18
19
20
21
22
23
24
25
26
27
28
29
30
31
32
33
34

Which of the following is the most likely cause of this patient's condition?

A. Acute cholecystitis

B. Acute pancreatitis

C. Nephrolithiasis

D. Perforated viscus

E. Small bowel obstruction

Submit

4
5
6
7
8
9
10
11
12
13
14
15
16
17
18
19
20
21
22
23
24
25
26
27
28
29
30
31
32
33
34

Which of the following is the most likely cause of this patient's condition?

A. Acute cholecystitis (24%)

B. Acute pancreatitis (13%)

C. Nephrolithiasis (0%)

✓ D. Perforated viscus (57%)

E. Small bowel obstruction (4%)

Omitted
Correct answer

57%
Answered correctly

07 secs
Time Spent

02/17/2020
Last Updated

4
5
6
7
8
9
10
11
12
13
14
15
16
17
18
19
20
21
22
23
24
25
26
27
28
29
30
31
32
33
34

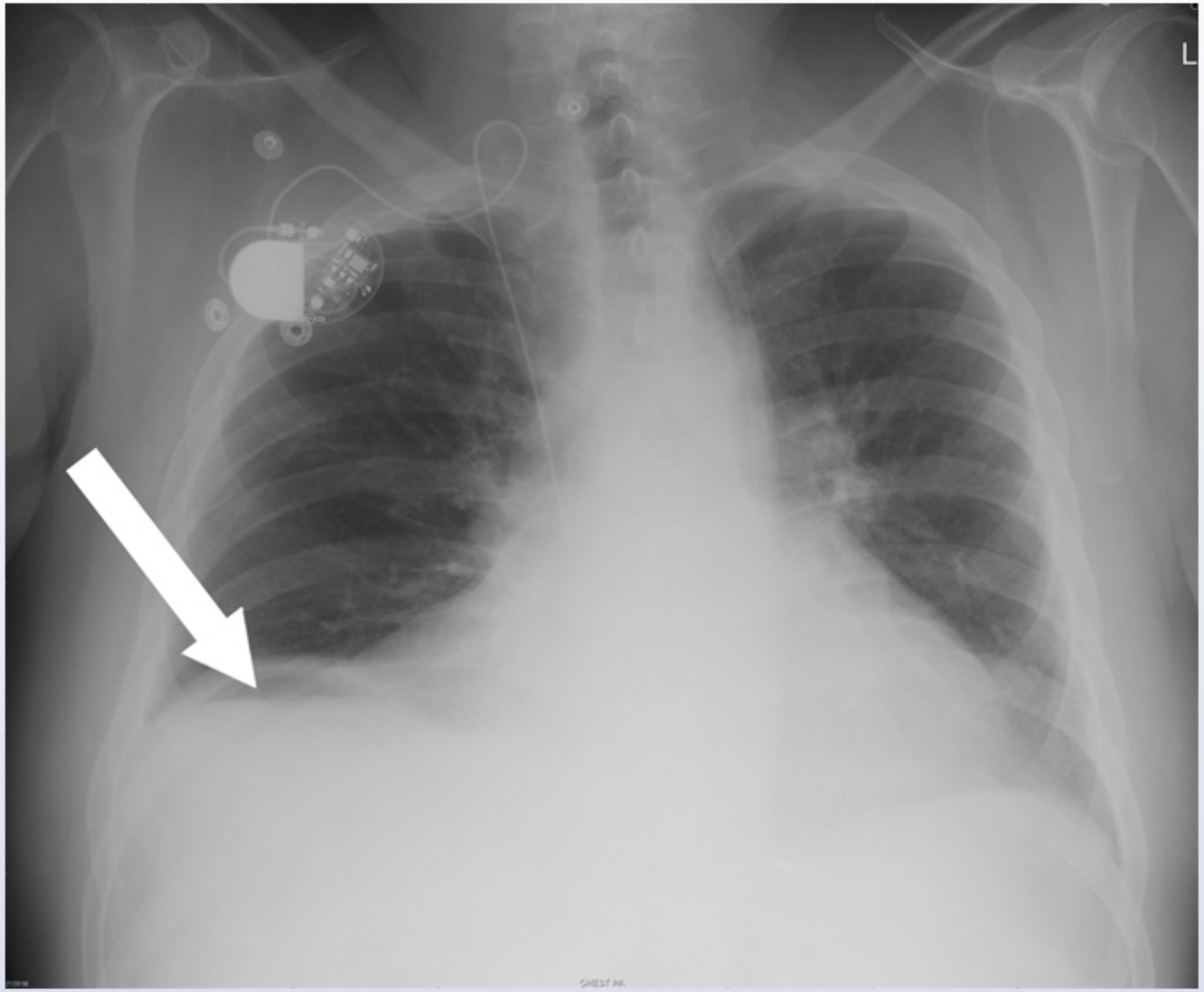

This patient's upright chest x-ray demonstrates **free air** under the diaphragm (**pneumoperitoneum**), likely due to **perforation** of a hollow

4
5
6
7
8
9
10
11
12
13
14
15
16
17
18
19
20
21
22
23
24
25
26
27
28
29
30
31
32
33
34

This patient's upright chest x-ray demonstrates **free air** under the diaphragm (**pneumoperitoneum**), likely due to **perforation** of a hollow abdominal viscus. The most common cause of pneumoperitoneum is a perforated duodenal ulcer, but perforation can occur anywhere along the gastrointestinal (or female reproductive) tract due to ulcers, tumors, trauma, or iatrogenic causes (eg, endoscopy, surgery).

Contamination of the sterile peritoneal cavity with bowel contents leads to chemical (acid or chyme-related) or bacterial **peritonitis**, which, if left untreated, can progress to sepsis and death. Diffuse irritation of the parietal peritoneum results in severe abdominal pain with **rigidity** and **rebound tenderness**. **Shoulder pain** is another frequent finding and reflects referred pain from diaphragmatic irritation. Referred pain is due to convergence of multiple nociceptors (visceral and somatic) onto a single secondary neuron within the spinal cord, which causes the brain to misinterpret visceral pain as airising from a body surface.

(Choice A) Other common causes of abdominal pain with associated diaphagmatic irritation and referred shoulder pain include acute cholecystitis/biliary colic and splenic lacerations. However, these would not be associated with intraabdominal free air.

(Choice B) Acute pancreatitis causes epigastric abdominal pain that may be referred to the back. X-ray findings are often normal, although a localized ileus near the inflammed pancreas (sentinel loop sign) may be seen.

(Choice C) Nephrolithiasis typically presents with colicky flank pain that is referred to the groin. Radiopaque stones (calcium, struvite, and cystine) may be visualized on plain radiography.

(Choice E) Small bowel obstruction causes poorly localized, constant abdominal pain, which can be referred to the epigastrium. Plain radiography demonstrates dilation of the small bowel with air fluid levels; free air is not seen in the absence of perforation.

Educational objective:
Pneumoperitoneum is air or gas in the peritoneal cavity; it can be seen as free air under the diaphragm in an upright chest x-ray. The most common cause is a perforated duodenal ulcer, but perforation can occur anywhere along the gastrointestinal (or female reproductive) tract. Subsequent peritonitis can lead to diffuse abdominal pain with rebound and guarding, sometimes with referred shoulder pain due to diaphragmatic irritation.

Anatomy Gastrointestinal & Nutrition Perforated viscus

4
5
6
7
8
9
10
11
12
13
14
15
16
17
18
19
20
21
22
23
24
25
26
27
28
29
30
31
32
33
34

Exhibit Display

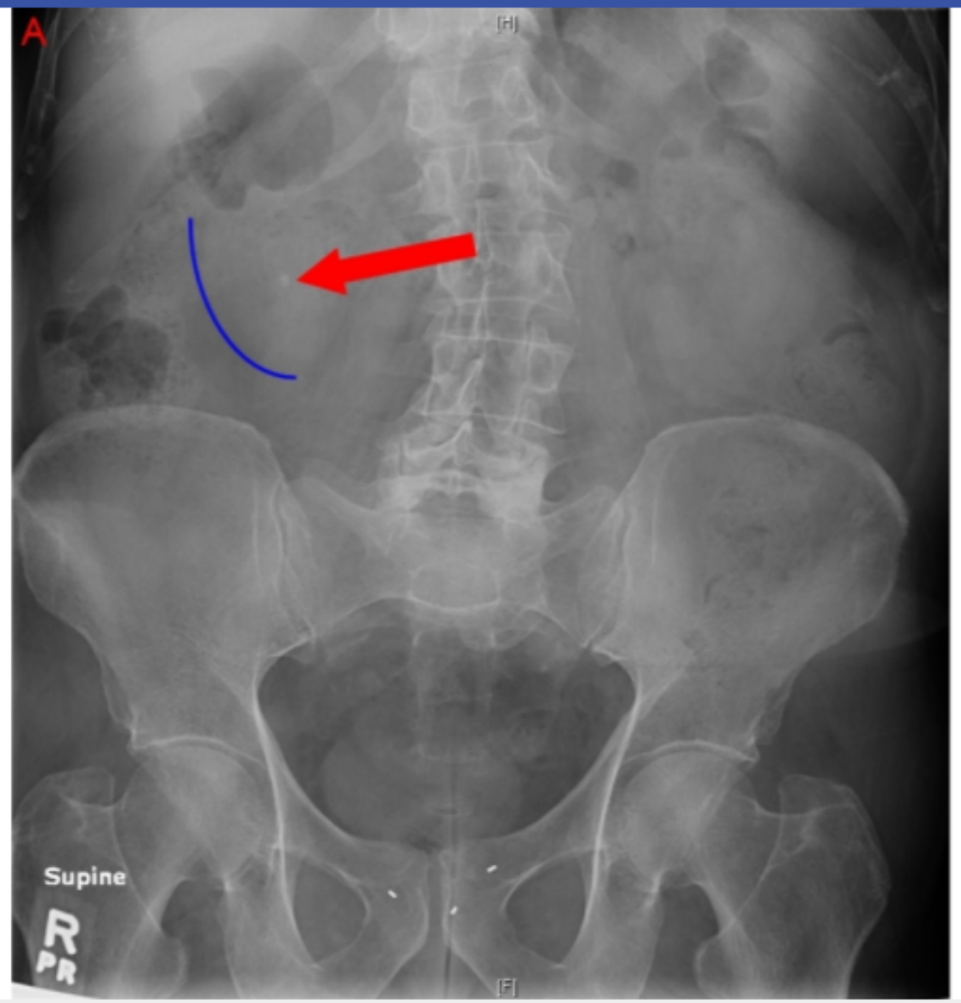

Zoom In | Zoom Out | Reset | Add To New Card | Existing Card

Anatomy | Gastrointestinal & Nutrition | Perforated viscus

4
5
6
7
8
9
10
11
12
13
14
15
16
17
18
19
20
21
22
23
24
25
26
27
28
29
30
31
32
33
34

Exhibit Display

Zoom In | Zoom Out | Reset | Add To New Card | Existing Card

Anatomy | Gastrointestinal & Nutrition | Perforated viscus

4
5
6
7
8
9
10
11
12
13
14
15
16
17
18
19
20
21
22
23
24
25
26
27
28
29
30
31
32
33
34

A 42-year-old man comes to the office with rectal bleeding. He used to have occasional streaks of blood on the tissue after wiping, but for the past several days he has seen blood dripping into the toilet at the end of defecation. The patient reports chronic constipation and has to strain while having a bowel movement but has no rectal or abdominal pain. He works as a truck driver, and his diet consists mainly of hamburgers and French fries. Abdominal examination is unremarkable. There is no mass or tenderness on digital rectal examination, but anoscopy shows bulging purplish-blue mucosal lesions above the dentate line. Rubber band ligation of the lesions is most likely to involve which of the following?

A. Deep external pudendal artery branches

B. External iliac vein tributaries

C. Inferior mesenteric vein tributaries

D. Internal pudendal vein tributaries

E. Left colic artery branches

F. Superior vesical artery branches

Submit

A 42-year-old man comes to the office with rectal bleeding. He used to have occasional streaks of blood on the tissue after wiping, but for the past several days he has seen blood dripping into the toilet at the end of defecation. The patient reports chronic constipation and has to strain while having a bowel movement but has no rectal or abdominal pain. He works as a truck driver, and his diet consists mainly of hamburgers and French fries. Abdominal examination is unremarkable. There is no mass or tenderness on digital rectal examination, but anoscopy shows bulging purplish-blue mucosal lesions above the dentate line. Rubber band ligation of the lesions is most likely to involve which of the following?

- A. Deep external pudendal artery branches (3%)
- B. External iliac vein tributaries (4%)
- ✓ C. Inferior mesenteric vein tributaries (62%)
- D. Internal pudendal vein tributaries (24%)
- E. Left colic artery branches (2%)
- F. Superior vesical artery branches (2%)

Omitted
Correct answer
C

62%
Answered correctly

04 secs
Time Spent

01/24/2020
Last Updated

Explanation

4
5
6
7
8
9
10
11
12
13
14
15
16
17
18
19
20
21
22
23
24
25
26
27
28
29
30
31
32
33
34

4
5
6
7
8
9
10
11
12
13
14
15
16
17
18
19
20
21
22
23
24
25
26
27
28
29
30
31
32
33
34

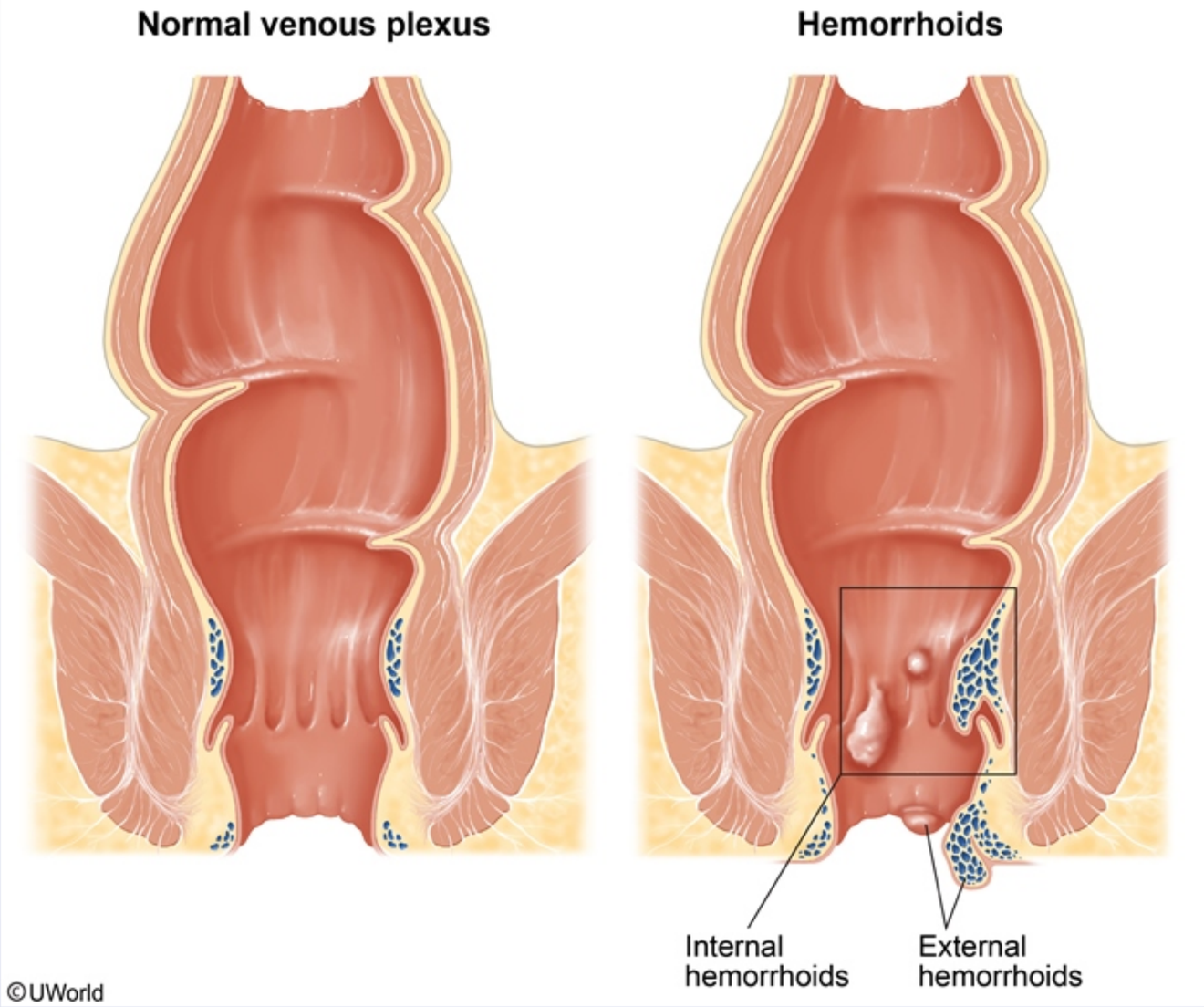

Hemorrhoids are classified based on their relation to the dentate line in the anal canal, with **internal hemorrhoids** originating **above the line** and external hemorrhoids below. They result from abnormal distension of the anal arteriovenous plexus, which normally forms the anal cushions

4
5
6
7
8
9
10
11
12
13
14
15
16
17
18
19
20
21
22
23
24
25
26
27
28
29
30
31
32
33
34

Hemorrhoids are classified based on their relation to the dentate line in the anal canal, with **internal hemorrhoids** originating **above the line** and external hemorrhoids below. They result from abnormal distension of the anal arteriovenous plexus, which normally forms the anal cushions (composed of venous sinusoids and connective tissue) that are important for maintaining fecal continence. Chronically increased venous pressure due to prolonged straining or breakdown of supporting tissue due to advancing age can cause the cushions to bulge into the anal canal, where they can become inflamed, thrombose, or prolapse.

Hemorrhoids can be treated with rubber band ligation, which cuts off the blood supply to the lesions and causes them to degenerate. The venous components of internal hemorrhoids drain into the **superior rectal vein**, which communicates with the **inferior mesenteric vein**. External hemorrhoids drain via the inferior rectal vein into the internal pudendal vein, which communicates with the internal iliac veins **(Choice D)**. Internal hemorrhoids have no somatic sensory innervation and cannot cause pain; however, external hemorrhoids are innervated by the same nerves that cover the perianal area and can be very sensitive to pain.

(Choice A) Branches of the deep external pudendal artery supply the scrotum (labia majora in females) and the perineum.

(Choice B) The external iliac vein receives drainage from the inferior epigastric and deep circumflex iliac veins, which serve the anterior abdominal wall and iliac crest, respectively.

(Choice E) The left colic artery branches off the inferior mesenteric artery to supply the transverse and descending colon.

(Choice F) The superior vesical artery and its branches supply portions of the urinary bladder and ductus deferens.

Educational objective:
Hemorrhoids result from abnormal distension of a portion of the anal arteriovenous plexus. The vascular components of internal hemorrhoids drain into the superior rectal vein, which subsequently drains into the inferior mesenteric vein. Band ligation of hemorrhoids cuts off their blood supply, causing them to degenerate.

References

- Hemorrhoids.
- Hemorrhoids.

Anatomy Gastrointestinal & Nutrition Hemorrhoids

Hemorrhoids are classified based on their relation to the dentate line in the anal canal, with **internal hemorrhoids** originating **above the line** and

Exhibit Display

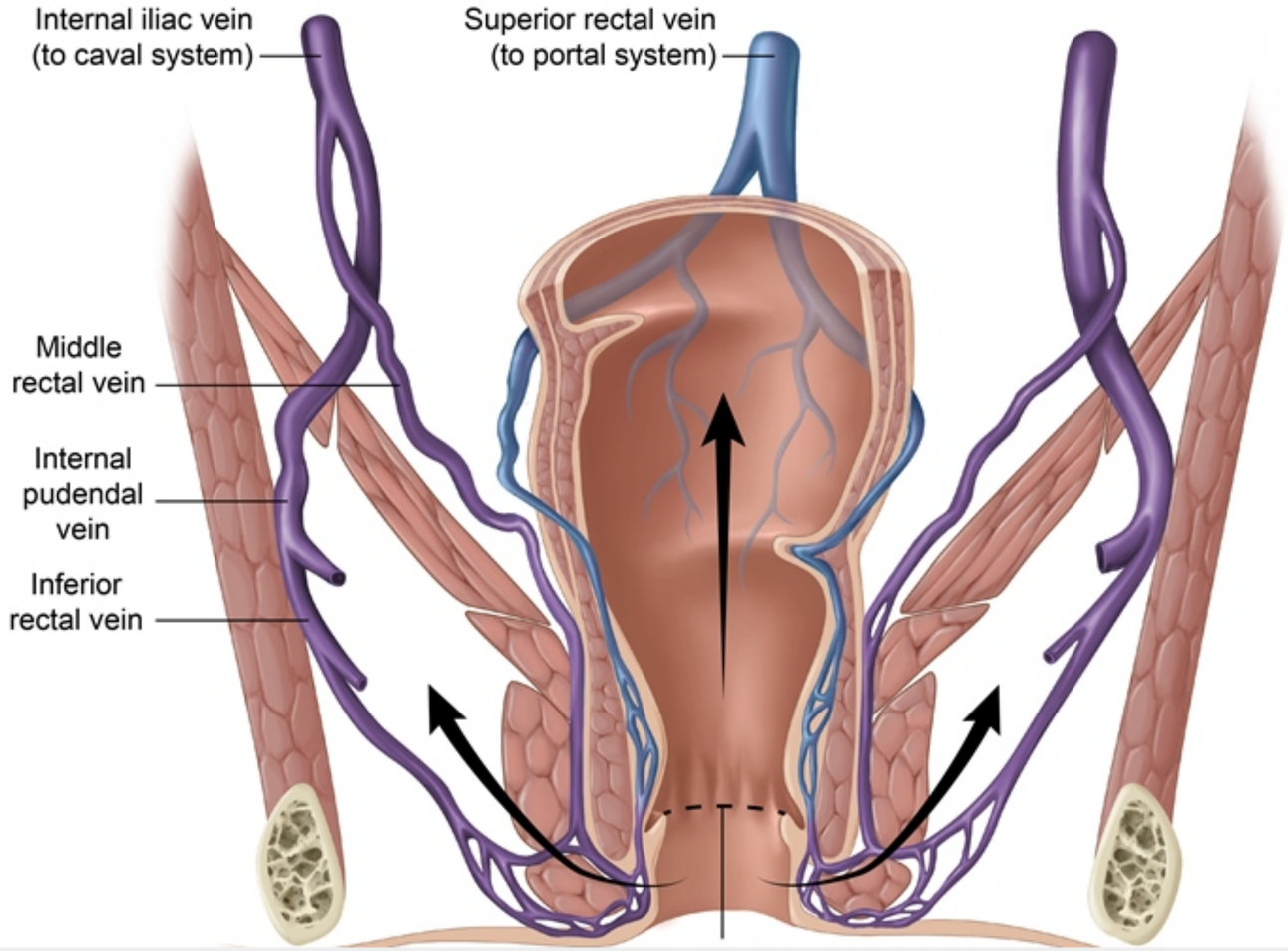

Zoom In | Zoom Out | Reset | Add To New Card | Existing Card

Anatomy | Gastrointestinal & Nutrition | Hemorrhoids